

УДК 617.57/.58-001.45:[616-089.22-024.62:615.463](045)

DOI: <http://dx.doi.org/10.15674/0030-59872023110-17>

Mechanical and clinical characteristics of the «rod – bone» connection in treatment of gunshot fractures with external rod devices from various manufacturers

Yu. V. Klapchuk ¹, O. K. Popsuishapka ², V. O. Lytvynshko ³

¹ Military and Clinical Center the Northern Region, Kharkiv, Ukraine

² Kharkiv Medical Academy of Postgraduate Education, Ukraine

³ Sytenko Institute of Spine and Joint Pathology National Academy of Medical Sciences of Ukraine, Kharkiv

Objective. To find out the state of the bone threading under the conditions of inserting the rods of different manufacturers and to establish the duration of a stable «rod – bone» connection in treatment of diaphyseal fractures of the bones of the limbs. *Methods.* An experiment was conducted using tibia bones of calves. Rods used in external fixators of Biomet (France), Stryker (USA), LLC H B Orto (Ukraine), ORTOPAK (Ukraine) manufacturers were selected. The shape of the bone threading and its contact with the surface of the rod were studied at 2–5X magnification. Devices from the specified manufacturers were used to fix bone fragments during the treatment of gunshot fractures in 91 patients. The stability of the rod in the bone was checked. *Results.* The experiment showed that in order to obtain the appropriate bone threading, it is necessary to first pass through both layers of the compact bone of the diaphysis using a drill with a diameter that corresponds to the inner diameter of the threaded part of the rod. Without this, bone coils in the first cortical layer are destroyed or bone fragments in the second are chipped off, reducing the strength of fixation. In the case of screwing the rods into the drilled channel in the second layer of the cortical bone, the quality of the «rod – bone» connection was worse in all cases. Under the conditions of installing the rods in the cancellous bone, a larger number of defective turns was formed in it compared to the compact one. The lowest frequency of rod instability in patients was found when using the ORTOPAK device (18 %); it was much more frequent (35–51 %) when using devices from other manufacturers. The incidence of the unstable state of the rods was almost 4 times greater in their location in the epimetaphysis than in the diaphysis. *Conclusions.* For the most effective connection of the rod with the bone, it is necessary to screw it into the prepared channel with a diameter that corresponds to the inner diameter of the threaded part of the rod. The quality and duration of the stable state of the rod in the bone depends on the technical characteristics of its threading, localization and state of fusion of the fragments.

Мета. З'ясувати стан кісткового різьблення за умов заведення стрижнів різних виробників і встановити тривалість стабільного з'єднання «стрижень – кістка» в разі лікування діафізарних переломів кісток кінцівок. *Методи.* Проведено експеримент з використанням великогомілкових кісток телят. Відібрані стрижні, які використовують у зовнішніх фіксаторах виробників: Біомет (Франція), Струкер (США), ТОВ Ейч Бі Орто (Україна), ОРТОПАК (Україна). Вивчали форму кісткового різьблення та його контакт із поверхнею стрижня за 2–5 разового збільшення. Пристрої від вказаних виробників застосовані для фіксації відламків кісток під час лікування вогнепальних переломів у 91 постраждалого. Перевіряли стан стабільності стрижня в кістці. *Результати.* Експеримент показав, що для отримання відповідного за формою кісткового різьблення необхідно попередньо проходити обидва шари компактною кістки діафіза свердлом із діаметром, який відповідає внутрішньому діаметру різьбової частини стрижня. Без цього руйнуються кісткові витки в першому кірковому шарі або відколюються фрагменти кістки в другому, що зменшує міцність фіксації. У разі загвинчування стрижнів у просвердлений канал у другому шарі кіркової кістки в усіх випадках якість з'єднання «стрижень – кістка» була гіршою. За умов установаження стрижнів у губчасту кістку в ній утворювалася більша кількість неповноцінних витків порівняно з компактною. Найменша частота нестабільності стрижнів у постраждалих виявлена в разі застосування апарата ОРТОПАК (18 %), значно частіша (35–51 %) — за пристроїв інших виробників. Частота нестабільного стану стрижнів була майже в 4 рази більшою за їхнього розташування в епіметафізі, ніж у діафізі. *Висновки.* Для максимально ефективного з'єднання стрижня з кісткою необхідно його загвинчувати в підготовлений канал діаметром, який відповідає внутрішньому діаметру різьбової частини стрижня. Якість і тривалість стабільного стану стрижня в кістці залежить від технічних характеристик його різьблення, локалізації та стану зрощення відламків. *Ключові слова.* Вогнепальні переломи, лікування, довгі кістки кінцівок, зовнішня фіксація, стрижень, стабільність фіксації.

Key words. Gunshot fractures, treatment, long bones of the limbs, external fixation, rod, stability of fixation

Introduction

Recently, the topic of fixation of fragments after gunshot fractures of the bones of the limbs with external fixation devices has become extremely relevant. According to published information, during the war with Russia on the territory of Ukraine, the number of persons with fractures of long bones, complicated by significant defects, increased among the victims (both military and civilians) due to the use of high-energy weapons (ballistic trauma) [1]. According to the UN, as of 15 August, the number of wounded civilians was 7,698, but the real figure is probably higher [2]. Installation of external fixation devices is a recognized first step [3], and according to other authors [4], an ideal treatment method for patients with gunshot fractures of the long bones of the limbs, as it provides the necessary stabilization and appropriate wound care and gives a possibility to obtain good long-term results.

As evidenced by our long-term practice of using devices for the treatment of fractures [5–8] and, especially, the experience gained during the last six months (from February to December), there are a number of topical issues. Among them, the first concern is the achievement of an effective and reliable «rod – bone» connection. A feature of the structure formed in the case of fixation of bone fragments with an external device is a large number of connecting nodes. If the junctions of the device elements are mechanically controlled, then the «rod – bone» connection is the most vulnerable, since it depends on the individual mechanical properties of bone tissue, which are significantly different from metal. In addition, the condition of the bone may change over time due to its reconstruction after surgical intervention. If backlash occurs in this connection, the structure goes from a stable-elastic to a plastic-unstable state with corresponding negative consequences.

The stability and reliability of this connection depends on the form of threading of the rods and the method of screwing them into the bone. But this issue is not given due attention. In most of the available instructions of manufacturers of external structures for osteosynthesis, there are no recommendations on the rules of screwing the rods, in the literature there are only separate reports concerning scientific studies of the mechanics of connecting the rods or the screw to the bone [9].

Purpose: to assess the state of bone threading following the insertion of rods produced by different manufacturers and to determine the duration of a stable «rod – bone» connection in treatment of diaphyseal fractures of the limbs.

Material and methods

The materials of the study were reviewed and approved by the Bioethics Committee at the State Institution Professor M. I. Sytenko Institute of Spine and Joint Pathology of the National Academy of Medical Sciences of Ukraine (Protocol No. 229 of 20.02.2023).

In order to assess the state of the bone threading after inserting the rod, an experiment was conducted using calf tibia bones. The samples of rods used in external fixators of manufacturers were selected as follows: Biomet (France), Stryker (USA), HB Ortho (Ukraine), ORTHOPAK (Ukraine). The devices of the specified manufacturers were used to fix bone fragments after diaphyseal fractures in 91 patients who received treatment at the State Institution Professor M. I. Sytenko Institute of Spine and Joint Pathology of the National Academy of Medical Sciences of Ukraine (13 subjects), the Military Medical Clinical Center of the Northern Region of the Ministry of Defense of Ukraine (35), the Communal Non-Profit Enterprise M. I. Kononenko Chuhuyiv Central Hospital (42).

Table 1

Characteristics of the threaded part of rods produced by different manufacturers

Characteristics	Manufacturer			
	Biomet	Stryker	HB Ortho (AO)	ORTHOPAK
Outer diameter (D) of the threaded part, mm	4.5	5	5	6–4.7 (cone)
Internal diameter (d) of the threaded part, mm	3.5	4	4	4.5–3.2 (cone)
Height (h) of thread, mm	0.65	0.50	0.50	0.75
Thread (l) pitch, mm	1.80	1.25	1.80	2.00
Angle (α) of the thread profile, degree	35	30	45	20
Shape of the cutting edge at the end of the rod	three-sided	15 mm long drill	three-sided, conical with a slot	two slots 12 mm long
Material	stainless steel			vanadium-titanium alloy VT 16-22

The main characteristics of the threaded part of the rods selected for the experiment, obtained by measurement, are given in the Table. 1.

Methodology of the experiment. These rod samples were screwed into the diaphyseal and epiphyseal parts of the calf tibia under the following conditions:

– by drilling the bone directly with a rod using a drill with a low frequency of rotation (for rods manufactured by Biomet, Stryker, HB Ortho (AO);

– by pre-drilling the bone with a drill with the diameter corresponding to the inner diameter of the threaded part of the rod (3.5 mm and 4 mm, respectively), then the rod was screwed into the formed hole manually using a T-key.

During the procedure of screwing the rod, attention was paid to the process of its threaded part entering the bone channel, resistance to rotation, uniformity of immersion, etc. For this, the process was filmed on a camera for repeated visual analysis.

Later, the bone was transversely sawed so that the saw passed along the edge of the hole in which the rod was located. Each of the obtained bone fragments with a hole was polished using sandpaper (100, 200) so that the polished surface passed through the middle of the hole. This was performed to obtain a «clean» section of the bone threading profile.

The obtained samples were photographed with a digital camera and the shape of the bone threading and its contact with the surface of the rod were studied at 2–5 times magnification. In the photographs, the quality of the contact of the rod with the bone was evaluated by the number of bone turns (in percent) with the profile that was in full contact with the metal. If the bone profile of the coil did not match the shape of the intercoil profile of the rod or was absent, it was considered inferior.

That is, if in one bone channel we saw 8 profiles, of which 6 were in full contact with the metal and 2 profiles of a broken shape, then the percentage of turns with full contact was 75.

In total, 8 samples of the bone threading profile were obtained, taking into account the fact that

the rod of each manufacturer was screwed into the bone without and with its prior drilling.

Criteria for clinical and radiological assessment of the stability of the rod-bone connection. First, it is necessary to define the term «stable (unstable) rod-bone connection». In our opinion, this is a condition when between the surfaces of the bone and the threaded part of the rod there are no angular, axial and rotational movements of the rod relative to the threaded surface of the bone in the event of applying forces in the corresponding three planes. In practice, we perform this by manually trying to move it by twisting, shearing and pulling. We systematically checked this sample at the following stages of treatment: after inserting the rods during surgery, disconnecting the external support, to check the state of fusion of the fragments (their mobility or immobility) after removing the device.

Results and their discussion

The characteristics of threading in bone canals after screwing in rods from different manufacturers are presented in Table 2.

The study showed that the quality of the bone threading, first of all, depended on the conditions of its screwing. As we can see from the Table, there were significantly more complete turns under the conditions of pre-drilling a channel in the bone with a drill of the appropriate diameter. At the same time, the immersion process of each rod during the experiment was shown to be accompanied by certain features, listed below:

1. Biomet rod (France). It has a three-sided sharpening at the end, thread pitch 1.8 mm, thread height 0.65 mm.

When inserting it into the whole bone with the help of a drill (without prior drilling), the passage of the first cortical layer lasted 85 s, after which the threaded part of the rod sank very quickly into the channel until it came into contact with the second cortical layer, then the speed of rotation of the drill dropped sharply, which indicated the emergence

Table 2

Turns with full metal contact (%)

Diaphysis layer	Biomet		Stryker		HB Ortho (AO)		ORTHOPAK	
	without drilling	drilling	without drilling	drilling	without drilling	drilling	without drilling	drilling
First cortical	6/2 30 %	8/6 75 %	14/10 71 %	15/15 100 %	13/2 15 %	13/11 85 %	—	10/10 7/7
Second cortical	6/2 30 %	6/5 83 %	12/3 25 %	13/7 54 %	8/2 25 %	8/6 75 %	—	0/0
Both cortical	12/4 30 %	14/11 79 %	26/13 50 %	38/31 82 %	21/4 19 %	21/12 57 %	—	—

of resistance. The exit of the end of the rod from the second cortical layer was accompanied by a chipping of the bone plate. Evaluation of the channel on the section showed that in the first cortical layer most of the turns were destroyed, and in the second there was a chipping of the outer part of the bone (Fig. 1, a).

In the case of inserting this same rod into a pre-drilled channel with a diameter of 3.5 mm, the immersion of the rod with the help of a manual T-key occurred evenly, with little effort during rotation, and on the sample we observed significantly more complete bony turns that were in full contact with metal than in the previous case (Fig. 1, b). So, insertion of the Biomet rod without prior drilling is possible, but at the same time perforation of the first layer occurs due to drilling with a three-sided sharpening of the rod with the simultaneous formation of a bone threading, after which the rod is fed along it, and upon contact with the second layer of the bone, immersion in it is impossible in this mode movement, because drilling of the bone with a trihedral sharpening requires much more revolutions than the number of bone turns in the first layer. Violent rotations result in either the destruction of the bone coils in the first cortical layer or, if there are many coils and they offer effective resistance, there is a wedge-shaped fracture of the bone in the second layer (Fig. 1, a). We can also observe both negative phenomena.

2. The rod manufactured by Stryker Company has a cutting edge in the form of a drill at the end, the thread pitch is 1.25 mm, and the height is 0.5 mm. When drilling a compact bone with the help of a rotary tool, the first cortical layer was quite effectively penetrated due to the sharp cutting edge. But when the rod entered the second cortical layer of the bone, there was a strong resistance to its rotation, because of which it was not even possible to pass it through the entire second layer. Evaluation of the cross-section of the bone showed that 10 out of 14 (71 %) bone

threading profiles with full contact with the metal were formed in the first cortical layer (Fig. 2, a). A bone threading defect was observed in the first two turns, which was associated with angular deviations of the rod during its rotation with the help of a swivel, provided in the manufacturer's kit. We observed this while watching the video of the procedure. In the second layer of the bone, there were few complete bone turns — 3 out of 12 (25 %). This can be explained by the fact that the side slits were filled with tightly compressed bone chips, which prevented the metal coils from cutting into the bone and created great resistance to rotation.

During the installation of the Stryker rod into a pre-drilled channel with a diameter of 4 mm (corresponding to the inner diameter of the threaded part), an effective formation of a bone thread was found in the first cortical layer of the bone with full contact of all turns (100%), and 54% in the second one (Fig. 2, b).

3. The rod produced by HB Ortho (Ukraine) has a three-sided sharpening at the end or a cone-shaped one with one slot, the thread pitch is 1.8 mm, the height is 0.5 mm. According to its characteristics, it is similar to the Biomet rod, and the results of the experiment with it, respectively, were similar.

In particular, the number of complete profiles of turns under the conditions of screwing without prior drilling in the first cortical layer of the bone was equal to 15 %, in the second — 25 %; in the case of a pre-drilled channel with a diameter of 4 mm — 85 and 75 %, respectively. Due to the similar pattern of thread formation with the Biomet rod, we do not provide an illustration.

4. The ORTHOPAK rod, unlike the previous ones, has a threaded part in the form of a cone with a small angle, two slots at the end with a cutting edge, a thread pitch of 2 mm, a coil height of 0.75 mm. Made of titanium alloy, according to the manufacturer's instructions, the rod must be screwed in manually

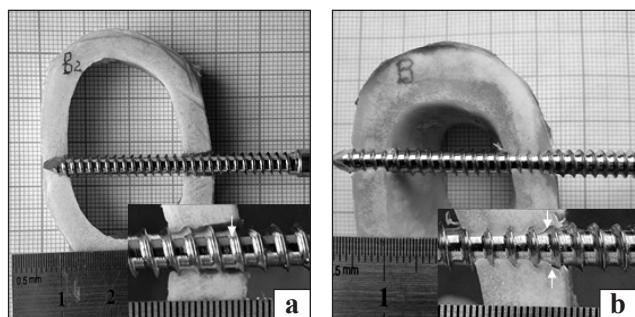


Fig. 1. The appearance of the thread in the bone canal after inserting the Biomet rod: a) with a drill at low turns without pre-drilling the canal, b) using an end wrench after pre-drilling the canal with a drill with a diameter of 3.5 mm




Fig. 2. The appearance of the thread in the bone canal after screwing the Stryker rod with a manual rotary screw: a) without pre-drilling the channel, b) after pre-drilling the channel with a drill with a diameter of 4 mm

with a T-key after pre-drilling both layers of compact bone with a 3.5 mm drill.

The screwing process began without much resistance to rotation, unlike all the other rods discussed above. But as the rod plunged into the bone, the resistance to rotation increased, especially when entering the second layer of compact bone. On the cross-section of the bone, in all cases it was found that all the turns of bone threading in the first cortical layer of the bone were in full contact with the metal surface, in the second, the formation of bone threading was limited or absent due to the absence of turns on the end part of the rod (Fig. 3).

Thus, the experiment showed that in order to obtain the appropriate bone thread, it is necessary to pre-drill both layers of compact bone with a drill with a diameter corresponding to the inner diameter of the threaded part of the rod. It is possible to drive the rod into the bone without prior drilling. But at the same time, there is either destruction of the bone coils in the first cortical layer at the stage of drilling the second layer or «breaking» of the bone in the second, which reduces the working area of the bone surface that is in contact with the metal surface.

The experiment showed that in the case of screwing the selected rods into the drilled channel in the second layer of the cortical bone, the quality of the bone carving was worse in all cases. This is due to the dense filling of the groove with bone chips, which blocks the cutting edge, or to a decrease in the rotation speed of the rod. In this regard, it should be noted that the main load is taken by the threaded connection of the rod in the first compact layer. In one of our studies [10], it was proved by means of mathematical modeling that under the action of the load along the axis of the titanium rod, which is located in the bone, the maximum stresses fall on the first 7–8 turns and decrease uniformly in the direction of penetration. If we compare the case when this same rod is screwed into titanium, the stress is concentrated only on 1–2 turns.

The connection of the rod to the second compact layer has a larger value of the second fulcrum to resist its angular movement.

The study showed that screwing of the rods into cancellous bone was accompanied by bone carving formed with a greater number of inferior turns with limited contact with the metal surface, in contrast to compact bone (Fig. 4).

This phenomenon can be explained by the fact that the cutting edge at the end of the rod cannot provide the effect of cutting fragile trabeculae, or rather, it breaks them. Thus, due to the uniform structure of compact bone, a much smoother contact surface can be obtained during cutting.

In practice, it is necessary to understand how the connection of a carved rod and a smooth one will differ. Firstly, it is an effective counteraction to the axial movement of the rod, which can occur by eliminating and countering the occurrence of angular deformation of the segment. Secondly, the presence of a thread significantly increases the contact area of the rod with the bone compared to a smooth rod of the same diameter, which reduces the specific pressure on the bone, which is a vulnerable component of the connection. Mathematical calculations show that the presence of a thread increases the area

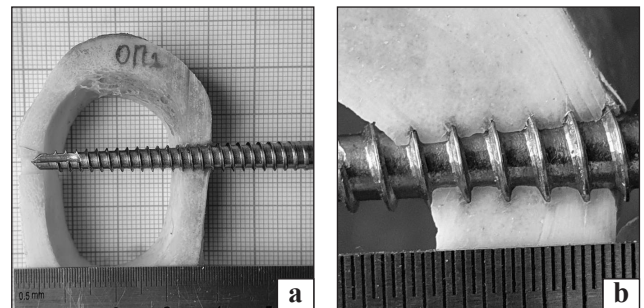


Fig. 3. The appearance of the thread in the bone channel after screwing the ORTHOPAK rod using an end wrench: a) after pre-drilling with a drill with a diameter of 3.5 mm; b) appearance of bone thread in the first layer of compact bone, 5-fold magnification

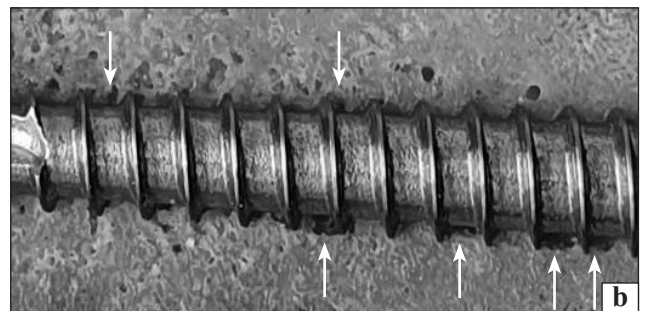
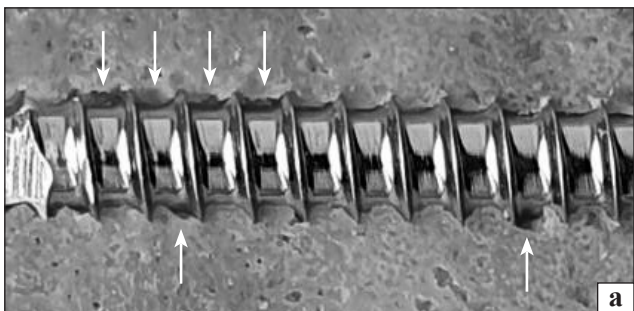


Fig. 4 The appearance of the thread in the cancellous bone after screwing the Biomet (a) and ORTHOPAK (b) rods (arrows show the turns of a broken shape)

of the contact surface by approximately two times. And the relevant issue in this case is to achieve the maximum contact area between the surface of the metal thread and the bone during the insertion of the rod. Reducing contact surfaces increases their stress level and increases the likelihood of bone destruction. There is also an assumption that the quality of bone turns is more important than their quantity.

In order to find out the state of connection of the rods with the bone during the treatment of fractures, we conducted a clinical study.

The state of the rod-to-bone connection was evaluated in 91 patients with the external abutment removed. This happened at the time of removing the external fixation device, or conducting a clinical test for the presence/absence of fragment mobility at a certain stage of treatment. The research was conducted within 3–6 months of fixation of fragments with an external fixation device. Among them, there were 24 patients with femur, 57 with tibia, 6 with humerus and 4 with forearm fractures. The above types of devices were applied to the patients. In total, the quality of the «rod – bone» connection was assessed in 405 cases, taking into account that 4–6 rods were installed in each patient. The first and main technique that revealed the quality of the connection of the rod to the bone was to check for its rotational movements. To do this, taking the end of the rod with fingers (or the rod retainer that remained on it), we tried to turn it first clockwise, and then counter-clockwise. If the rod rotated without resistance, the state of its connection with the bone was considered unstable, and the presence of its angular and axial movements relative to the bone was further checked. At the same time, attention was paid to the soft tissues around the rod, because in its unstable state, inflammation with the presence of serous or purulent discharge and granulations was observed in them. Instability was also evidenced by bone resorption around the rod on radiographs. The absence of rotational and other movements of the rod indicated the presence of a tight contact between it and the bone in the threaded area.

The frequency of the «unstable» («stable») state of the rod-bone connection was analyzed depending on:

- rod type (Table 3);
- localization of the wound rod: diaphysis, epimetaphysis (Table 4);
- the state of the regenerate that connected the fragments — solid bone (bone fusion), fibrous connection (non-union) (Table 5).

Statistical analysis using the χ^2 method showed that the lowest frequency of unstable state was in the case of using the ORTHOPAK rod (18 %), and much higher

when using the rods of other manufacturers (35–51 %). In our opinion, this may be due to two circumstances. The first is the poor performance of the procedure for winding the rods (without pre-drilling the channel, using a drill with the wrong diameter).

In addition, Biomet, Stryker, HB Ortho external fixators were installed in various medical institutions of Ukraine and by different surgeons, in contrast to ORTHOPAK fixators, which were used by surgeons who developed the device and, accordingly, carefully followed the method of inserting the rods. It cannot be ruled out that the design and material of the rod (titanium alloy, conical threaded part, larger thread pitch) plays an essential part as well.

The frequency of the unstable state of the rods was almost 4 times greater in their location in the epimetaphyseal zone than in the diaphyseal zone. This fact may be associated with a lower density of bone tissue, along with a greater contact stress of the extreme rods than those located in the central part of the segment. The latter is evidenced by computational finite-element mathematical models [11]. We cannot exclude that the lower density of bone tissue in the epiphyseal zones is of certain significance.

In the absence of bone fusion of the fragments, the rods were in an unstable state much more often. This is due to the fact that under such conditions

Table 3

The frequency of the state of an unstable «rod – bone» connection after screwing the rods produced by different manufacturers

Rod (manufacturer)	Number			
	patients	rods	rods in an unstable state	
			abs.	%
Biomet	25	121	42	35
Stryker	17	76	30	39
HB Ortho	30	138	70	51
ORTHOPAK	19	76	14	18
Total	91	405	156	39

Table 4

The frequency of the state of an unstable «rod – bone» connection in the diaphysis and epimetaphysis of the bone

Rod location	Number		
	rods	rods in an unstable state	
		abs.	%
Diaphysis	217	37	17
Epimetaphysis	188	119	63
Total	405	156	—

Table 5

**The frequency of the state
of an unstable «rod – bone» connection in the presence
and absence of bony fusion of fragments**

Regenerate state	Number of patients	Frequency of rods in an unstable state	
		abs.	%
Bony fusion	63	313	32
Fibro-cartilaginous fusion	18	92	61
Total	91	405	—

the bone cannot fully withstand the load and it increases on the fixing structure and, in particular, at the points of contact of the rod with the bone. In this case, the bone around the rods is in an overload mode, which probably leads to its contact resorption. When bony fusion of fragments occurs, the external fixator enters a “passive” state and the level of contact stresses approaches a minimum.

Considering this regularity, one must realize that an artificial fixator (in particular, an external rod device) has a certain limited resource of a stable state over time. And it must be rationally used to obtain bone fusion within 3–5 months, using early functional load of the injured limb to stimulate the formation of periosteal bone regenerate.

Conclusions

Screwing into the diaphysis of a long bone without pre-drilling the channels for the Biomet, Stryker, HB Ortho rods, equipped with external fixation devices, is accompanied by the destruction of the bone thread.

To achieve the most effective connection of the rod with the bone, it is necessary to screw it into the prepared channel with a diameter that corresponds to the inner diameter of the threaded part of the rod.

When the rods are screwed into the cancellous bone, the profile of the bony thread on many turns has a broken shape with limited contact, in contrast to the formed thread with a regular profile in compact bone.

The treatment of diaphyseal fractures of the bones of the limbs with the use of external devices Biomet, Stryker, HB Ortho within 3–6 months was associated with the loss of a stable state in 35–51 % of rods, mainly those located in the epiphyseal and metaphyseal sections of long bones. Destabilization of the rods was observed much less often under the conditions of using ORTHOPAK devices (18 %).

Conflict of interest. The authors declare no conflict of interest.

References

1. Ukraine's experience with management of combat casualties using NATO's Four-Tier «Changing as Needed» Healthcare System / A. Kazmirchuk, Y. Yarmoliuk, I. Lurin [et al.] // *World Journal of Surgery*. — 2022. — Vol. 46 (12). — P. 2858–2862. — DOI: 10.1007/s00268-022-06718-3.
2. Holt E. Ukraine invasion: 6 months on / E. Holt // *Lancet* (London, England). — 2022. — Vol. 400 (10353). — P. 649–650. — DOI: 10.1016/S0140-6736(22)01635-X.
3. External fixation followed by delayed interlocking intramedullary nailing in high velocity gunshot wounds of the femur / G. N. Dar, S. R. Tak, K. A. Kangoo [et al.] // *Ulusal travma ve acil cerrahi dergisi = Turkish journal of trauma & emergency surgery*. — 2009. — Vol. 15 (6). — P. 553–558.
4. Gustilo R. B. Problems in the management of type III (severe) open fractures: a new classification of type III open fractures / R. B. Gustilo, R. M. Mendoza, D. N. Williams // *The Journal of trauma*. — 1984. — Vol. 24 (8). — P. 742–746. — DOI: 10.1097/00005373-198408000-00009.
5. Litvishko V. Treatment of long bones comminuted fractures using external fixation device / V. Litvishko // *Orthopaedics, traumatology and prosthetics*. — 2016. — No. 4 (605). — P. 40–46. — DOI: 10.15674/0030-59872016440-46. (in russian)
6. Litvishko V. The functional treatment of the diaphyseal tibial fractures using plaster cast or external fixator / V. Litvishko, O. Popsuishapka // *Orthopaedics, traumatology and prosthetics*. — 2015. — No.4 (601). — P. 91–102. — DOI: 10.15674/0030-59872015491-102. (in Ukrainian)
7. Popsuishapka O. K. Functional treatment of diaphyseal fractures of limbs using rod devices for elastically stable connection of fragments (methodological recommendations) / O. K. Popsuishapka, V. O. Lytvishko, I. M. Borovyk. — Kyiv: Ministry of Health of Ukraine, Ukrainian Center for Scientific Information and Patent and Licensing Work, 2014. (in Ukrainian)
8. Lytvishko V. O. B. O. Regularities of formation of osseous regenerate after shaft fracture under the conditions of functional therapy using elastic-stable connection of fragments: Thesis ... Doctor med sci; 14.01.21 — *traumatology and orthopaedics* / V. O. Lytvishko. — Kharkiv, 2018. — 351 p. (in Ukrainian)
9. Biomechanical study of a low-cost external fixator for diaphyseal fractures of long bones / K. JE. Kouassi, O. Cartiaux, L. Fonkoué [et al.] // *Journal of Orthopaedic Surgery and Research*. — 2020. — Vol. 15. — Article ID : 247. — DOI: 10.1186/s13018-020-01777-5.
10. Research and evaluation of the biomechanical structure "fragments-fixator" created in the surgical treatment of fractures of the femoral neck [Issledovaniye i otsenka biomekhanicheskoy konstruktzii «otlomki-fiksator», sozdavayemoy pri khirurgicheskom lechenii perelomov sheyki bedrennoy kosti] / O. Popsuishapka, Ye. Pobel, M. Shevtsova, L. Beloguova // *Orthopaedics, traumatology and prosthetics*. — 2006. — No. 4. — P. 56–62. (in russian)
11. Borovyk I. M. Treatment of diaphyseal fractures of the femur in children with an external rod apparatus [Lecheniye diafizarnykh perelomov bedrennoy kosti u detey vneshnim sterzhnevym apparatom] : Thesis ... Candidat of med sci; 14.01.21 — *traumatology and orthopaedics* / I. M. Borovyk. — Kharkiv, 2010. (in russian).

MECHANICAL AND CLINICAL CHARACTERISTICS
OF THE «ROD – BONE» CONNECTION IN TREATMENT
OF GUNSHOT FRACTURES WITH EXTERNAL ROD DEVICES
FROM VARIOUS MANUFACTURERS

Yu. V. Klapchuk ¹, O. K. Popsuishapka ², V. O. Lytvyshko ³

¹Military and Clinical Center the Northern Region, Kharkiv. Ukraine

²Kharkiv Medical Academy of Postgraduate Education. Ukraine

³Sytenko Institute of Spine and Joint Pathology National Academy of Medical Sciences of Ukraine, Kharkiv

✉ Yuriy Klapchuk, MD, PhD: klapchuks@gmail.com

✉ Olexii Popsuishapka, MD, Prof. in Traumatology and Orthopaedics: alexecorn@gmail.com

✉ Valerii Lytvyshko, MD, DMSci in Traumatology and Orthopaedics: lvaort@yandex.ua