

УДК 616.7-006.34-089.843(045)

## Indications and limits for modular endoprosthetic reconstruction by MUTARS implants in patients with malignant bone tumor (literature review)

O. Vyrva, Ya. Golovina, V. Burlaka, V. Baev, I. Shevchenko, R. Malyk, D. Mikhanovsky, O. Golovina, A. Vyrva, Y. Yutovets

SY «Sytenko Institute of Spine and Joint Pathology, National Academy of Medical Sciences of Ukraine», Kharkiv

*Modular tumor prostheses are well established today for the reconstruction of osseous defects after resection of malignant bone tumors. Almost every joint and even total bones (e. g., total femur or humerus) can be replaced with promising functional results dramatically reducing necessity for ablative procedures. During the last 30 years the 5-year survival rate of megaendoprostheses increased from 20 to 85 %. Although the complication rate with the use of the modern modular endoprostheses is constantly decreasing it is still significantly higher than in primary joint arthroplasty. Together with local tumor recurrence periprosthetic infection remains the most severe complication. Due to constant improvements of prostheses material and surgical techniques, the indications and limits of limb salvage with modular tumor prostheses are continuously changing and to some extent might have to be reconsidered. The typical indication for modular endoprostheses is a large osseous defect after resection of a malignant bone tumor of the metadiaphyseal region of a long bone in the upper or lower extremity. Involvement of major vessels to the tumor is still considered as a contraindication to limb salvage surgery. But limb salvage can nowadays be performed with modular endoprostheses and vascular reconstruction with good oncological and functional results. The functional results after reconstruction of bone defects in tumor surgery are good and can be scored according to Enneking score. In this review authors present the modular endoprosthetic systems MUTARS developed by Implantcast (Buxtehude, Germany) with discussion the indications and contraindications, complications and functional outcomes as well as a surgical technique and postoperative management this category of the patients. Key words: malignant bone tumors, endoprosthetic replacement, modular tumor prosthesis, complications, functional outcomes.*

*Сьогодні модульні пухлинні ендопротези широко використовують для заміщення післярезекційних кістково-суглобових дефектів. Майже будь-який дефект кістки (навіть тотальний плечової або стегнової) чи суглоба можна замінити з високими післяопераційними функціональними результатами та відносно невисокими для індивідуального ендопротезування матеріальними затратами. При цьому зберігається техніка абляційного видалення пухлини. За останні 30 років п'ятирічна виживаність мегаендопротезів збільшилась від 20 до 85 %. Нині рівень ускладнень після модульного ендопротезування знизився, але порівняно з первинним ендопротезуванням суглобів залишився досить високим. Разом з локальними рецидивами пухлин у ділянці хірургічного втручання найскладнішими є інфекційні ускладнення. Розвиток хірургічної техніки та матеріалознавства значно поширюють показання до органозберігальних хірургічних втручань та дають змогу використовувати модульні ендопротези в більшості клінічних випадків. Найпоширенішими показаннями для мегаендопротезування є дефекти кісток після видалення злоякісних пухлин верхньої і нижньої кінцівок. Залучення до пухлинного процесу магістральних судин ще залишається протипоказанням для збереження кінцівки, але вже можливе використання судинної пластики для реконструкції кінцівки з хорошими онкологічними і функціональними результатами. Сьогодні функціональні результати після сучасного модульного пухлинного ендопротезування є доволі високими. Їх зазвичай оцінюють за шкалою Enneking. У поданому огляді представлені результати використання модульної системи пухлинних ендопротезів MUTARS виробництва компанії Implantcast (Німеччина) з обговоренням показань та протипоказань, ускладнень та функціональних результатів таких операцій. Робота містить рекомендації щодо хірургічної техніки та післяопераційного ведення цієї категорії хворих. Ключові слова: злоякісні кісткові пухлини, ендопротезування, модульні пухлинні ендопротези, ускладнення, функціональні результати.*

**Key words:** malignant bone tumors, endoprosthetic replacement, modular tumor prosthesis, complications, functional result

## Introduction

Nowadays the majority of patients with malignant bone tumors can be treated with limb salvage procedures whenever wide margins are achievable [24, 26]. If reasonable from an oncological point of view ablative measures such as amputations or rotation-plasty almost never become necessary. The use of tumor prostheses for reconstruction has gained more and more acceptance over the past few decades and has not shown any adverse effect on local recurrence and survival [6, 30]. While custom-made material was used in the beginning of the era of tumor prostheses, surgeons now accept the modern modular replacement systems as state-of-the-art [14, 45]. Custom-made implants were expensive and time-consuming in fabrication, which sometimes led to a reduced outcome due to delayed optimal therapy. With modern modular endoprostheses, defects of some of the most extreme cases can be reconstructed individually, achieving excellent functional results while saving time and resources [34]. During the last 30 years the 5-year survival rate of megaendoprostheses has increased dramatically from 20 to 85 %, despite patients being generally young and physically active and putting high demands on the material [26]. Nevertheless, the complication rate cannot compete with primary joint arthroplasty [1, 32, 47]. In the following we will give an overview of the modular endoprosthesis system MUTARS, describe postoperative management, summarize its indications, typical complications and limits as well as functional outcome.

**Surgical Technique:** With the use of the Modular Universal Tumor and Revision System (MUTARS-Implantcast, Buxtehude), major osseous defects of the upper and lower extremities can be successfully reconstructed [10]. The modular design allows individual reconstruction of defects in 2-cm steps and torsion adjustments in 5° increments (fig. 1). The different modular components are fixed with screws. Frequently, tumor prostheses are used for reconstruction of the proximal and distal femur, the proximal tibia, and proximal humerus. Even replacements of total bones, such as the total femur or humerus including the adjacent joints, are becoming increasingly common [49]. Nowadays stem-anchorage of most tumor prostheses can be accomplished without bone cement. We use hydroxyapatite-coated titanium stems with a hexagonal shape that provide excellent primary rotation stability (fig. 1). The usual stems have a length of 12 cm whereas the diameter is planned individually on digital X-rays (usually not measuring below the 12-mm core diameter). Cemented anchorage in tumor prostheses is mostly indicated in older patients (over 60 years of age), those with advanced osteopenia, prolonged




**Fig. 1.** MUTARS proximal femur with hydroxyapatite-coated titanium stem. The hexagonal shape provides excellent primary rotation stability. The modular design allows torsion adjustments in 5° increments

preoperative immobilization or neoadjuvant chemotherapy and cases in which press-fit anchorage in the metadiaphyseal region is impossible. The articulating parts are usually connected with a rotating hinge and a polyethylene inlay. In cases in which extraordinary forces occur, such as total or distal femoral replacement or after extraarticular knee-joint resections, the new PEEK-Optima lock shows excellent properties for femoro-tibial locking. It has been available since 2003 and shows a fatigue strength that is five times higher than in polyethylene. Refixation of muscles and tendons (e. g., gluteal muscles in proximal femur, patellar ligament in proximal tibia, or rotator-cuff in proximal humerus) is usually accomplished by sewing to a MUTARS attachment tube (Implantcast, Buxtehude) tied around the prosthesis [44] (fig. 2). Moreover, this strong and durable yet flexible material (polyethylene terephthalate-PET) is routinely used for refixation of the gastrocnemius flap for defect-coverage, especially in the proximal tibia. In these cases, where tension-free primary wound closure is hardly possible, an additional mesh-graft often becomes unavoidable. Besides its use for refixation of soft tissue and tendons, the MUTARS attachment tube provides excellent results in reconstruction of capsular structures (fig. 2) in proximal femur replacement. In combination with a bipolar cup we were able to completely prevent postoperative dislocation in our patient collective [37, 39].

## Postoperative Management

Postoperatively all patients are treated with intravenous antibiotics (e. g., cephalosporin of third



**Fig. 2.** MUTARS attachment tube in proximal femur a before and b after closure and fixation of the neo-reconstruction in combination with a bipolar cup capsule

generation) for 3–7 days, followed by oral medication until completion of wound healing. Moreover, patients are informed about the necessity of prophylactic intake of antibiotics in cases of possible bacteremia (e. g., systemic/local infections or dental treatment) preventing the danger of hematogenous seeding and late endoprosthetic infections. Patients with proximal humerus reconstruction are immobilized for 4–6 weeks in a Gilchrist-bandage in which training of the elbow, wrist, and fingers usually remains unrestricted. We follow a relatively strict immobilization regimen after cementless implantation of tumor prostheses in the lower extremities: 6 weeks of 10 kg weight bearing followed by a stepwise increase of 5–10 kg per week (depending on the patient's weight) until achievement of full weight bearing. In patients with proximal femur replacement in combination with a bipolar cup and MUTARS attachment tube, range of motion of the hip joint is unrestricted, even immediately after the operation. When an acetabular cup is implanted additionally, bed rest of 4 weeks is necessary to prevent possible dislocation until the full stability of the scar tissue of the “new” capsule is developed. Range of motion in patients with distal femur replacement is only limited (4 weeks immobilization in extension) when a gastrocnemius muscle flap is performed for better coverage of the prosthesis. In proximal tibia replacement, immobilization of the extended knee joint is essential due to the reattachment of the patellar ligament to the attachment tube. This is usually accomplished by wearing a knee immobilizer for 4 weeks. From the fifth week, post-operative mobilization has to be started but should be restricted to a maximal flexion of 90° [10, 31–33, 45]. Otherwise an accelerated wear of the polyethylene bushing is at risk. When a mesh graft is necessary to allow tension-free skin closure (especially in distal femur or proximal tibia) we usually achieve excellent results with an additional vacuum-sealing of the graft for the first 5 days. After resection of tumors

involving the knee joint, eminent attention has to be turned to weakness or paralysis of the anterior and lateral compartment muscles, resulting in foot drop. The common fibular nerve with its terminal branches is explored routinely and may be affected by hooks as well as edema or hematoma. Mild pressure or stretching of the nerve can produce a temporary impairment of local circulation that interrupts normal nerve conduction. If foot drop is apparent, a prophylaxis of plantar flexion contracture should be started immediately and an ankle-foot orthosis (AFO) should be prescribed. The lesion is usually incomplete, and in most cases the function recovers within a few months [29, 42, 45].

### Complications

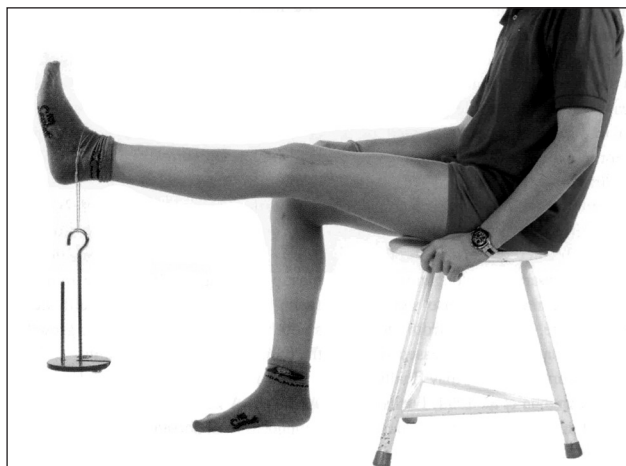Local recurrence is the worst possible complication, accompanied as it is by a dismal prognosis [40]. The rate of local recurrence after limb salvage with tumor prostheses in the literature ranges from 1 to 9%, which is comparable to ablative procedures [34, 47]. To avoid this result at least a wide resection according to Enneking (1988) is required. The 5- to 10- year survival rate for modern megaendoprostheses averages from 69 to 90% [10, 12, 36]. Due to their lower general exposure, reconstructions of the upper extremities and hip have higher survival rates than reconstructions around the knee joint [29, 36–38, 45]. The most common complications leading to explantation of the prosthesis are aseptical loosening, periprosthetic infection, and fracture of the stem or adjacent bone [4, 14, 22, 45]. The literature indicates infection rates from 1 to 36% with the lowest rates for upper extremity and the highest rates for reconstruction of the proximal tibia [12, 13]. In case of infection, a two-stage approach with a temporary static cement spacer charged with antibiotics prior to reimplantation of the prosthesis usually becomes unavoidable [5, 48]. Only in early infections is a one-stage procedure with debridement, pulse lavage, and replacement of the polyethylene bushing

possibly sufficient [5]. Deep infection constitutes the most serious complication at which, when uncontrollable, secondary amputation frequently (19–46 %) becomes necessary [29, 42]. It increasingly seems as if the routine use of an antibacterial silver coating in MUTARS tumor prostheses is able to reduce the rate of infection without any toxicological side effects [5, 10]. Aseptic loosening of the stem occurs in up to 27 % in the lower extremity. In these cases revision surgery is almost always feasible [23]. Even stem fractures with an incidence of 1–22 % are usually reparable [5, 13]. The complications described so far require major operations with at least a partial replacement of the prosthesis. Wear of the polyethylene bushing necessitates only minor surgical treatment. Failure of the bushing is not as much a «complication» as a normal side effect of extensive usage, especially in young and active patients. Wear of the polyethylene manifests in increasing instability of the joint. A repair should be performed early because the debris might induce aseptic loosening [26, 41]. The most common complication in proximal humerus replacement is the high dislocation rate due to resection of the rotator-cuff [43]. It can be reduced by reattaching the remaining muscles to a MUTARS attachment tube [9, 12]. The dislocation rate in proximal femur replacement is reported in the literature with an incidence of up to 20 % [11, 32, 39]. Many surgeons use of a bipolar cup combined with the MUTARS attachment tube for reconstruction of the joint capsule and reattachment of the muscles (abductor muscles, iliopsoas muscle) for reduced dislocation to 0 % [10, 39]. Also in replacement of the proximal tibia, the attachment tube excelled as a reliable way to restore the extensor mechanism. Refixation of the patellar ligament to the tube if necessary augmented with a gastrocnemius flap leads to good functional results in active knee extension (fig. 3). A relevant weakening of the extensors, which occurs frequently if the tendon is directly fixed to the prosthesis, can be avoided.

The new antibacterial silver coating of MUTARS prostheses can significantly reduce the rate of infection without toxicological side effects because many of last orthopaedic reviews show promising positive results of using this coating surface.

### Indications and Limits

Constant improvements of prostheses material and surgical techniques lead to a steadily increasing number of patients with limb-sparing procedures using modular tumor prostheses. The typical indication for modular endoprostheses is a large osseous defect after resection of a malignant bone tumor of the meta-diaphyseal region of a long bone in the upper or lower



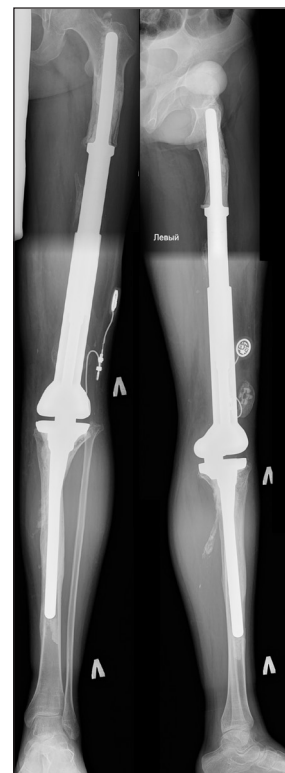**Fig. 3.** Functional outcome after proximal tibia replacement and refixation of the patellar ligament to the attachment tube

extremity. Involvement of major vessels by the tumor is still considered as a contraindication to limb salvage surgery [19]. But even in these cases patients can be saved from mutilating procedures. Limb salvage can nowadays be performed with modular endoprostheses and vascular reconstruction with good oncological and functional results. Thus the need for rotationplasty or amputation is decreasing [20]. Another limitation for the usage of tumor prostheses is the infiltration of the extensor mechanism, especially in malignancies around the knee. If extraarticular resection becomes necessary the extensor muscles should be at least partially preserved. Otherwise defect coverage is hardly possible and limb function is unsatisfying. But even when large parts of the quadriceps femoris muscles have to be resected, the extensor mechanism can be augmented by a muscle flap of the biceps femoris and gastrocnemius reattached to a MUTARS attachment tube. If more stability is needed an additional orthosis with stance security can be prescribed. Tumor prostheses reach their limits in cases of deep infections with poor soft tissue condition (e. g., extensive wound necrosis or skin induration due to irradiation). In patients with infections related to tumor prosthesis, limb salvage fails in approximately 30 % of cases, depending on the soft tissue condition [5]. Even the new antibacterial silver coating is unable to countervail the poor soft tissue condition so that ablative surgery should be performed early to avoid repeated revision surgery.

### Tumor Prosthesis in Children

Although reconstruction with modular endoprostheses has become the treatment of choice in adults, this cannot be transferred to bone tumors during childhood. Many surgeons still believe that the use of tumor prostheses is not a reasonable approach before the age

of 11–13 [3, 34]. The combination of significant limb length discrepancies at maturity and the difficulties with participating in active rehabilitation programs for children compromised the good results achieved in adults. In very young patients limb ablation including rotationplasty is still a common procedure, because it is not usually accompanied by relevant surgical problems. As a one-step operation rotationplasty may be performed with good functional results [30, 46], but like amputation it is a mutilating procedure. Especially in children that are close to puberty its stigmatizing effect is not to be neglected. Nowadays this procedure should be reserved for selected cases. The reasonable alternative of osteoarticular allografts is accompanied by a very high complication rate and cannot prevent growth impairment [27]. To date, endoprosthesis systems are still cautiously used in children due to complications caused by the limb length inequality and the frequent surgery necessary for elongation procedures. The invasive methods cause significant hospitalization time, time off from school, extensive scar formation, and increased risk of infection. In the worst cases this may finally lead to amputation [6, 16, 28, 33]. For almost 30 years modular expandable prostheses have been on the market. The basic technique for lengthening usually consists of a fixed stem with a screw extension mechanism, as in, for example, the Lewis expandable adjustable prosthesis (LEAP), introduced in 1983 [17, 18] or later in the Howmedica Modular Reconstruction System (HMRS) with custom-made growth modules housed within the prosthesis [7]. The elongation is performed by insertion of a chuck key to turn the screw mechanism, thereby expanding the tubular portion of the prosthesis [21]. Other designs focus on modular systems in which a midsection is sequentially replaced by a longer one whenever elongation becomes necessary. But in both designs there is still the need for surgery with all the drawbacks mentioned above, including neurological compromise due to stretch injuries, vascular injury, and loss of motion [15, 25, 35]. The maximal increase in length is limited to approximately 2 cm for each elongation procedure. Perhaps the progress in modern growing prostheses such as the Phenix Growing Prosthesis (Phenix Medical, Paris, France) [50] or new generations of the HMRS [8] will solve some of these problems. The mentioned prostheses usually consist of two hollow tubes containing a spring-loaded coil that is immobilized by a solid piece of plastic. When length adjustment is required the plastic is heated (for example by an external electromagnetic field), which melts it and releases the spring causing elongation until the plastic cools again. If possible minimal resurfacing using a press-fit prosthetic stem with a smooth surface



**Fig. 4.** MUTARS growing prosthesis in distal femur replacement. Note the small implant connected to an internal motor that is implanted subcutaneously and can be controlled by an external device

can preserve the growth plate in the uninvolved side of the joint. The new MUTARS Expand uses a similar approach. A motor housed in the prosthesis is connected to a subcutaneous receiver and can be activated and controlled by an external device, allowing exact length adjustment (up to 10 cm) without any surgery (fig. 4). Both systems can be controlled in the outpatient clinic without hospitalization. All these prostheses are designed to bear the corresponding loads over several years but they are only adjustable in length and do not grow concomitantly in strength and breadth. The devices might be at greater risk of breaking under the adult weight and finally would have to be replaced by a permanent implant. After unsatisfying results at the beginning of the era of growing prostheses, the first experiences with the new systems are promising. But whether they will prove of value in practice can only be answered over time.

### Functional Results

The functional results after reconstruction of bone defects in tumor surgery are promising and can be scored according to Enneking et al. [2]. Herein subjective parameters (contentedness, pain, etc.) as well as functional parameters (range of motion, walking distance, use of walking aids, etc.) play a role. A score of 100 % means unlimited function of the affected

extremity. In the literature the average range shown is 60–90 % [23, 26, 31, 36]. Munster Group, Germany achieved the best results in patients with proximal tibia replacement (83 %) followed by distal femur replacement (80 %). Patients with proximal femur replacement achieved an average score of 70 % [10]. It has to be noted that, especially in elderly patients, they retain a Trendelenburg gait and most need a cane on the healthy side when performing longer walks, even if the gluteal muscles are reattached to the MUTARS attachment tube. Patients with replacement of the proximal humerus achieved an average of «only» 70 %, which can be explained by the impaired range of motion of the shoulder joint. Due to resection of sizable parts of the rotator-cuff and deltoid muscle, which is unpreventable in removal of the tumor, patients can hardly elevate the arm more than 60° and abduct more than 30°. All patients are able to move their hand to their mouth [10]. The new inverse shoulder prostheses might improve the functional outcome by restoring the function of the rotator-cuff, since it might be possible to preserve the axillary nerve and relevant parts of the deltoid muscle.

## Summary

Limb salvage with tumor prostheses has become a routine procedure leading to good functional results. But especially in the case of young and active patients, who represent the «typical» bone tumor patient, the material is pushed to its physical limits; mechanical complications seem to be almost unavoidable. Fortunately revision surgery of these complications is almost always successful. The use of the MUTARS attachment tube can prevent dislocations after proximal femur replacement and lead to better functional results in reconstructions of the proximal tibia. The most severe complication besides local recurrence remains periprosthetic infection. Due to constant improvements of prostheses material and surgical techniques, the indications and limits of limb salvage with modular tumor prostheses are continuously changing and to some extent might have to be reconsidered.

## References

- 151 endoprosthetic reconstructions for patients with primary tumors involving bone / M. R. Safran, M. H. Kody, R. S. Namba [et al.] // *Contemp. Orthop.* — 1994. — Vol. 29. — P. 15–25.
- A system for the functional evaluation of reconstructive procedures after surgical treatment of tumors of the musculoskeletal system / W. F. Enneking, W. Dunham, M. C. Gebhardt [et al.] // *Clin. Orthop. Relat. Res.* — 1993. — Vol. 286. — P. 241–246.
- Amputation and adriamycin in primary osteosarcoma / E. P. Cortes, J. F. Holland, J. J. Wang [et al.] // *Engl. J. Med.* — 1974. — Vol. 291. — P. 998–1000.
- Aseptic loosening in cemented custom-made prosthetic replacements for bone tumours of the lower limb / P. S. Unwin, S. R. Cannon, R. J. Grimer [et al.] // *J. Bone Joint Surg.* — 1996. — Vol. 78-B. — P. 5–13.
- Characteristics and outcome of infections associated with tumor endoprostheses / J. Harges, C. Gebert, A. Schwappach [et al.] // *Arch. Orthop. Trauma Surg.* — 2006. — Vol. 126. — P. 289–296.
- Complications and surgical indications in 144 cases of non-metastatic osteosarcoma of the extremities treated with neoadjuvant chemotherapy / P. Ruggieri, R. De Cristofaro, P. Picci [et al.] // *Clin. Orthop. Relat. Res.* — 1993. — Vol. 295. — P. 226–238.
- Endoprostheses in children: first results / R. Kotz, C. Schiller, R. Windhager, P. Ritschl // *Limb salvage: major reconstructions in oncologic and nontumoral conditions* // F. Langlais, B. Tomeno (eds). — Berlin Heidelberg New York: Springer Verlag, 1991. — P. 591–599.
- Endoprosthesis management of the extremities of children after resection of primary malignant bone tumors / P. Krepler, M. Dominkus, C. D. Toma, R. Kotz // *Orthopade.* — 2003. — Vol. 32. — P. 1013–1019.
- Endoprosthetic reconstruction for malignant upper extremity tumors / A. Aumar, J. J. Eckardt, F. R. Eilber [et al.] // *Clin. Orthop. Relat. Res.* — 1999. — Vol. 360. — P. 207–220.
- Endoprosthetic reconstruction in 250 patients with sarcoma / G. Gosheger, C. Gebert, H. Ahrens [et al.] // *Clin. Orthop. Relat. Res.* — 2006. — Vol. 450. — P. 164–171.
- Endoprosthetic replacement for primary malignant tumors of the proximal femur / Y. Kabukcuoglu, R. J. Grimer, R. M. Tillman, S. R. Carter // *Clin. Orthop. Relat. Res.* — 1999. — Vol. 358. — P. 8–14.
- Endoprosthetic replacement of the proximal humerus. Long-term results / D. Kumar, R. J. Grimer, A. Abudu [et al.] // *J. Bone Joint Surg.* — 2003. — Vol. 85-B. — P. 717–722.
- Endoprosthetic replacement of the proximal tibia / R. J. Grimer, S. R. Carter, R. M. Tillman [et al.] // *J. Bone Joint Surg.* — 1999. — Vol. 81-B. — P. 488–494.
- Etiology and results of tumor endoprosthesis revision surgery in 64 patients / P. Z. Wirganowicz, J. J. Eckardt, F. J. Dorey [et al.] // *Clin. Orthop. Relat. Res.* — 1999. — Vol. 358. — P. 64–74.
- Function and complications after ablative and limb-salvage therapy in lower extremity sarcoma of bone / A. J. Renard, R. P. Veth, H. W. Schreuder [et al.] // *J. Surg. Oncol.* — 2000. — Vol. 73. — P. 198–205.
- Interrelationships of clinical outcome, length of resection, and energy cost of walking after prosthetic knee replacement following resection of a malignant tumor of the distal aspect of the femur / A. Kawai, S. I. Backus, J. C. Otis, J. H. Healey // *J. Bone Joint Surg.* — 1998. — Vol. 80-A. — P. 822–831.
- Kenan S. Limb salvage in pediatric surgery. The use of the expandable prosthesis / S. Kenan, M. M. Lewis // *Orthop. Clin. North Am.* — 1991. — Vol. 22. — P. 121–131.
- Kenan S. Limb-sparing surgery in skeletally immature patients with osteosarcoma. The use of an expandable prosthesis / S. Kenan, N. Bloom, M. M. Lewis // *Clin. Orthop. Relat. Res.* — 1991. — Vol. 270. — P. 223–230.
- Lawrence W. Jr. Concepts in limb-sparing treatment of adult soft tissue sarcomas / W. Lawrence Jr. // *Semin Surg. Oncol.* — 1988. — Vol. 4. — P. 73–77.
- Leggon R. E. Limb salvage surgery with vascular reconstruction / R. E. Leggon, T. S. Huber, M. T. Scarborough // *Clin. Orthop. Relat. Res.* — 2001. — Vol. 387. — P. 207–216.
- Lewis M. M. The expandable prosthesis: tumor prosthesis in children / M. M. Lewis, J. Pafford, W. J. Spiers // *Bone tumor management* / R. Coombs, G. Friedlaender (eds). — London: Butterworths, 1987.
- Limb salvage surgery for primary bone sarcoma of the lower extremities: long-term consequences of endoprosthetic reconstructions / S. J. Ham, H. Schraffordt Koops, R. P. Veth

- [et al.] / *Ann. Surg. Oncol.* — 1998. — Vol. 5. — P. 423–436.
23. Limb salvage with tumor endoprostheses for malignant tumors of the knee / W. Plotz, H. Rechl, R. Burgkart [et al.] // *Clin. Orthop. Relat. Res.* — 2002. — Vol. 405. — P. 207–215.
  24. Local and systemic control after ablative and limb sparing surgery in patients with osteosarcoma / M. Sluga, R. Windhager, S. Lang [et al.] // *Clin. Orthop. Relat. Res.* — 1999. — Vol. 358. — P. 120–127.
  25. Local complications after limb-salvage surgery for pediatric bone tumours: a pictorial essay / P. S. Babyn, C. E. Wihlborg, J. K. Tjong [et al.] // *Can. Assoc. Radiol. J.* — 2001. — Vol. 52. — P. 35–42.
  26. Long-term followup of uncemented tumor endoprostheses for the lower extremity / F. Mittermayer, P. Krepler, M. Dominkus [et al.] // *Clin. Orthop. Relat. Res.* — 2001. — Vol. 388. — P. 167–177.
  27. Long-term results of allograft replacement in the management of bone tumors / H. J. Mankin, M. C. Gebhardt, L. C. Jennings [et al.] // *Clin. Orthop. Relat. Res.* — 1996. — Vol. 324. — P. 86–97.
  28. Long-term results of the cooperative German-Austrian-Swiss osteosarcoma study group's protocol COSS-86 of intensive multidrug chemotherapy and surgery for osteosarcoma of the limbs / N. Fuchs, S. Bielack, D. Epler [et al.] — 1998. — *Ann. Oncol.* — Vol. 9. — P. 893–899.
  29. Malawer M. M. Prosthetic survival and clinical results with use of large-segment replacements in the treatment of high-grade bone sarcomas / M. M. Malawer, B. Chou // *J. Bone Joint Surg.* — 1995. — Vol. 77-A. — P. 1154–1165.
  30. Malignant tumor of the distal part of the femur or the proximal part of the tibia: endoprosthetic replacement or rotation-plasty. Functional outcome and quality-of-life measurements / A. Hillmann, C. Hoffmann, G. Gosheger [et al.] // *J. Bone Joint Surg.* — 1999. — Vol. 81. — P. 462–468.
  31. Modular megaprosthesis for proximal femoral tumors / I. Ilyas, R. Pant, A. Kurar [et al.] // *Int. Orthop.* — 2002. — Vol. 26. — P. 170–173.
  32. Modular prosthetic replacement of the proximal femur after resection of a bone tumour a long-term follow-up / D. Donati, M. Zavatta, E. Gozzi [et al.] // *J. Bone Joint Surg.* — 2001. — Vol. 83. — P. 1156–1160.
  33. Modular uncemented prosthetic reconstruction after resection of tumours of the distal femur / R. Capanna, H. G. Morris, D. Campanacci [et al.] // *J. Bone Joint Surg.* — 1994. — Vol. 76-B. — P. 178–186.
  34. Osteosarcoma in children: long-term functional analysis / P. U. Tunn, P. Schmidt-Peter, D. Pomraenke, P. Hohenberger // *Clin. Orthop. Relat. Res.* — 2004. — Vol. 421. — P. 212–217.
  35. Paley D. Problems, obstacles, and complications of limb lengthening by the Ilizarov technique / D. Paley // *Clin. Orthop. Relat. Res.* — 1990. — Vol. 250. — P. 81–104.
  36. Prosthetic and extremity survivorship after limb salvage for sarcoma. How long do the reconstructions last? / S. M. Horowitz, D. B. Glasser, J. M. Lane, J. H. Healey // *Clin. Orthop. Relat. Res.* — 1993. — Vol. 293. — P. 280–286.
  37. Prosthetic reconstruction of the proximal femur after resection for bone tumors / H. G. Morris, R. Capanna, M. Del Ben, D. Campanacci // *J. Arthroplasty.* — 1995. — Vol. 10. — P. 293–299.
  38. Prosthetic replacement of the distal femur for primary bone tumours / P. Roberts, D. Chan, R. J. Grimer [et al.] // *J. Bone Joint Surg.* — 1991. — Vol. 73-B. — P. 762–769.
  39. Reconstruction of the extensor mechanism after proximal tibia endoprosthetic replacement / J. Bickels, J. C. Wittig, Y. Kollender [et al.] // *Arthroplasty.* — 2001. — Vol. 16. — P. 856–862.
  40. Relationship of chemotherapy-induced necrosis and surgical margins to local recurrence in osteosarcoma / P. Picci, L. Sangiorgi, B. T. Rougraff [et al.] // *J. Clin. Oncol.* — 1994. — Vol. 12. — P. 2699–2705.
  41. Revision of the Kotz type of tumour endoprosthesis for the lower limb / F. Mittermayer, R. Windhager, M. Dominkus [et al.] // *J. Bone Joint Surg.* — 2002. — Vol. 84-B. — P. 401–406.
  42. Risk of amputation following limb salvage surgery with endoprosthetic replacement, in a consecutive series of 1261 patients / L. M. Jeys, R. J. Grimer, S. R. Carter, R. M. Tillman // *Int. Orthop.* — 2003. — Vol. 27. — P. 160–163.
  43. Ross A. C. Endoprosthetic replacement of the proximal humerus / A. C. Ross, J. N. Wilson, J. T. Scales // *J. Bone Joint Surg.* — 1987. — Vol. 69-B. — P. 656–661.
  44. Soft tissue reconstruction of megaprotheses using a trevira tube / G. Gosheger, A. Hillmann, N. Lindner [et al.] // *Clin. Orthop. Relat. Res.* — 2001. — Vol. 393. — P. 264–271.
  45. Survivorship analysis of 141 modular metallic endoprostheses at early follow up / E. N. Zeegen, L. A. Aponte-Tinao, F. J. Hornicek [et al.] // *Clin. Orthop. Relat. Res.* — 2004. — Vol. 420. — P. 239–250.
  46. The limits of saving the extremity-amputation versus resection / R. Kotz, P. Ritschl, D. Kropetz [et al.] // *Z. Orthop. Ihre Grenzgeb.* — 1992. — Vol. 130. — P. 299–305.
  47. The UCLA experience in limb salvage surgery for malignant tumors / J. J. Eckardt, F. R. Eilber, F. J. Dorey, J. M. Mirra // *Orthopedics.* — 1985. — Vol. 8. — P. 612–621.
  48. Two-stage revision for infected endoprostheses used in tumor surgery / R. J. Grimer, M. Belthur, C. Chandrasekar [et al.] // *Clin. Orthop. Relat. Res.* — 2002. — Vol. 395. — P. 193–203.
  49. Ward W. G. Total femoral endoprosthetic reconstruction / W. G. Ward, F. Dorey, J. J. Eckardt // *Clin. Orthop. Relat. Res.* — 1995. — Vol. 316. — P. 195–206.
  50. Wilkins R. M. The Phenix expandable prosthesis: early American experience / R. M. Wilkins, A. Soubeiran // *Clin. Orthop. Relat. Res.* — 2001. — Vol. 382. — P. 51–58.

DOI: <http://dx.doi.org/10.15674/0030-598720144128-134>

Article was received 20.11.2014

## ПОКАЗАННЯ ТА ОБМЕЖЕННЯ ДО МОДУЛЬНОГО ЕНДОПРОТЕЗУВАННЯ ІМПЛАНТАТАМИ MUTARS У ПАЦІЄНТІВ ЗІ ЗЛОЯКІСНИМИ ПУХЛИНАМИ (ОГЛЯД ЛІТЕРАТУРИ)

О. Є. Вирва, Я. О. Головіна, В. В. Бурлака, В. О. Баєв, І. В. Шевченко, Р. В. Малик,  
Д. О. Михановський, О. О. Головіна, О. О. Вирва, Ю. О. Ютовець

ДУ «Інститут патології хребта та суглобів ім. проф. М. І. Ситенка НАМН України», Харків