

УДК 616.71.004.64-089.843

DOI: <http://dx.doi.org/10.15674/0030-59872024179-88>

Modern Technologies for Bone Defect Replacement (Literature Review)

O. A. Buryanov ¹, V. P. Kvasha ¹, V. O. Kuprii ²,
Yu. L. Sobolevskiy ¹, V. S. Chornyi ¹, H. H. Hliba ¹, V. O. Rohozynskiy ³

¹ Bogomolets National medical university, Kyiv, Ukraine

² SSI «Center for innovative medical technologies of the national academy of sciences of Ukraine», Kyiv

³ National military medical clinical centre «Main military clinical hospital», Kyiv, Ukraine

Information is provided regarding the materials used to replace bone defects caused by gunshot wounds. Materials and various techniques for replacing bone defects of the limbs are described. Goal. Conduct an analysis of surgical technologies and materials for the replacement of bone defects, by analyzing literary sources. Methods. In three reputable databases (PubMed, Scopus, and Web of Science), an analysis of the latest scientific studies devoted to the treatment of defects of long tubular bones in the period from 2015 to 2022 was carried out. The search was carried out using the keywords "bone defects", "autograft", "allograft", "Ilizarov method", "Masquelet method", "biocomposite materials". The results. Analysis of osteoinductive and osteoconductive properties of auto- and allografts, modern biocomposite materials. Established advantages and disadvantages. The contemporary analysis of literary sources does not provide an objective comparative assessment of the effectiveness of the treatment of bone defects according to the Masquelet and Ilizarov method due to the lack of a sufficient number of randomized studies, which is the basis for further targeted research. Conclusions. Treatment of bone tissue defects of various genesis is an urgent problem of modern orthopedics and traumatology. The wide range of treatment options is proof that no single strategy works for every patient, just as there is no perfect universal material to fill and ensure bone regeneration in the defect site. A promising direction is the search for new or a combination of known materials and methods, which are able to maximally provide compensation for these pathological conditions.

Наведено інформацію стосовно матеріалів, які застосовуються для заміщення кісткових дефектів, утворених унаслідок вогнепальних поранень. Описано матеріали та різні техніки для заміщення кісткових дефектів кінцівок. Мета. Провести аналіз хірургічних технологій та матеріалів при заміщенні кісткових дефектів, шляхом аналізу літературних джерел. Методи. У трьох реєстрованих базах даних (PubMed, Scopus і Web of Science) проведено аналіз останніх наукових досліджень, присвячених темі лікування дефектів довгих трубчатих кісток у період з 2015 по 2022 роки. Пошук проведено за ключовими словами «кісткові дефекти», «аутотрансплантат», «алотрансплантат», «метод Ілізарова», «метод Masquelet», «біокомпозитні матеріали». Результати. Проведено аналіз остеоіндуктивних та остеокондуктивних властивостей ауто- та алотрансплантатів, сучасних біокомпозитних матеріалів. Встановлені переваги та недоліки. Аналіз сучасних літературних джерел не дають об'єктивної порівняльної оцінки результативності лікування кісткових дефектів за методикою Masquelet та Ілізарова в зв'язку з відсутністю достатньої кількості рандомізованих досліджень, що є підґрунтям для подальших цілеспрямованих досліджень. Висновки. Лікування дефектів кісткової тканини різного генезу актуальною проблемою сучасної ортопедії і травматології. Широкий спектр варіантів лікування є доказом того, що жодна стратегія не працює для кожного пацієнта, як не існує ідеального універсального матеріалу для заповнення та забезпечення регенерації кістки в місці дефекту. Перспективним напрямком є пошук нових, або комбінація відомих матеріалів та методів, які в змозі максимально забезпечити компенсацію цих патологічних станів. Ключові слова. Кісткові дефекти, аутотрансплантат, алотрансплантат, метод Ілізарова, метод Masquelet, біокомпозитні матеріали.

Keywords. Bone defects, autograft, allograft, Ilizarov method, Masquelet method, biocomposite materials

Introduction

Bone tissue defects may result from a variety of causes: tumors of the musculoskeletal system, osteofibrous dysplasia, congenital defects, infections, and arise as a result of traumatic high-energy injuries [1].

Bone defects are a pathological condition with a loss of bone tissue that cannot self-repair, even with appropriate surgical stabilization. This condition is characterized as a critical defect [2].

According to statistical data, bone defects occur in 0.4 % of all individuals with bone fractures, which in absolute numbers amounts to about one million cases of skeletal trauma annually. Bone defects most commonly develop under the open high-energy traumas, and constitute 11.4 % of all individuals with open bone fractures [3].

The treatment of firearm bone tissue defects, resulting from the use of firearms or explosive weapons, is a pressing current issue. Such injuries arise from the high-energy combined impact, and lead to polystructural damages [4].

Systematic studies of injury characteristics among NATO allied forces in Iraq and Afghanistan show that limb injuries are the most common, accounting for 39 % to 49 % of injuries compared to the other ones [5].

A characteristic trend in modern combat limb injuries is an increase in the number of individuals with bone tissue defects. According to Ukrainian authors, in 2018, bone tissue defects were observed in 5.95 % of the wounded with combat limb trauma, and by 2023, the proportion of such injuries increased to 7.1 % of cases [6,7].

Patients with bone tissue defects require staged, timely treatment tactics, considering the condition of soft tissues, vascular-nerve disorders, and infectious complications, which dictate prolonged terms of rehabilitative treatment.

Thus, the treatment of segmental bone defects is one of the challenges of modern orthopedics due to the severity of high-energy injuries, which are so characteristic in modern world.

Objective: to analyze surgical technologies and materials for replacing bone defects through the review of literature sources.

Materials and Methods

A literature review was conducted in three databases (PubMed, Scopus, and Web of Science) on the treatment of long bone defects from 2015 to 2022. The search was performed using keywords such as bone defect, nonunion, auto- and allograft trans-

plantation, Ilizarov method — bone transport (BT), Masquelet method — induced membrane, free vascularized fibular graft (FVFG). Titles and abstracts were reviewed during the selection process, and potentially relevant articles were thoroughly studied and assessed for inclusion.

Inclusion Criteria: Full-text articles were included if they presented clinical studies confirming the treatment of patients with segmental bone defects and non-union using distraction osteogenesis (DO), induced membrane technique (IMT), free vascularized fibular graft (FVFG), or auto- and allograft transplantation. Articles were selected if they contained treatment outcomes and complications based on a sufficient number of patients (at least twenty). Additionally, comparative studies were considered if they provided quantitative data evaluating the mentioned treatment methods. **Exclusion Criteria:** Case reports, pilot studies, and preliminary research were excluded from the analysis.

In total, among the databases mentioned above, 1 041 scientific works were assessed. Out of these, 50 full-text clinical articles and reviews were selected based on the inclusion and exclusion criteria (Figure).

Results

For bone defect replacement, the most frequently used methods are: auto- and allografts and biocomposite materials, as well as their combinations.

Autoplasty

Autologous bone grafting is characterized by complete biological compatibility, by which rejection issues could be avoided. It facilitates optimal integration, and further consolidation [8].

This method is effective for the restoration of bone defects resulting from firearm injuries, trauma, infectious diseases, and iatrogenic complications.

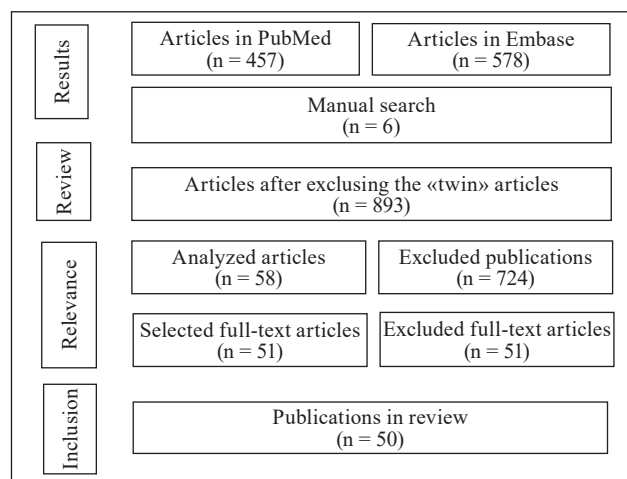


Figure. Literature review findings

The key factor influencing the distribution of methodological approaches in the use of autotransplantation is the individual parameters of the transplant.

The selection of a specific type of transplant depends on the size and nature of the defect, as well as the patient's needs. Each type of autotransplant has its own characteristics that can influence its effectiveness in specific cases. The parameters of autotransplants vary depending on their origin [9, 10].

The characteristics of autotransplants are presented in Table 1.

Dense cortical grafts provide greater mechanical support. The osteoconduction parameter indicates the ability of the graft to create a supportive framework for the growth of new bone and reflects its ability to promote the differentiation of mesenchymal stem cells into osteogenic cells. Spongy grafts from various sources have a higher concentration of native osteogenic cells and growth factors, which contributes to the rapid formation of new bone [11].

Vascularized autotransplants are the most commonly used method and are considered the ideal donor. Vascularized bone grafts (VBG) are widely used for the reconstruction of bone defects in various locations. Free vascularized bone grafting is typically used for defects smaller than 5–6 cm, while this

method can also be employed for larger defects due to vascularization, without the risk of infection [12].

Vascularized fibular grafts (VFG) are mainly used on the humeral, radial, or ulnar bones in cases of persistent non-union when traditional bone grafting has been unsuccessful, or for bone defects larger than 6 cm. Additionally, VFG is considered the standard method for treating large bone defects and allows for the reconstruction of soft tissue loss through a one-stage surgical procedure with high infection resistance due to autonomous vascularization [13].

The fibula exhibits a unique anatomical characteristic, as it receives dual vascular supply from both the endosteal and periosteal sources, originating from the fibular artery and vein, respectively. Moreover, blood circulation to the proximal segment of the fibula is facilitated by the anterior tibial artery, providing an additional viable option when needed. Notably, the vascular structures within the fibula demonstrate a relatively substantial diameter, ranging from 1.5 to 3 mm, thereby simplifying the surgical anastomosis process with the recipient's vascular network. Additionally, the fibula's triangular cross-sectional shape and tubular structure, akin to the high cortical bone density, confer remarkable resistance to torsional stresses [14].

Table 1

Parametric characteristics of autotransplants

Type of Autotransplant	Maximum Size	Vascularization	Osteogenesis	Osteoinduction	Osteoconduction	Mechanical Strength
Transplant	5–75 ml	—	++	+	+/-	-
Spongy (Cancellous) transplant	3–70 cm ³	—	++	+	+/+	+
Cortical transplant	37 cm	—	+	+/-	++	++
Vascularized fibular graft (VFG)	40 cm	+++ Small saphenous artery	+	+	+++	+++
Vascularized iliac crest graft	10 cm	+++ Deep flexor pollicis longus artery	+	+	+++	++
Vascularized scapula graft	14 cm	+++ Scapular flexor artery	+	+	+++	++
Vascularized rib graft	8 cm	+++ Thoracodorsal artery	+	+	+++	+++
Vascularized medial condyle of the femur graft	11 cm	+++ Descending genicular artery	+	+	+++	++
Vascularized lateral condyle of the femur graft	13 cm	+++ Lateral genicular artery	+	+	+++	++
Vascularized proximal part of the radius graft	6 cm	+++ Radial artery	+	+	+++	++

The use of vascularized free medial femoral condyle (VFMC) grafts is recommended for the treatment of small defects. However, there are relative contraindications to this procedure, including conditions such as diabetes mellitus, immunosuppression, chronic infections, alcohol and tobacco consumption, substance abuse, and obesity, which apply to all types of autografts [15].

Alloplasty

The use of allografts for bone defect reconstruction remains relevant. Rupp M., Klute L., Baertl S., Walter N., Mannala G. K. Frank, L., Pfeifer C., Alt V., Kerschbaum M. analyzed 1,090,167 surgical interventions over a period of 10 years and reached the conclusion that, in relative terms, the proportion of allografts increased by 7.2 %, and the overall growth was 74.1 %. This method ranks second among the techniques for bone defect replacement [16].

Bone allografts offer expanded and adaptable options for replacing and restoring damaged bone structures across diverse patient cohorts. Notably, Ahmed N., Eras V. and their colleagues exemplify the successful utilization of such materials in surgical interventions for patients presenting with bone defects of traumatic, infectious, and oncological etiologies, thereby underscoring their proven safety and efficacy [17].

Depending on their structure, allografts can be classified into three main categories: structural allografts, non-structural partial allografts, and demineralized bone matrix (DBM). Structural allografts can be used as intact elements to replace volumetric bone defects or as preserved structural fragments [18].

The appropriateness of using various types of allografts depending on clinical needs, based on the analysis of the literature sources mentioned above, is presented in Table 2.

Biocomposite materials

Currently, there is a sufficient variety of materials being used. The most commonly used materials have been selected for analysis.

Hydroxyapatite (HA) is a significant material for bone tissue regeneration. Research demonstrates that HA possesses high osteoconductive and osteointegrative activity, promoting rapid consolidation of bone fragments. Positive characteristics of the material include its biocompatibility with patient tissues and its propensity for osteointegration [19].

Calcium sulfate (CS) is one of the potential substitutes for bone transplants. According to the studies conducted by Lobb, DeGeorge, and Chhabra, CS possesses a well-understood chemical composition and properties. Its clinical versatility is evident in the form of blocks, granules, or injectable materials, making it suitable for various types of bone tissue defects. CS exhibits resistance to compression but has low tensile strength. An important characteristic of this material is its volume change during solidification: initially, the volume of CS decreases, but as it solidifies, it increases, which is a crucial parameter in addressing specific clinical challenges. CS itself serves as an osteoconductive material [20].

Tricalcium phosphate (TCP) is widely used as an effective synthetic bone graft substitute and bioactive material that can interact with tissues, promoting their regeneration. TCP exhibits good biocompatibility and the ability to produce calcium and phosphate, facilitating its integration with bone tissue. Studies by Bohner M., Santoni B. L. G., Dobelin N. have demonstrated that TCP can be synthesized in various forms, including porous ceramic materials and granules, enabling its use in different clinical scenarios. The material's porosity and morphological characteristics determine its degradation and resorption in the body. TCP possesses both osteoconductive and osteoinductive properties, facilitating complete restoration of bone defects.

Beta-tricalcium phosphate (b-TCP) is a synthetically derived inorganic compound that contains two minerals present in bone, minimizing the risk of disease transmission and offering relatively low production costs. In terms of characteristics, it occupies an

Table 2

Indications for the use of different types of allografts

Type of allograft	Indications	Contraindications
Structural	Diaphyseal defects, providing load-bearing function	Metaphyseal defects, pseudarthrosis, subchondral/chondral defects
Non-structural	Metaphyseal defects, pseudarthrosis	Diaphyseal defects, need for load-bearing function, subchondral/chondral defects
Osteochondral	Subchondral/chondral defects	Diaphyseal/metaphyseal defects, pseudarthrosis, need for load-bearing function
DBM (Demineralized Bone Matrix)	Metaphyseal and pseudarthrosis defects	Diaphyseal and subchondral/chondral defects, need for load-bearing function

intermediate position between the less absorbable hydroxyapatite (HA) and the rapidly absorbable calcium sulfate (CS) [21].

Polymethylmethacrylate (PMMA) is a rigid and transparent inert plastic that is used by mixing its components to form a paste, which then hardens. PMMA-based bone cement lacks osteogenic or osteoinductive properties, limiting its ability to promote bone tissue formation. Its use is only suitable as an osteoconductive material, where its porous structure can be utilized to support reparative processes and serve as a depot for antibiotics in an infected bone cavity [22].

Bioactive glass is an invention credited to the prominent American scientist Hench L. L. and the initially developed bioactive glass 45S5 is named after him [23].

Initially, the material was chemically inert and incapable of active tissue regeneration. The original bioactive glass had limitations in creating structures due to its composition, which caused crystallization and implant fracture, hindered the formation of a strong bond between bone and bioactive glass, and led to the formation of scar tissue around the implant. Further research revealed new possibilities for defect replacement and active regeneration by its ability to chemically bond with bone and promote the growth of new bone tissue. Ongoing developments continuously lead to new compositions of bioactive glass, and their properties can be altered by incorporating various elements (such as strontium, cobalt, copper, silver) into the glass composition [24].

Bone morphogenetic proteins (BMP) belong to the group of beta-transforming growth factors (TGF- β), which play a significant role in embryogenesis, organogenesis, proliferation, and differentiation of stem cells. Approximately 20 representatives of the BMP family have been identified, which can be categorized into several groups based on their structural similarity [25].

BMP (bone morphogenetic proteins) are natural proteins that play a crucial role, particularly in the development of the skeletal system. They are key factors that regulate bone balance by controlling the differentiation of osteoblasts and osteoclasts, indicating their stimulatory role in bone tissue. Additionally, BMPs influence the expression of genes related to osteogenesis and regulate bone remodeling processes. Specifically, BMP-2, BMP-4, BMP-7, and BMP-9 activate the Smad signaling pathway, promoting osteogenic differentiation of mesenchymal stem cells and bone formation. Evidence has shown that BMP-2 and BMP-7 have significant osteogenic func-

tion and can promote osteointegration. Therefore, the FDA has approved the use of recombinant human BMP-2 and BMP-7 for the treatment of certain orthopedic conditions, such as fractures and non-unions. RhBMP-2, in particular, is used for autologous bone grafting and the treatment of fractures with substantial loss of bone tissue. RhBMP-7 also plays a crucial role in bone regeneration and can aid in the healing of non-unions. The use of these recombinant BMPs has demonstrated improved outcomes compared to traditional treatment methods [26].

Currently, the most commonly used techniques for bone defect replacement are the Masquelet and Ilizarov methods.

The Masquelet technique is a relatively new two-stage approach to bone tissue loss recovery characterized by segmental bone defects caused by various factors (infections, non-plastic, traumatic). During the 1980s and 1990s, Masquelet primarily applied this technique to treat septic non-unions, involving the use of a cement spacer to prevent fibrous tissue growth in the intercalary space, providing mechanical stability, and combating infection. Additionally, the use of spacers as foreign material triggered an immune reaction, resulting in the formation of an autologous membrane that further supported the graft. A significant addition to the method is the utilization of a spacer made of polymethylmethacrylate (PMMA), which the author considers the most optimal [27].

The significance of the Masquelet concept lies in the specificity of tissue interaction and the bioactive membrane, highlighting their roles in the inflammatory response and tissue regeneration. The application of a combined and progressive approach, based on evidence-based methods, is of great importance for expanding the understanding of the Masquelet technique and adapting it to various fields of medicine [28].

The Ilizarov method (distraction osteogenesis) was first used in 1951 and involves the application of an external fixator, consisting of bone constructs (pins, rods, wires, screws) and a circular frame, which allows for the distraction of bone fragments and facilitates the formation of new bone tissue in the defect zone. The proposed technique and construction enable the formation of bone regenerate in the direction of bone growth and control the speed of distraction [29].

The main advantages of the Ilizarov method are as follows: the ability to stabilize and fixate bone fragments using the principles of extrafocal application, which promotes consolidation in a functionally

beneficial position; allowing for step-by-step correction based on individual clinical cases; preservation of joint functionality during consolidation, playing a crucial role in improving treatment outcomes and shortening rehabilitation periods.

Among the drawbacks, it is worth noting: the lengthy treatment period due to the presence of trans-tissue metal constructs, which entails a high risk of infection at the insertion sites, necessitating sufficient and prolonged aseptic and antiseptic measures; the method has its limitations concerning anatomical areas of application and requires highly skilled medical expertise to consider risk factors in each individual case; personal discomfort associated with using the device in daily life and its negative impact on the patient's psychological state [30].

The comparative characteristics of the Ilizarov and Masquelet methods are presented in Table 3.

The *Kapandji technique* was proposed in 1993 and received widespread recognition in the medical community. The idea of the method is in using a combination of a vascularized autograft and an allograft to achieve bone stability and its subsequent integration. The vascularized autograft provides the necessary blood supply for bone nourishment, while the al-

lograft is used to fill defects and create the required structural support.

The study conducted by Li et al. demonstrates the effectiveness of the Kapandji technique as a procedure for revision surgical correction after unsuccessful previous limb-saving surgeries. In 91.3 % of cases, bone fusion was achieved after the revision surgical correction. Improvement in functional outcomes was noted in the majority of patients, with no recurrences or complications during the average follow-up period of 41 months (range: 18–76 months) [31].

Discussion

The discussion regarding the choice of graft material, specifically autografts/allografts, is still going on. Modern researchers pay great attention to the donor site during autotransplantation.

Although the overall level of complaints after transplantation of the iliac crest is generally low, gait disturbances are the most common manifestation [32].

According to research by Katz M. S. et al., 74 out of 485 patients experienced gait disturbances in the early postoperative period (15.26 %), and only 11 patients (0.23 %) had chronic gait problems that lasted more than a month, especially in male patients. Hypoesthesia in the donor site area was found in 10 patients (2.06 %). Only five of them (1.03 %) had superficial sensory problems that lasted more than a month after surgery, and no difference between younger and older patients was detected [33].

However, Schaaf H. et al. indicate that 2.7 % of patients suffered from persistent sensory disorders [34].

Among the complications, delayed wound healing characterized 14 cases (2.89 %) painful scars — 6 cases (1.24 %), without a significant difference between age groups. Also, the authors noted the hematomas in 8.1 % and infectious complications in 12.8 %, which is explained by violations of surgical technique [35].

Severe complications, such as fractures of the anterior iliac crest and the hernias at the surgical access site occur in only 0.21–0.25 % of cases [36].

The research by Michael A Flierl et al. indicates that the cohort of autografts had a statistically significant shorter union time ((198 ± 172–225) days) compared to allografts ((416 ± 290–543) days), and tended towards earlier union, compared to the combination of allograft/autograft ((389 ± 159–619) days). Furthermore, the autograft cohort had the lowest level of surgical revisions (17 %) and revision bone grafting (9 %) compared to allografts (47 % and 32 %), and the combination of allograft/autograft (25 % and

Table 3

The comparative characteristics of the Ilizarov and Masquelet methods

Characteristic	Ilizarov method	Masquelet method
Osteogenesis	+++	+
Vascularization	++	+++
Limb stabilization	+	+
Deformity and length correction	++	–
Risk of rejection or necrosis	+	+/-
Soft tissue healing	+/-	–
Infection risk	–	+
Application in infected wounds	+	+++
Financial affordability	++	+
Possibility of weight-bearing on the limb	++	+
Need for bone grafting	++	–
Potential development of contractures	-/+	++
Requirement for repeat surgical corrections	–	+++
Staff qualification	–	++
Treatment duration	–	-/+
Impact on the patient's quality of life	–	+

Notes: «+++» — very high advantage; «++» — high advantage; «+» — moderate advantage; «+/-» — slight advantage; «-» — no advantage.

31 %). The overall level of postoperative infectious complications was significantly lower in the autograft group (12.4 %) compared to the allograft cohort (26.3 %) ($P < 0.05$) [37].

The vascularity of the autograft is one of the important parameters, as the presence of blood supply promotes the survival of the graft and its integration with the surrounding tissues. Free vascularized bone grafts are a more complex method used for the restoration of large bone defects since they include not only bone tissue but also the vessels that provide the necessary blood supply to the graft, requiring microsurgical techniques and specialized skills of the surgeon [38].

Feltri and Solaro (source) observe that the use of vascularized fibular grafts yields favorable functional outcomes, with a fusion rate of 80.1 % (confidence interval: 74.1–86.2 %) and a complication rate of 39.4 % (confidence interval: 34.4–44.4 %). The most common complications encountered were fractures, nonunions, delayed unions, infections, and thromboses. The morbidity at the donor site accounted for 10.7 % of the total complication rate, while the rate of reoperation was found to be 24.6 % (confidence interval: 21.0–28.1 %). This study underscores the significant advantages of utilizing vascularized bone grafts from the fibula, although it is crucial to consider the potential risks and complications associated with the procedure [39].

Despite the meticulous processing and sterilization of allografts, there always remains a potential risk of patient infection. In their study, Campanile, Hamidieh, et al. demonstrate that the overall rate of bacterial contamination in 19,805 bone allografts across 17 investigations was 12.6 % (95 % confidence interval 0.100, 0.152). The level of bacterial infection was reported to be 10.8 % until the year 2010, increasing to 14.7 % from January 2010 to March 2021 [40].

A promising approach to address this issue is the radiation sterilization of bone material using various exposure doses. However, research findings by Yusof N. et al. suggest that radiation sterilization at a dose of 25 kGy has a significant negative impact on the longevity of cortical bone during a prolonged fatigue cycle ($p = 0.001$). Samples irradiated at 25 kGy exhibited a reduced mean fatigue life (5.39 ± 0.32) compared to non-irradiated (6.20 ± 0.50), 10 kGy (6.35 ± 0.79), and 17.5 kGy (6.01) samples ($p = 0.001$). Furthermore, the samples irradiated at 25 kGy showed a more brittle fracture surface morphology than samples irradiated at 0 kGy, 10 kGy, and 17.5 kGy ($p = 0.04$) [41].

The research conducted by Tan Chern Yang et al. on the radiation sterilization of allografts under low-temperature conditions ($-40\text{ }^{\circ}\text{C}$ to $0\text{ }^{\circ}\text{C}$) demonstrated significantly lower values of mean compressive strength ((84 ± 27) MPa compared to (119 ± 31) MPa, $p = 0.005$) and viscosity ((3622 ± 1720) kJ/m³ compared to (5854 ± 2900) kJ/m³, $p = 0.009$) compared to samples irradiated at cooling temperatures below $-40\text{ }^{\circ}\text{C}$. This led to the conclusion that such a cooling range during gamma irradiation contributes to preserving the mechanical properties of cortical bone allografts [42].

The remodeling of allografts is an important issue. Enneking W. F., Campanacci D. A. established that the junction of the graft with the recipient's bone tissue occurs slowly (approximately twelve months) through the formation of a callus derived from the host, which overlapped the junction and filled the gaps between the adjoining cortical shells. The graft did not undergo load-oriented remodeling even after many years. The restoration of the graft matrix was both external and internal. External restoration involved the layering of the host bone onto the external surface of the graft, covering about 40 % of the surface within one year and 80 % within two years. Internal repair was limited to the ends and periphery, and penetrated so slowly that only 15–20 % of the graft was restored over five years, after which further repair occurred rarely [43].

Among modern researchers, significant attention is paid to bioactive glass. The development of manufacturing technologies, such as sol-gel processing, allows for the creation of bioactive glass with increased porosity and surface area. The advantages of these materials compared to widely used polymers and other compounds include non-toxicity, the absence of negative body reactions, and high bioactivity. Bioactive glass is also produced in various forms, from powders to 3D scaffolds. Since infection, especially in combat injuries, is a common companion of bone defects, further research to study the effectiveness of these biomaterials is quite appropriate [44].

The publications by Crush, Hussain, Seah, and Khan present a comprehensive evidence base regarding the high regenerative capacity of bioactive glass, particularly in combination with other materials, allowing for the modification of its properties to meet specific needs. In their research, the authors obtained structurally integral scaffolds that promote the growth of new bone, facilitating both osteo- and angiogenesis. With the use of bioactive glass, it is possible to achieve the delivery of antibiotics or growth factors, expanding its potential in tissue regeneration.

Further investigations focusing on the combination of bioactive glass with other materials and utilizing 3D printing to create optimized porosity and scaffold architecture offer the possibility of achieving better outcomes in the repair of bone defects [45].

A critical issue today is the comparative analysis of the outcomes of the Masquelet technique versus the Ilizarov method.

In his own work, Masquelet reports that the overall complication rate was 45%, among which fractures constituted about 13% [46].

Morelli I with other authors conducted a systematic study of the Masquelet technique involving 427 adults. The complications rate was high (49.6 %) across all studies, and the final union rate after revision surgeries was 89.7 %. In 18 % of patients, they observed failures (persistence of infection or non-union) with a subsequent need for further surgical intervention in 26.7 % [47].

Yin P. et al. conducted an analysis of the results of the Ilizarov method treatment for infected non-unions of the tibia and femur. In total, among 590 patients covering 24 studies, the average bone union rate was 97.26 %. The average size of the bone defect was 65–67 mm in patients with infected non-union of the tibia and 80 mm in patients with infected non-union of the femur. The rate of fractures was 4 %, malunion — 7 %, deep infection recurrence — 5 %, and knee joint stiffness — 12 %. The rate of superficial site infection at the pin insertion sites varied from 10 to 100 %, with an average external fixation time of 10.69 months and an average external fixation index of 1.70 months/cm [48].

Govind Kumar Gupta et al. present somewhat different comparative treatment outcomes. In the group of patients treated with the Ilizarov method, union was observed in 67 % of cases, consolidation requiring additional bone graft — 25 %, and delayed union — 8 %. In the group treated with the Masquelet method: union in 75%, and in 25 % — delayed consolidation. The bone transport technique showed excellent results in 58.3 % and good in 41.7 %, whereas the Masquelet technique showed excellent results in 50 % and good in 50 % [49].

According to Nando Ferreira, «if randomized studies do not compare these treatment methods, it is difficult to establish a clear advantage of any one method. However, after a thorough review of the literature, it seems that bone transport provides a more predictable outcome and should be preferred» [50].

Conclusions

The treatment of bone tissue defects of various genesis, including those of a gunshot origin, remains a relevant issue in modern orthopedics and traumatology. A wide range of treatment options proves that no single strategy works for every patient, nor does an ideal universal material exist for filling and ensuring bone regeneration at the defect site.

The problem lies not only/in so much in the size of the defect, but in an environment that impedes osteogenesis, and is characterized by the presence of pathogenic microflora, damage to soft tissues, and impaired vascularization. A promising direction is the search for new, or a combination of known materials and methods, capable of maximally compensating for these pathological conditions.

Conflict of interest. The authors declare no conflict of interest.

References

1. El-Rashdy, A. A., Roether, J. A., Harhaus, L., Kneser, U., & Boccaccini, A. R. (2017). Regenerating bone with bioactive glass scaffolds: A review of in vivo studies in bone defect models. *Acta Biomaterialia*, 62, 1-28. <https://doi.org/10.1016/j.actbio.2017.08.030>
2. Nauth, A., Schemitsch, E., Norris, B., Nollin, Z., & Watson, J. T. (2018). Critical-size bone defects: Is there a consensus for diagnosis and treatment? *Journal of Orthopaedic Trauma*, 32(3), S7-S11. <https://doi.org/10.1097/bot.0000000000001115>
3. Omar, M., Zeckey, C., Krettek, C., & Graulich, T. (2021). Offene Frakturen. *Der Unfallchirurg*, 124(8), 651-665. <https://doi.org/10.1007/s00113-021-01042-2>
4. Mathieu, L., Bilichtin, E., Durand, M., De l'Escalopier, N., Murison, J. C., Collombet, J., & Rigal, S. (2019). Masquelet technique for open tibia fractures in a military setting. *European Journal of Trauma and Emergency Surgery*, 46(5), 1099-1105. <https://doi.org/10.1007/s00068-019-01217-y>
5. Hoencamp, R., Vermetten, E., Tan, E. C., Putter, H., Leenen, L. P., & Hamming, J. F. (2014). Systematic review of the prevalence and characteristics of battle casualties from NATO coalition forces in Iraq and Afghanistan. *Injury*, 45(7), 1028-1034. <https://doi.org/10.1016/j.injury.2014.02.012>
6. Korol, S. (2021). Cyst plasty in the system of specialized treatment of wounded ends due to combat injuries. *TRAUMA*, 19(1), 20-26. <https://doi.org/10.22141/1608-1706.1.19.2018.126659>. (in Ukrainian)
7. Burianov, O., Yarmoliuk, Y., Derkach, S., Gritsai, M., Klapchuk, Y., Los, D., Omelchenko, T., & Kolov, G. (2023). Criteria for predicting risks in the case of replacing an external fixator with an internal fixator during the treatment of gunshot fractures of the extremities. *ORTHOPAEDICS, TRAUMATOLOGY and PROSTHETICS*, (1), 5-9. <https://doi.org/10.15674/0030-5987202315-9>
8. Shores, J., Brandacher, G., & Lee, W. (2018). From auto- to Allotransplantation: Immunomodulatory protocol for hand and arm transplantation. *Journal of Reconstructive Microsurgery*, 34(09), 683-684. <https://doi.org/10.1055/s-0038-1651524>
9. Villarreal-Villarreal, G. A., Simental-Mendía, M., Alonso, A. A., Vilchez-Cavazos, F., Acosta-Olivo, C. A., & Peña-Martínez, V. M. (2023). Comparison of anterior iliac crest versus proximal tibia autologous bone Graft harvesting: A systematic review and meta-analysis. *The Journal of Foot and Ankle Surgery*, 62(2),

- 388-397. <https://doi.org/10.1053/j.jfas.2022.10.004>
10. Wang, Z., Zhu, Y., Deng, X., Xin Xing, Tian, S., Fu, L., Yan, X., Chen, W., Hou, Z., & Zhang, Y. (2021). Structural Bicortical autologous iliac crest bone Graft combined with the tunnel bone tamping method for the depressed tibial plateau fractures. *BioMed Research International*, 2021, 1-10. <https://doi.org/10.1155/2021/1249734>
 11. Tow, A. P. (2022). Autotransplantation: a lost art worthy of revival in the era of implants. *General dentistry*, 70(4), 28-32. <https://doi.org/10.56569/UDJ.1.1.2022.5-19>
 12. Petrella, G., Tosi, D., Pantaleoni, F., & Adani, R. (2021). Vascularized bone grafts for post-traumatic defects in the upper extremity. *Archives of Plastic Surgery*, 48(01), 84-90. <https://doi.org/10.5999/aps.2020.00969>
 13. Shi, L. L., Garg, R., Jawa, A., Wang, Q., Chai, Y., Zeng, B., & Jupiter, J. B. (2020). BONY hypertrophy in vascularized fibular grafts. *HAND*, 17(1), 106-113. <https://doi.org/10.1177/1558944719895784>
 14. Boghossian, E., & Stewart, D. A. (2021). The medial Metaphyseal periosteal artery (MMPA): An alternate pedicle for the medial femoral trochlea flap. *The Journal of Hand Surgery*, 46(11), 1032.e1-1032.e3. <https://doi.org/10.1016/j.jhsa.2020.11.012>
 15. Hill, J. R., Heckmann, N., McKnight, B., White, E. A., Ghias, A., & Patel, B. A. (2020). Medial femoral trochlea Osteochondral Graft: A quantitative anatomic comparison to the proximal pole of the scaphoid. *Journal of Wrist Surgery*, 09(04), 283-288. <https://doi.org/10.1055/s-0040-1708862>
 16. Rupp, M., Klute, L., Baertl, S., Walter, N., Mannala, G., Frank, L., Pfeifer, C., Alt, V., & Kerschbaum, M. (2021). The clinical use of bone Graft substitutes in orthopedic surgery in Germany — A 10-years survey from 2008 to 2018 of 1,090,167 surgical interventions. *Journal of Biomedical Materials Research Part B: Applied Biomaterials*, 110(2), 350-357. <https://doi.org/10.1002/jbm.b.34911>
 17. Ahmed, N., Eras, V., Pruß, A., Perka, C., Brune, J., & Vuhhan, T. (2022). Allografts: Expanding the surgeon's armamentarium. *Cell and Tissue Banking*, 24(1), 273-283. <https://doi.org/10.1007/s10561-022-10015-7>
 18. Aurich, M., & Hofmann, G. O. (2020). Fixation of displaced avulsion fracture of the anterior superior iliac spine (ASIS) after bone Graft harvesting using anatomic low-profile locking plate: Case report and surgical technique. *Zeitschrift für Orthopädie und Unfallchirurgie*, 159(06), 681-686. <https://doi.org/10.1055/a-1192-7544>
 19. Ielo, I., Calabrese, G., De Luca, G., & Conoci, S. (2022). Recent advances in hydroxyapatite-based Biocomposites for bone tissue regeneration in orthopedics. *International Journal of Molecular Sciences*, 23(17), 9721. <https://doi.org/10.3390/ijms23179721>
 20. Lobb, D. C., DeGeorge, B. R., & Chhabra, A. B. (2019). Bone Graft substitutes: Current concepts and future expectations. *The Journal of Hand Surgery*, 44(6), 497-505.e2. <https://doi.org/10.1016/j.jhsa.2018.10.032>
 21. Bohner, M., Santoni, B. L., & Döbelin, N. (2020). β -tricalcium phosphate for bone substitution: Synthesis and properties. *Acta Biomaterialia*, 113, 23-41. <https://doi.org/10.1016/j.actbio.2020.06.022>
 22. Kim, S., Baril, C., Rudraraju, S., & Ploeg, H. (2021). Influence of porosity on fracture toughness and fracture behavior of antibiotic-loaded PMMA bone cement. *Journal of Biomechanical Engineering*, 144(1). <https://doi.org/10.1115/1.4051848>
 23. Hench, L. L. (2013). Chronology of Bioactive glass development and clinical applications. *New Journal of Glass and Ceramics*, 03(02), 67-73. <https://doi.org/10.4236/njgc.2013.32011>
 24. Kargozar, S., Montazerian, M., Fiume, E., & Baino, F. (2019). Multiple and promising applications of strontium (sr)-containing Bioactive glasses in bone tissue engineering. *Frontiers in Bioengineering and Biotechnology*, 7. <https://doi.org/10.3389/fbioe.2019.00161>
 25. Ayoub, A., & Gillgrass, T. (2019). The clinical application of recombinant human bone morphogenetic protein 7 for reconstruction of alveolar cleft: 10 years' follow-up. *Journal of Oral and Maxillofacial Surgery*, 77(3), 571-581. <https://doi.org/10.1016/j.joms.2018.08.031>
 26. Bai, Y., Moeinzadeh, S., Kim, S., Park, Y., Lui, E., Tan, H., Zhao, W., Zhou, X., & Yang, Y. P. (2020). Development of PL-GA-PEG-COOH and gelatin-based Microparticles dual delivery system and E-beam sterilization effects for controlled release of BMP-2 and IGF-1. *Particle & Particle Systems Characterization*, 37(10). <https://doi.org/10.1002/ppsc.202000180>
 27. Issaoui, H., Fekhaoui, M. R., Jamous, M., & Masquelet, A. (2021). Modified Masquelet technique using Allogeneic Graft for a Gustilo-Anderson type III-A open fracture of the femur with an 8 cm bone defect. *Case Reports in Orthopedics*, 2021, 1-7. <https://doi.org/10.1155/2021/8829158>
 28. Masquelet, A. C., & Giannoudis, P. V. (2021). The induced membrane technique for treatment of bone defects: What have I learned? *Trauma Case Reports*, 36, 100556. <https://doi.org/10.1016/j.tcr.2021.100556>
 29. Tetsworth, K., Paley, D., Sen, C., Jaffe, M., Maar, D. C., Glatt, V., Hohmann, E., & Herzenberg, J. E. (2017). Bone transport versus acute shortening for the management of infected tibial non-unions with bone defects. *Injury*, 48(10), 2276-2284. <https://doi.org/10.1016/j.injury.2017.07.018>
 30. Liu, Y., Yushan, M., Liu, Z., Liu, J., Ma, C., & Yusufu, A. (2020). Complications of bone transport technique using the Ilizarov method in the lower extremity: A retrospective analysis of 282 consecutive cases over 10 years. *BMC Musculoskeletal Disorders*, 21(1). <https://doi.org/10.1186/s12891-020-03335-w>
 31. Li, M., Xiao, X., Fan, J., Lu, Y., Chen, G., Huang, M., Ji, C., Wang, Z., & Li, J. (2021). Is the Capanna technique a reliable method for revision surgery after failure of previous limb-salvage surgery? *Annals of Surgical Oncology*, 29(2), 1122-1129. <https://doi.org/10.1245/s10434-021-10506-z>
 32. Boehm, K. S., Al-Taha, M., Morzycki, A., Samargandi, O. A., Al-Youha, S., & LeBlanc, M. R. (2018). Donor site morbidities of iliac crest bone Graft in Craniofacial surgery. *Annals of Plastic Surgery*, 83(3), 352-358. <https://doi.org/10.1097/sap.0000000000001682>
 33. Katz, M. S., Ooms, M., Heitzer, M., Peters, F., Winnand, P., Kniha, K., Möhlhenrich, S. C., Hölzle, F., Knobe, M., & Modabber, A. (2021). Postoperative morbidity and complications in elderly patients after harvesting of iliac crest bone grafts. *Medicina*, 57(8), 759. <https://doi.org/10.3390/medicina57080759>
 34. Schaaf, H., Lendeckel, S., Howaldt, H., & Streckbein, P. (2010). Donor site morbidity after bone harvesting from the anterior iliac crest. *Oral Surgery, Oral Medicine, Oral Pathology, Oral Radiology, and Endodontology*, 109(1), 52-58. <https://doi.org/10.1016/j.tripleo.2009.08.023>
 35. Tosun, E., Akkocaoglu, M., Tüz, H. H., Avağ, C., & Gokturk, T. (2019). Complications associated with anterior iliac bone grafting for the reconstruction of Dentoalveolar defects. *Journal of Craniofacial Surgery*, 30(4), 980-984. <https://doi.org/10.1097/scs.0000000000005331>
 36. Gawhale, S. K., Kantharaju, H., Prasanna Kumar, G. S. & Shah, N. (2020). Incisional Hernia Secondary to Iliac Crest Bone Graft: A Rare Case Report and Review of Literature. *J. Orthop. Case Rep.*, 10, 15-17. <https://doi.org/10.13107/jocr.2020.v10.i07.1898>
 37. Flierl, M. A., Smith, W. R., Mauffrey, C., Irgit, K., Williams, A. E., Ross, E., Peacher, G., Hak, D. J., & Stahel, P. F. (2013). Outcomes and complication rates of different bone grafting modalities in long bone fracture nonunions: A retrospective cohort study in 182 patients. *Journal of Orthopaedic Surgery and Research*, 8(1). <https://doi.org/10.1186/1749-799x-8-33>
 38. Petrella, G., Tosi, D., Pantaleoni, F., & Adani, R. (2021).

- Vascularized bone grafts for post-traumatic defects in the upper extremity. *Archives of Plastic Surgery*, 48(01), 84-90. <https://doi.org/10.5999/aps.2020.00969>
39. Feltri, P., Solaro, L., Errani, C., Schiavon, G., Candrian, C., & Filardo, G. (2021). Vascularized fibular grafts for the treatment of long bone defects: Pros and cons. A systematic review and meta-analysis. *Archives of Orthopaedic and Trauma Surgery*, 143(1), 29-48. <https://doi.org/10.1007/s00402-021-03962-5>
 40. Baseri, N., Meysamic, A., Campanile, F., Hamidieh, A., & Jafarian, A. (2022). Bacterial contamination of bone allografts in the tissue banks: A systematic review and meta-analysis. *Journal of Hospital Infection*, 123, 156-173. <https://doi.org/10.1016/j.jhin.2021.10.020>
 41. Yusof, N. (2017). Advances of radiation sterilisation in tissue banking. *Cell and Tissue Banking*, 19(2), 175-186. <https://doi.org/10.1007/s10561-017-9651-4>
 42. Yang Harmony, T. C., Yusof, N., Ramalingam, S., Baharin, R., Syahrom, A., & Mansor, A. (2021). Deep-freezing temperatures during irradiation preserves the compressive strength of human cortical bone allografts: A cadaver study. *Clinical Orthopaedics & Related Research*, 480(2), 407-418. <https://doi.org/10.1097/corr.0000000000001968>
 43. Enneking, W. F., & Campanacci, D. A. (2001). Retrieved human allografts. *The Journal of Bone and Joint Surgery-American Volume*, 83(7), 971-986. <https://doi.org/10.2106/00004623-200107000-00001>
 44. Kargozar, S., Mozafari, M., Ghodrati, S., Fiume, E., & Baino, F. (2021). Copper-containing bioactive glasses and glass-ceramics: From tissue regeneration to cancer therapeutic strategies. *Materials Science and Engineering: C*, 121, 111741. <https://doi.org/10.1016/j.msec.2020.111741>
 45. Crush, J., Hussain, A., Seah, K. T., & Khan, W. S. (2021). Bioactive glass: Methods for assessing angiogenesis and osteogenesis. *Frontiers in Cell and Developmental Biology*, 9. <https://doi.org/10.3389/fcell.2021.643781>
 46. Masquelet, A. C., Fitoussi, F., Begue, T., & Muller, G. P. (2000). Reconstruction of the long bones by the induced membrane and spongy autograft. *Ann Chir Plast Esthet.*, 45(3), 346-353. PMID: 10929461
 47. Morelli, I., Drago, L., George, D. A., Gallazzi, E., Scarponi, S., & Romano, C. L. (2016). Masquelet technique: Myth or reality? A systematic review and meta-analysis. *Injury*, 47, S68-S76. [https://doi.org/10.1016/s0020-1383\(16\)30842-7](https://doi.org/10.1016/s0020-1383(16)30842-7)
 48. Yin, P., Ji, Q., Li, T., Li, J., Li, Z., Liu, J., Wang, G., Wang, S., Zhang, L., Mao, Z., & Tang, P. (2015). A systematic review and meta-analysis of Ilizarov methods in the treatment of infected Nonunion of tibia and femur. *PLOS ONE*, 10(11), e0141973. <https://doi.org/10.1371/journal.pone.0141973>
 49. Shekhar, S., Gupta, G., Majhee, A., Rani, S., Prasad, P., & Chauhan, G. (2022). A comparative study between bone transport technique using Ilizarov/LRS fixator and induced membrane (Masquelet) technique in management of bone defects in the long bones of lower limb. *Journal of Family Medicine and Primary Care*, 11(7), 3660. https://doi.org/10.4103/jfmpc.jfmpc_2447_21
 50. Ferreira, N., & Tanwar, Y. S. (2020). Systematic approach to the management of post-traumatic segmental Diaphyseal long bone defects: Treatment algorithm and comprehensive classification system. *Strategies in Trauma and Limb Reconstruction*, 15(2), 106-116. <https://doi.org/10.5005/jp-journals-10080-1466>

The article has been sent to the editors 03.11.2023

СУЧАСНІ ТЕХНОЛОГІЇ ЗАМІЩЕННЯ КІСТКОВИХ ДЕФЕКТІВ (ОГЛЯД ЛІТЕРАТУРИ)

О. А. Бур'янов¹, В. П. Кваша¹, В. О. Купрій²,
Ю. Л. Соболевський¹, В. С. Чорний¹, Г. Г. Гліба¹, В. О. Рогозинський³

¹ Національний медичний університет імені О. О. Богомольця, Київ, Україна

² Центр інноваційних медичних технологій НАН України, Київ

³ Національний військово-медичний клінічний центр «Головний військовий клінічний госпіталь», Київ, Україна

✉ Oleksandr Buryanov, MD, Prof. in Traumatology and Orthopaedics: kaftraum@ukr.net

✉ Volodymyr Kvasha, MD, Prof. in Traumatology and Orthopaedics: vlkvasha@ukr.net

✉ Valentyn Kuprii, MD: drkuprii@gmail.com

✉ Yuriy Sobolevskiy, MD, PhD: soburik@icloud.com

✉ Volodymyr Chornyi, MD, PhD: oncoortoped@gmail.com

✉ Heorrhii Hliba: gliba.georgiy@gmail.com

✉ Valentyn Rohozynskiy, MD, PhD: v.rogozinskiy.v@gmail.com