

КОРОТКІ ПОВІДОМЛЕННЯ ТА НОТАТКИ З ПРАКТИКИ

УДК 617.547:616.711-001.36]-089.8-072.1](045)=111

DOI: <http://dx.doi.org/10.15674/0030-59872024149-52>

Lumbar Discectomy with Canal Decompression by Destandau Endospine system

Santosh Kumar Sahu¹, Dattatreya Kar²¹ Department of Orthopaedic, IMS & SUM Hospital, Siksha 'O' Anusandhan (Deemed to be University), Bhubaneswar, India² Department of Medical Research, IMS & SUM Hospital, Siksha 'O' Anusandhan (Deemed to be University), Bhubaneswar, India

Lumbar disc herniation is a common disease. There is severe pain in the buttock and leg, which may persist for more than 6 weeks even after conservative treatment. Currently, there are several surgical techniques for the treatment of lumbar disc herniation, ranging from laminectomy to microdiscectomy. The main advantages of endoscopic discectomy include: cosmetic appeal, minimally invasive nature, better visualization, shorter hospital stay and faster recovery. Objective. This article reviews discusses the management of patients with degenerative diseases of the lumbar spine by Destandau Endospine system. The authors shares his experience of the surgical technique and the results of percutaneous endoscopic discectomy using the Destandau system during the treatment of 51 patients with herniated disc and canal stenosis in the lumbar spine. The main advantages of the Destandau endoscopic system are a small skin incision and minimal damage to soft tissues. This is a minimally invasive intervention, which is applied through a skin incision 1.5–2 cm long. In order to ensure the accuracy and safety of the patient both before and during the operation, fluoroscopy is used. Under the control of an endoscope, the herniated intervertebral disc, free fragments of the disc are removed and the pinched nerve is released. Thus, rapid recovery is achieved during postoperative rehabilitation. Conclusions. The endoscopic system can be used to treat all types of intervertebral disc herniations and associated canal stenosis. It is a relatively safe procedure, provided proper preoperative planning and an experienced team of doctors. Most lumbar pathologies that are not related to instability can be successfully resolved with its help. The two main advantages of the Destandau endospinal system include minimally invasive surgery with minimal iatrogenic damage and excellent efficacy. In the case of its successful application, the recovery process is significantly shortened, without any restrictions for returning to everyday life.

Грижа міжхребцевого диска попереку є поширеним захворюванням. Виникає сильний біль у ділянці сідниці та в нозі, який зникає протягом 6 тижнів за умов консервативного лікування. Наразі існує декілька хірургічних методик лікування гриж поперекового диска, починаючи від ламінектомії до мікродискектомії. Основні переваги ендоскопічної дискектомії включають: косметичну привабливість, мінімально інвазивний характер, кращу візуалізацію, менший термін госпіталізації та більш швидке одужання. Мета. Розглянуто спостереження за пацієнтами з дегенеративними захворюваннями поперекового відділу хребта за допомогою системи Дестандау. Автори діляться досвідом техніки хірургічного втручання та результатами черезшкірної ендоскопічної дискектомії за системою Дестандау під час лікування 51 пацієнта з грижею диска та стенозом каналу поперекового відділу хребта. Основні переваги ендоскопічної системи Дестандау — це невеликий розріз шкіри та мінімальне ушкодження м'яких тканин. Це малоінвазивне втручання, яке застосовують через розріз шкіри 1,5–2 см завдовжки. Із метою забезпечення точності й безпеки пацієнта як перед операцією, так під час неї застосовується рентгенівське обладнання. Під контролем ендоскопа видаляють грижу міжхребцевого диска, вільні фрагменти диска та звільняють затиснений нерв. Таким чином досягають швидкого відновлення під час післяопераційної реабілітації. Висновки. Ендоскопічна система може бути використаною для лікування всіх видів гриж міжхребцевих дисків і супутнього стенозу каналу. Це відносно безпечна процедура за умови правильного передопераційного планування та досвідченої команди лікарів. Більшість поперекових патологій, які є не пов'язані з нестабільністю, можуть бути успішно вирішені за її допомогою. Дві основні переваги ендоспинальної системи Дестандау включають малоінвазивну хірургію з мінімальним ятрогенним ушкодженням і відмінній ефективності. У разі її успішного застосування, процес відновлення значно скорочується, без будь-яких обмежень для повернення до повсякденного життя. Ключові слова. Дестандау, ендоскопія, хребет, поперековий відділ.

Keywords. Destandau, Endoscopic spine system, Lumbar, Discectomy, Decompression

Introduction

Lumbar prolapsed intervertebral disc prolapse is a very common problem. Nearly 4–33 % of the population suffer from low back pain at some point in their life time and 10 % of all lumbar disc prolapse patients equip surgery [1, 2]. Mostly pain due to lumbar disc disease resolves over a period of 6 weeks with conservative management. Whereas patients with severe pain and associated neurological deficit that are not relieved with conservative management are candidates for surgery. Although several surgical techniques are available for lumbar disc herniation ranging from laminectomy to micro discectomy, major advantages of endoscopic discectomy includes, its cosmetic appeal, minimally invasive nature, better visualization as a result of improved magnification and illumination and speedy recovery [3]. In 1934, Mixter and Barr first described the surgical procedure for lumbar discectomy [4]. Mayer and Brock in 1993 described the surgical technique and preliminary results of percutaneous endoscopic discectomy: surgical technique and preliminary results of percutaneous endoscopic discectomy compared to microsurgical discectomy [5]. Foley and Smith described endoscopic discectomy techniques in 1997 [6]. The major advantages of Destandau Endospine System, includes, small skin incision and minimal soft tissue injury. With the Destandau Endospine System, deeply located pathology in the lumbar spine, can be easily addressed. Apart from its cosmetic appeal due to small incision, it also reduces the soft tissue injury, thus aid in rapid recovery during post-operative rehabilitation. Endospine System can be used to address all kinds of lumbar disc herniations and associated canal stenosis [7, 8].

Technical Note

We prefer knee-chest position, which allows the abdomen to be completely lax while allowing adequate interspinous distraction, which is very im-

portant, while dealing with patients of spinal canal stenosis. A specialized pillow is placed below the patient's chest, which allows the head to lie lower than the remaining body parts, thus aiding in venous return, which in turn minimizes venous bleeding (Fig. c) [9]. Localization of disc space is done in lateral fluoroscopy with help of a metallic tool provided in the Destandau Endospine System. The entry point is marked with a skin marker to determine the correct disc space. (Fig. d, e) [10]. 15-20 mm skin incision is made — 10 mm from the midline spinous process (Fig. f). The fascia is incised in the same direction with the help of Mayo's scissors, and the paravertebral muscles are elevated from the spinous process and superior lamina with the help of a 12-mm periosteal elevator provided in the set. Bleeding from the separated muscles is controlled with bipolar cautery. Next two gauze pieces with thread, one of them is placed cranially and the other one is placed caudally to retract the paraspinal muscles laterally. Once the inter laminar window is exposed, the outer sheath of the Endospine system is placed snugly in the plane developed between spinous process and the elevated paraspinal muscles thus exposing the interlaminar window, with the lamina in the cranial half and the yellow ligament in the caudal half (Fig. g). Then the inner tube locked into the outer tube with the help of in-built lock. Next the endoscope is fixed into the 4mm endoscope channel and suction tube is kept into another parallelly placed 4mm channel (Fig. h). But the 12 mm working portal is placed at an angle of 12° to the two 4-mm channels, to avoid intermingling of the instruments. To start with excision of the lamina, begins at the spino-laminar junction with the help of a 450 Rongeur to detach the yellow ligament from the lamina. Then a neuropattie was used to push the dura anteriorly, to avoid accidental dural injury. Next, the yellow ligament is detached from the caudal lamina and the medial facet in order to decompress the traversing nerve root and neuropatties were pushed cranially and laterally to decompress the shoulder of the nerve root and provides a bloodless field. Then with the help of a 45° Kerrison Rongeur, the SAP (superior articular process) is undercut to decompress the exiting root. Then the nerve root is retracted medially to expose the disc space. Next, epidural veins over the exposed disc space is cauterized with RFA (radio frequency ablator). With an annulotome the annulus is opened and adequate discectomy is performed. Sometimes on retraction of nerve root, extruded disc fragments can be easily visualized in such scenarios sequestrectomy was done. The disk space is thoroughly irrigated with normal

Table

Patients Demography

Age (years)	27–63
Gender (Male : Female)	36 : 15
BMI	27.56 ± 4.12
Pre-op VAS	7.7 ± 2.27
Duration of surgery (in minutes)	110.54 ± 25.65
Hospital Stay (days)	2 ± 0
L _V –S _I level (no.of cases)	30
L _{IV} –L _V level (no.of cases)	15
Both L _V –S _I & L _{IV} –L _V (no.of cases)	9

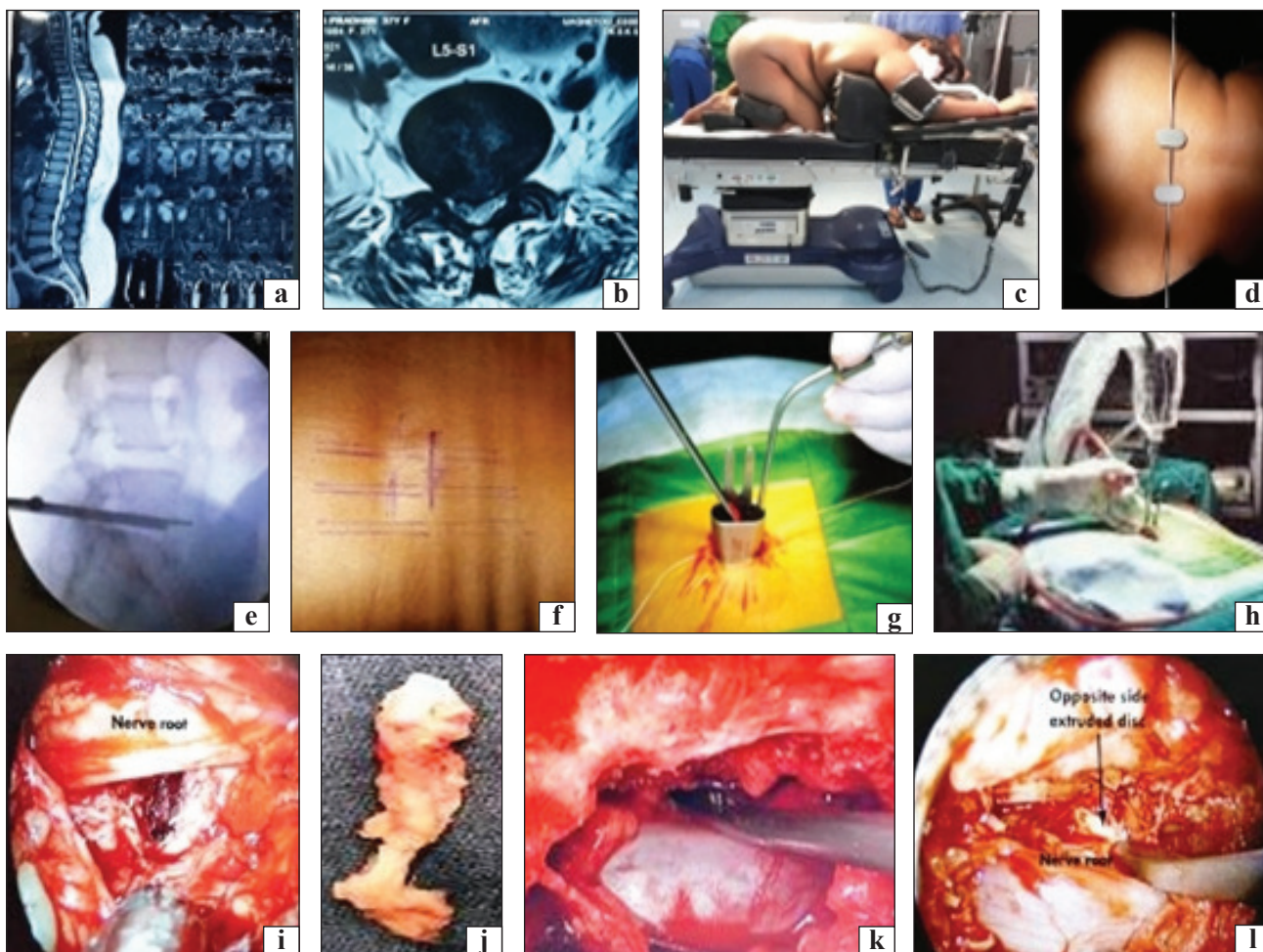


Figure. Surgical Steps

saline to get rid of the loose fragments (Fig. i). Then the entire Endoscope assembly is angulated to the opposite side. Next the base of the spinous process is undercut with a Kerrison Rongeur, following which the opposite lamina is undercut with Kerrison Rongeur, while keeping the yellow ligament intact to avoid accidental injury to dura (Fig. k). Then the opposite lamina is undercut to remove the yellow ligament cranially from the opposite lamina, followed by detachment of caudal ligament from the opposite caudal lamina. Then the SAP (superior articular process) of the opposite side is undercut with the help of Kerrison Rongeur. The Destandau's Endospine system was withdrawn as a single unit, once the opposite side nerve root and lateral edge of dura were satisfactorily decompressed and hemostasis is achieved with bipolar cautery for muscles and bone wax was used to control osseous bleeding. Wound was closed in layers, without a drain, with 2-0 Vicryl for the fascial layer and 3-0 Vicryl was used for subcuticular closure. Most of the stable patients were mobilized

6hrs following surgery, without any support and all such patients were discharged after 24 hours.

Our Experience

At a tertiary care hospital of Bhubaneswar India between 2018 and 2020, 51 cases of lumbar disc herniations with or without spinal canal stenosis at one or two levels were managed with Destandau's endoscopic technique. All the surgeries were done by the author. MRI was done in all cases. In all 51 cases, were operated under general anesthesia in knee-chest position. The most common levels encountered were L_V-S_1 followed by $L_{IV}-L_V$. Out of 15 cases with $L_{IV}-L_V$ level pathology, discectomy was done in 6, discectomy with decompression was done in 6 cases, and decompression without discectomy was done in 3 cases. Out of 30 cases with L_V-S_1 pathology, discectomy was done in 9 cases, discectomy with decompression in 18 cases, and decompression without discectomy was performed in 3 cases. 9 patients had both $L_{IV}-L_V$ and L_V-S_1 involvement, which was addressed in same sitting. 6 patients had pathology involving $L_{III}-L_{IV}$ level,

of which 3 had only discectomy, 3 needed discectomy with canal decompression. Two cases had facet joint cysts, which was putting pressure over the nerve root, both were at L_{III}–L_{IV}. Thorough decompression and debridement of the cysts were done, under endoscopic guidance. In our series, the author had 3 incidences of dural punctures and all the 3 cases, were managed by packing with small Gel foamed pieces. The author had excellent results in 96 % of cases using modified McNab's criteria for evaluation, good result in 3 % and fair result in 1 % of the cases [10].

Discussion

Conventional open discectomy surgery involves excision of a larger portion of posterior bony and soft tissue elements to expose the thecal sac and the nerve root and to get rid of the pathological disc. Many a times integrity of facet joint is compromised while navigating laterally, resulting in instability at the corresponding level, which in turn warrants interbody fusion. Apart from its cosmetic appeal due to small incision, endospine system also reduces the soft tissue injury, thus aid in rapid recovery during postoperative rehabilitation. Several endoscopic discectomy techniques have been described in literature. Dr. Jean Destandau from France has designed his own endospine system for the minimally invasive endoscopic surgery. The major advantages of Destandau endospine system includes cosmetic appeal because of small incision, minimally invasive, minimal soft tissue damage, minimal blood loss, reduced risk of nerve injury because to excellent magnification & illumination, reduced risk of infection, less postoperative morbidity, short hospital stay. Apart from this, the technique is easy to adapt, once the initial learning curve is safely negotiated. This approach can easily be converted to open discectomy if necessity arises. Multiple level discs can be addressed through the same incision by adjusting the inclination of operating tube. Last but not the least, the Destandau endospine system includes simple and affordable instruments.

Conclusions

Destandau's Endoscopic spine system is a relatively safe procedure, once the initial learning curve is safely negotiated, and various lumbar pathologies, which are not associated with instability, can be successfully addressed with favorable results in good hands. The two major advantages of Destandau's endospine system includes, minimally invasive surgery with minimal iatrogenic injury and excellent efficiency, because of which patient recovery is shortened, without any restriction to return to professional life.

Conflict of interest. The authors declare no conflict of interest.

References

1. Woolf, A. D., & Pfleger, B. (2003). Burden of osteoporosis and fractures in developing countries. *Current Osteoporosis Reports*, 81(9), 646–656.
2. Ozer, A. F., Keskin, F., Oktenoglu, T., Suzer, T., Ataker, Y., Gomleksiz, C., & Sasani, M. (2013). A Novel Approach to the Surgical Treatment of Lumbar Disc Herniations: Indications of Simple Discectomy and Posterior Transpedicular Dynamic Stabilization Based on Carragee Classification. *Advances in Orthopedics*, 2013, 1–6. <https://doi.org/10.1155/2013/270565>
3. Kaushal, M., & Sen, R. (2012). Posterior endoscopic discectomy: Results in 300 patients. *Indian Journal of Orthopaedics*, 46(1), 81. <https://doi.org/10.4103/0019-5413.91640>
4. Mixter, W. J., & Barr, J. S. (1934). Rupture of the Intervertebral Disc with Involvement of the Spinal Canal. *New England Journal of Medicine*, 211(5), 210–215. <https://doi.org/10.1056/nejm193408022110506>
5. Mayer, H. M., & Brock, M. (1993). Percutaneous endoscopic discectomy: surgical technique and preliminary results compared to microsurgical discectomy. *Journal of Neurosurgery*, 78(2), 216–225. <https://doi.org/10.3171/jns.1993.78.2.0216>
6. Foley, K. T., Smith, M. M., & Rampersaud, Y. R. (1999). Microendoscopic approach to far-lateral lumbar disc herniation. *Neurosurgical Focus*, 7(5), E7. <https://doi.org/10.3171/foc.1999.7.5.8>
7. Isaacs, R. E., Podichetty, V., & Fessler, R. G. (2003). Microendoscopic discectomy for recurrent disc herniations. *Neurosurgical Focus*, 15(3), 1–4. <https://doi.org/10.3171/foc.2003.15.3.11>
8. Maroon, J. C. (2002). Current Concepts in Minimally Invasive Discectomy. *Neurosurgery*, 51(suppl_2), S2-137–S2-145. <https://doi.org/10.1097/00006123-200211002-00019>
9. Park, C. K. (2000). The Effect of Patient Positioning on Intraabdominal Pressure and Blood Loss in Spinal Surgery. *Anesthesia & Analgesia*, 91(3), 552–557. <https://doi.org/10.1213/00000539-200009000-00009>
10. Mostofi, K., & Destandau, J. (2017). Endoscopic anatomy and features of lumbar discectomy by Destandau technique. *Interdisciplinary Neurosurgery*, 7, 75–77. <https://doi.org/10.1016/j.inat.2016.11.009>

The article has been sent to the editors 11.12.2023

ПОПЕРЕКОВА ДИСКЕКТОМІЯ З ДЕКОМПРЕСІЄЮ КАНАЛУ ЗА СИСТЕМОЮ DESTANDAU ENDOSPINE

Сантош Кумар Саху¹, Дататрея Кар²

¹ Ортопедичне відділення, Інститут медичних наук і лікарня ім. Сікши 'О' Анусандхан, Бхубанешвар. Індія

² Відділ медичних досліджень, Інститут медичних наук і лікарня ім. Сікши 'О' Анусандхан, Бхубанешвар. Індія

✉ Dr. Santosh Kumar Sahu, MS: drksims@gmail.com

✉ Dr. Dattatreya Kar, PhD: drdkar2@gmail.com