

УДК 617.582:616.728.2-001.31](045)=161.2=111

DOI: <http://dx.doi.org/10.15674/0030-59872023498-102>

Completely slipped capital femoral epiphysis in an 11 year old girl successfully treated by DUNN's open reduction through GANZ's surgical dislocation of the hip (clinical case)

B. Romanyshyn¹, A. Schchurovsky¹, G. Ulrich Exner²

¹ Western Ukrainian Specialized Children's Medical Centre, Lviv

² Orthopaedie Zentrum Zuerich Hirslanden Klinik im Park. Switzerland

Slipped capital femoral epiphysis (SCFE) is a hip condition that occurs in teens and preteens who are still growing. Treatment for SCFE involves surgery to stop the head of the femur from slipping any further. Without early detection and proper treatment, SCFE can lead to potentially serious complications, including rapid degeneration of the femoral head and/or painful arthritis in the hip joint. Objective. Our case is presented to familiarize with the technique of safe surgical hip dislocation for the treatment of intra-articular hip pathologies. Case report and Methods. After collision while playing the 11 year old girl developed left hip pain still allowing to walk. Imaging documented an acute slipped femoral capital epiphysis with the metaphysis articulating against the acetabulum. The patient was underwent open reduction could be performed using the DUNN procedure modified by GANZ. 6 weeks later prophylactic screw stabilization of the healthy right hip followed. Results. At 9 months follow-up the patient walks painfree with symmetric range of motion. Conclusion. The goal of treatment is to prevent the mildly displaced femoral head from slipping any further. This is always accomplished through surgery. Early diagnosis of SCFE provides the best chance of stabilizing the hip and avoiding complications. When treated early and appropriately, long-term hip function can be expected to be very good. Once SCFE is confirmed, the child will not be allowed to put weight on their hip and will be admitted to the hospital. In most cases, surgery is performed within 24 to 48 hours. In patients with unstable SCFE, the surgeon may first make an open incision in the hip, then gently manipulate (reduce) the head of the femur back into its normal anatomic position. The surgeon will then insert one or two metal screws to hold the bone in place until the growth plate closes. Sometimes surgeon may recommend inserting a screw into the unaffected hip at the same time to reduce the risk of SCFE. Our case demonstrates the value of open reduction of a severely dislocated femoral capital epiphysis in a case otherwise probably needing endoprosthetic hip replacement for restitution of hip function or hip arthrodesis at short-term follow-up.

Звих головного епіфіза стегнової кістки (SCFE) — це захворювання кульшового суглоба, яке виникає у підлітків і дітей, які ще ростуть. Лікування SCFE включає хірургічне втручання, щоб зупинити подальше зміщення головки стегнової кістки. Без раннього виявлення та належного лікування SCFE може призвести до потенційно серйозних ускладнень, включаючи швидку дегенерацію головки стегнової кістки та/або болісний артрит у кульшовому суглобі. Мета. Навести клінічний випадок для ознайомлення з технікою, застосованою нами, для лікування внутрішньосуглобових патологій стегна. Методи. Після зіткнення під час гри в 11-річної дівчинки розвинувся больовий синдром в лівому кульшовому суглобі, який ще дозволяв ходити. Візуально зафіксовано повне зміщення епіфіза головки стегнової кістки з метафізом, який з'єднується з кульшовою западиною. Пацієнтці виконали відкриту репозицію за допомогою процедури DUNN, модифікованої GANZ. Через 6 тижнів здійснено профілактичну гвинтову стабілізацію здорового правого стегна. Результати. Через 9 міс. спостереження хвора ходить без болю із симетричним діапазоном рухів. Висновок. З метою запобігання подальшого зміщення головки стегнової кістки пацієнта госпіталізують і забороняють навантажувати уражену кінцівку, операція виконується протягом 24–48 год. У разі повного звиху головки хірург може спочатку зробити відкритий розріз стегна, а потім обережно маніпулювати голівкою і перемістити її у нормальне анатомічне положення. Потім ми застосуємо один або два металевих гвинти, щоб утримувати кістку на місці, доки зона росту не закритється. Іноді ми рекомендуємо одночасно фіксувати гвинтом також не-уражене стегно, щоб зменшити ризик SCFE. Наш випадок демонструє цінність відкритого вправлення повного звиху епіфіза головки стегнової кістки.

Keywords. Slipped capital femoral epiphysis, surgical hip dislocation GANZ's method, open reduction DUNN's method

Introduction

Slipped Capital Femoral Epiphysis (SCFE) is a pathology developing during the pubertal growth spurt [3] presenting with a broad spectrum of severity [1]. Accordingly treatment has to be individualized [2]. The goal of treatment is to prevent secondary coxarthrosis, which in mild slips is best achieved by in-situ pinning to prevent further increase of displacement [19], combination with Imhäuser-Southwick intertrochanteric osteotomy on more severe slips [4], or direct reduction of the slipped epiphysis to restore anatomy as first described by DUNN [1]. Dunn's procedure has been criticized since his publication, as subsequent authors experienced high rates of femoral head necrosis. The major point to reduce the risk of femoral head necrosis has been outlined by DUNN [1] in describing, how to protect the important branches of the medial femoral circumflex vessels to the femoral head, which probably had not been adhered to in the failed cases.

Extensive studies of the vascular anatomy [6, 7, 10] have led Ganz to develop his technique of safe surgical hip dislocation [5] to treat problems not accessible by closed means. Fig. 1 illustrates the normal anatomy of the vessels to the epiphysis in an eleven year old girl.

Surgical dislocation of the hip combined with DUNN's principles has been introduced by Ganz for reduction of the femoral head in severe cases of slipped capital femoral epiphysis to restore the hip anatomy [8, 15].

Since then, the indications for the appropriate treatment of SCFE and results are discussed controversially [7, 9–14].

With the case report we wish to draw attention to this procedure not only to restore anatomy in cases of severe SCFE but also to familiarize with surgical hip dislocation to assess pathology as e.g. tumors around the coxal femoral end and the acetabulum.

Material and Methods

The work was performed in compliance with the current legislation and the article was approved at a meeting of the Bioethics Committee of the Western Ukrainian Specialized Children's Medical Center (Protocol № 93 dated 12.12.2023).

The healthy well proportionate 11 year old premenarchal girl had first mild pain of the left hip after collision with a class mate, but could still walk well. About 4 weeks later she suffered acute incapacitating pain making it impossible to stand and walk. CT — images showed the completely dislocated femoral

epiphysis (SCFE) with the femoral neck metaphysis articulating against the acetabulum (fig. 2).

Two weeks later October 5th, 2022 open reduction of the epiphysis was performed though GANZ' hip dislocation.

Surgical technique followed strictly the steps described in detail [15]; the illustrations herein shall just assist in understanding the critical steps of the procedure (fig. 3).

The patient is positioned in the lateral decubitus and leg and hip are prepped with betadine solution (fig. 4, a). Through a straight lateral incision the anterior margin of the *m. gluteus maximus* is identified and the posterior borders of *m. gluteus medius* and *m. vastus lateralis* with their insertions/origin of trochanter maior are exposed and a sagittal osteotomy of the trochanter maior is performed leaving the insertions of *m. gluteus medius* and *m. vastus lateralis* en bloc with the osteotomized trochanter (fig. 3, a). K-wire insertion and image intensifier control may be used to determine the correct osteotomy plane as the trochanteric insertion of *m. piriformis* protecting the femoral head vessels should not be released from the femur. By retracting the *m. luteus-medius* — trochanter — *m. vastus lateralis* compound medially the hip capsule is exposed. Hohmann retractors are inserted. The hip capsule is incised as shown in (fig. 3, b) antero-lateral strictly along the labrum to avoid injury to the vessels, then along the femoral neck leaving an anterior flap.

The joint is now inspected and a cuneiform segment is resected from the metaphysial femoral stump to shorten the femoral neck as advised by Dunn not to rupture the medial gluteal vessels shortened by the time interval between slip and surgery. It is advisable to transfix the femoral epiphysis against the femoral neck with a K-wire (fig. 4, b) in order to dislocate this bloc out of the acetabulum by externally rotating, abducting and flexing the leg. The femoral epiphysis is now carefully reduced anatomically upon the shortened femoral stump and transfixed with 2 screws. A small drill hole in the femoral head documents persistent blood flow (fig. 4, c).

Following reduction of the hip the maior trochanter is stabilised by 2 lag screws. The patient was mobilized with crutches for partial weight bearing to full weight bearing following prophylactic transfixation of the right hip 7 weeks later November 24th, 2022. At last follow-up in July 2023 the patient was pain-free, fully active with symmetric range of hip motion. X-Ray documents the restored anatomy except shortening as expected without signs of femoral head necrosis (fig. 5).

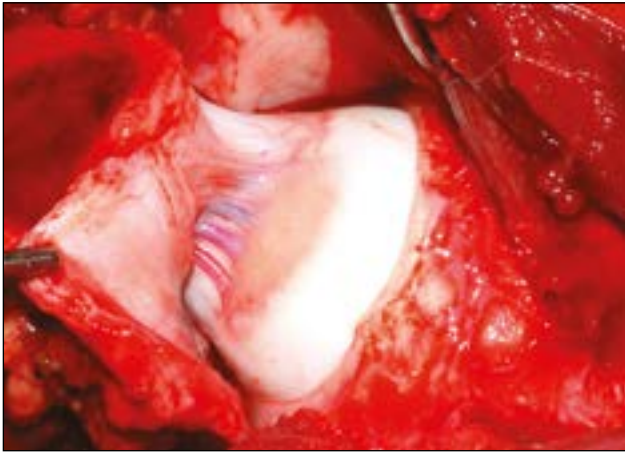


Fig. 1. Deep terminal synovial branches of the medial femoral circumflex vessels to the femoral head in an 11 year old girl exposed for surgical hip dislocation to remove an acetabular tumor. The incision follows antero-later the labrum

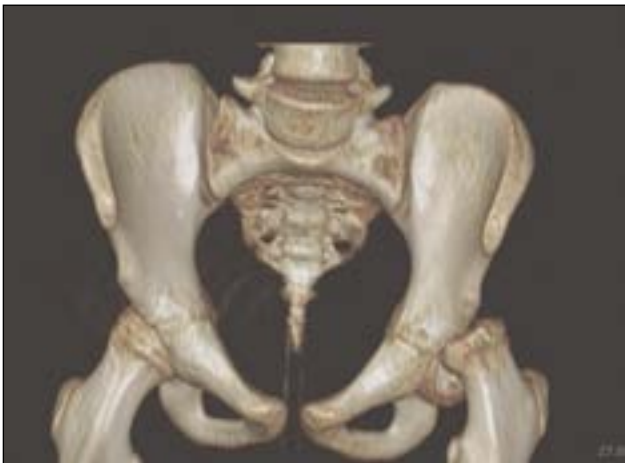
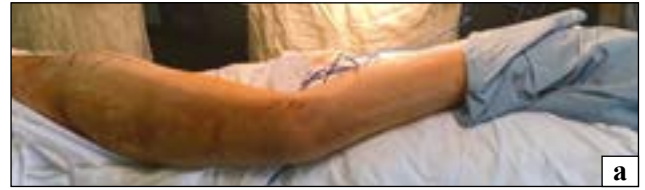

Fig. 2. CT with 3-D-reconstructions show the complete slip of the left femoral epiphysis and the contact of the femoral metaphysis with the acetabular rim

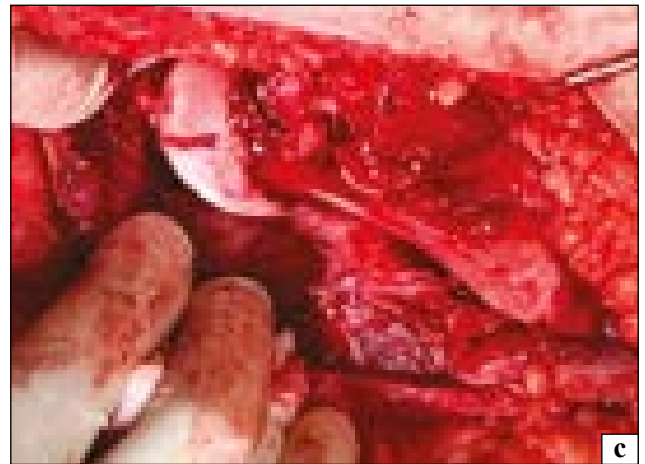

Fig. 4. The patient is positioned in the lateral decubitus (a). The leg is prepped completely for free mobility. The straight lateral incision is marked (b). For dislocation of the epiphysis out of the acetabulum after shortening of the femoral neck a K-wire is inserted to avoid tearing the medial femoral circumflex vessels (c). The femoral head is anatomically repositioned and already transfixed with 2 screws. A drill hole into the femoral head shows blood flow

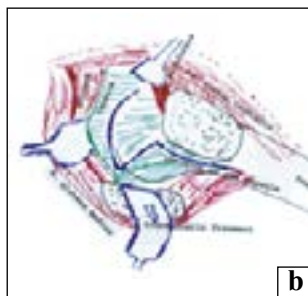
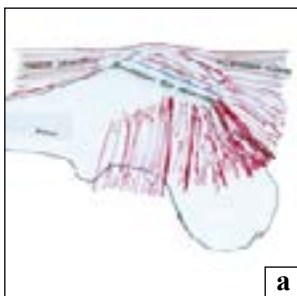


Fig. 3. Illustration of the surgical principles: a) plane for the trochanter flip-osteotomy leaving the attachments of the *m. glutes medius* and *m. vastus lateralis* with the trochanter. The insertion of the *m. piriformis* should be left to protect the medial gluteal artery crossing underneath; b) exposure and incision of the capsule of a left hip. Hohman levers retract the trochanter with the muscular attachments. The insertion of the *m. piriformis* is left on the femur. Of utmost importance is the Z-incision of the capsule (blue line) antero-lateral close to the labrum, then ventral in line with the femoral neck and then along the femur

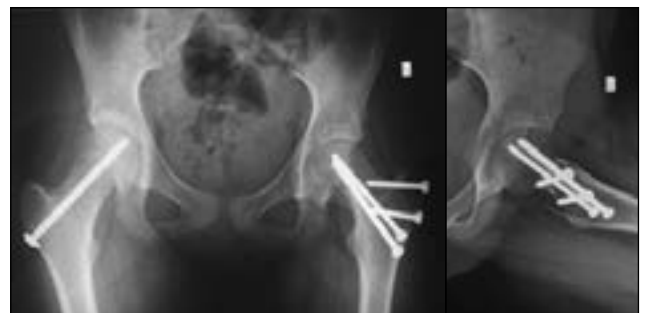

Fig. 5. At 9 months after open reduction of the left hip X-Rays show the correct axial anatomic relations without signs of femoral head necrosis. The right hip was stabilized prophylactically by a transfixing screw

Results and Discussion

Surgical hip dislocation developed by Ganz is a technique allowing to treat pathologies of the acetabulum, femoral head and femoral neck otherwise not accessible. It needs to strictly adhere to the principles protecting the vascular supply of the branches of the medial femoral circumflex artery to the femoral head, as contribution of the ligamentum capitis femoris vessels and the lateral femoral circumflex artery are unfortunately negligible.

Dunn's method with careful exposure and shortening of the femoral neck has been frequently criticized in spite of excellent results in experienced hands [1, 17, 18]. With the introduction of surgical hip dislocation Dunn's method to control the vascular supply to the femoral head is greatly facilitated. However, it needs to strictly follow an anatomic approach especially respecting the medial femoral circumflex vessels by respecting the protective insertion of the *m. piriformis* and correctly positioning the Z-shaped capsular incision as described by [15] and shown in fig 3. Furthermore the anteromedial posterolateral periosteal flaps around the femoral neck have to follow Dunn's description [1].

The indication for open reduction of SCFE needs careful evaluation in the light of good results achieved by in situ pinning or additional intertrochanteric corrective osteotomy as femoral head necrosis in SCFE has never been reported without operative intervention.

The case presented to our understanding would not have been manageable without reduction of the slipped femoral head.

Prophylactic fixation of the contralateral hip in SCFE is controversially discussed regarding indication as well as technique [15, 16]. Factors as body mass, age, type of slip, sex have an influence on the risk for contralateral slipping of SCFE. If carefully done we consider the risk of prophylactic stabilization of the unslipped contralateral hip low and generally recommend it as it was done in the presented case.

Conclusion

Surgical hip dislocation to done according to Ganz principles is a valuable technique to approach intra-articular hip pathologies and can restore the anatomy in severe slipped capital femoral epiphysis as illustrated in the presented case.

Conflict of interest. The authors declare no conflict of interest.

References

- Dunn, D. M. (1964). The treatment of adolescent slipping of the upper femoral epiphysis. *The Journal of Bone and Joint Surgery*, 46-B(4), 621–629. <https://doi.org/10.1302/0301-620x.46b4.621>
- Galletta, C., Aprato, A., Giachino, M., Marre' Brunenghi, G., Boero, S., Turchetto, L., & Massè, A. (2022). Modified Dunn procedure versus percutaneous pinning in moderate/severe stable slipped capital femoral epiphyses. *HIP International*, 32, 813–819. <https://doi.org/10.1177/11207000211004862>
- Exner, G. U. (1986). Growth and Pubertal Development in Slipped Capital Femoral Epiphysis: A Longitudinal Study. *Journal of Pediatric Orthopaedics*, 6(4), 403–409. <https://doi.org/10.1097/01241398-198607000-00003>
- Schai, P. A., Exner, G. U., & Hänsch, O. (1996). Prevention of secondary coxarthrosis in slipped capital femoral epiphysis: a long-term follow-up study after corrective intertrochanteric osteotomy. *J. Pediatr. Orthop. B.*, 5, 135–143. <https://doi.org/10.1097/01202412-199605030-00001>
- Ganz, R., Gill, T. J., Gautier, E., Ganz, K., Krügel, N., & Berlemann, U. (2001). Surgical dislocation of the adult hip. *The Journal of Bone and Joint Surgery. British volume*, 83-B(8), 1119–1124. <https://doi.org/10.1302/0301-620x.83b8.0831119>
- Kalhor, M., Horowitz, K., Gharehdaghi, J., Beck, M., & Ganz, R. (2012). Anatomic Variations in Femoral Head Circulation. *HIP International*, 22(3), 307–312. <https://doi.org/10.5301/hip.2012.9242>
- Gautier, E., Ganz, K., Krügel, N., Gill, T., & Ganz, R. (2000). Anatomy of the medial femoral circumflex artery and its surgical implications. *The Journal of Bone and Joint Surgery. British volume*, 82-B(5), 679–683. <https://doi.org/10.1302/0301-620x.82b5.0820679>
- Ziebarth, K., Leunig, M., Slongo, T., Kim, Y.-J., & Ganz, R. (2013). Slipped Capital Femoral Epiphysis: Relevant Pathophysiological Findings With Open Surgery. *Clinical Orthopaedics and Related Research*, 471(7), 2156–2162. <https://doi.org/10.1007/s11999-013-2818-9>
- Fournier, A., Monget, F., Ternynck, C., Fron, D., Mezel, A., Herbaux, B., Canavese, F., & Nectoux, E. (2022). Comparison between anterior cuneiform osteotomy and Dunn procedure in the surgical management of unstable severe slipped femoral epiphysis: A case-control study of 41 patients. *Orthopaedics & Traumatology: Surgery & Research*, 108(1), 103167. <https://doi.org/10.1016/j.otsr.2021.103167>
- Cheok, T., Smith, T., Berman, M., Jennings, M., Williams, K., Poonnoose, P. M., Rawat, J., & Foster, B. (2022). Is the modified Dunn's procedure superior to in situ fixation? A systematic review and meta-analysis of comparative studies for management of moderate and severe slipped capital femoral epiphysis. *Journal of Children's Orthopaedics*, 16(1), 27–34. <https://doi.org/10.1177/18632521221078864>
- Abdelazeem, A. H., Beder, F. K., Abdel Karim, M. M., Abdelazeem, H., & Abdel-Ghani, H. (2016). The anatomical reduction of a moderate or severe stable slipped capital femoral epiphysis by modified Dunn subcapital osteotomy using the Ganz approach. *The Bone & Joint Journal*, 98-B(9), 1283–1288. <https://doi.org/10.1302/0301-620x.98b9.37071>
- Gorgolini, G., Caterini, A., Efremov, K., Petrungaro, L., De Maio, F., Ippolito, E., & Farsetti, P. (2021). Surgical treatment of slipped capital femoral epiphysis (SCFE) by Dunn procedure modified by Ganz: a systematic review. *BMC Musculoskeletal Disorders*, 22(S2), 1064. <https://doi.org/10.1186/s12891-022-05071-9>
- Passaplan, C., Gautier, L., & Gautier, E. (2020). Long-term follow-up of patients undergoing the modified Dunn

- procedure for slipped capital femoral epiphysis. *Bone & Joint Open*, 1(4), 80–87. <https://doi.org/10.1302/2046-3758.14.bjo-2020-0010.r1>
14. Tibor, L. M., & Sink, E. L. (2013). Risks and Benefits of the Modified Dunn Approach for Treatment of Moderate or Severe Slipped Capital Femoral Epiphysis. *Journal of Pediatric Orthopaedics*, 33, S99–S102. <https://doi.org/10.1097/bpo.0b013e3182860050>
 15. Leunig, M., Slongo, T., Kleinschmidt, M., & Ganz, R. (2007). Subcapital Correction Osteotomy in Slipped Capital Femoral Epiphysis by Means of Surgical Hip dislocation. *Oper. Orthop. Traumatol*, 19(4), 389–410
 16. Tomaru, Y., Kamada, H., Tsukagoshi, Y., Nakagawa, S., Onishi, M., Tanaka, K., Takeuchi, R., Mataka, Y., Miyakawa, S., & Yamazaki, M. (2019). Prophylactic pinning should be considered in patients at risk for slipped capital femoral epiphysis. *Journal of Rural Medicine*, 14(2), 191–195. <https://doi.org/10.2185/jrm.3011>
 17. Fish, J. B. (1994). Cuneiform osteotomy of the femoral neck in the treatment of slipped capital femoral epiphysis. *The Journal of Bone & Joint Surgery*, 76(1), 46–59. <https://doi.org/10.2106/00004623-198466080-00002>
 18. Velasco, R., Schai, P. A., & Exner, G. U. (1998). Slipped Capital Femoral Epiphysis: A Long-term Follow-up Study after Open Reduction of the Femoral Head Combined with Subcapital Capital Wedge Resection. *J. Pediatric Orthop. B.*, 7, 43–52.
 19. Aronson, D. D., Peterson, D. A., & Miller, D. V. (1992). Slipped capital femoral epiphysis: the case for internal fixation *in situ*. *Clin. Orthop. Relat. Res*, 281, 115–122.

Стаття надійшла до редакції 12.09.2023

УСПІШНА ВІДКРИТА РЕПОЗИЦІЯ DUNN У ДІВЧИНКИ З ПОВНИМ ЗМІЩЕННЯМ ГОЛОВКИ СТЕГНОВОЇ КІСТКИ ЗА ДОПОМОГОЮ МЕТОДИКИ GANZ ДЛЯ ЗВИХУ СТЕГНА (КЛІНІЧНИЙ ВИПАДОК)

Б. Романишин¹, О. Щуровський¹, Г. Ульріх Екснер²

¹ Західноукраїнський спеціалізований дитячий медичний центр, Львів

² Ортопедичний центр Хірсланден, Цюріх, Швейцарія

✉ Bohdan Romanyshyn, MD: bodyk2005@ukr.net

✉ Alexander Schchurovsky, MD, PhD: oshch@hotmail.com

✉ G. Ulrich Exner, Prof.: guexner@gmail.com