

## ОРИГІНАЛЬНІ СТАТТІ

УДК 616.717/.718-001.3/-001.4-007-089.22(045)=161.2=111

DOI: <http://dx.doi.org/10.15674/0030-5987202345-13>**Methodological principles of diagnosis verification and treatment tactics determination in combat limb injuries with bone defects****O. A. Buryanov<sup>1</sup>, V. P. Kvasha<sup>1</sup>, Yu. L. Sobolevskiy<sup>1</sup>, Yu. O. Yarmoliuk<sup>2</sup>,  
Yu. V. Klapchuk<sup>3</sup>, D. V. Los<sup>4</sup>, V. O. Kuprii<sup>5</sup>, G. B. Kolov<sup>6</sup>**<sup>1</sup> Bogomolets National Medical University, Kyiv, Ukraine<sup>2</sup> National Military and Medical Center «GVKG», Kyiv, Ukraine<sup>3</sup> Military Medical Clinical Center of Northern Region, Kharkiv, Ukraine<sup>4</sup> Military Medical Clinical Center of the Western Region, Lviv, Ukraine<sup>5</sup> SSI «Center for innovative medical technologies of the national academy of sciences of Ukraine», Kyiv<sup>6</sup> SI «Institute of Traumatology and Orthopedics» NAMS of Ukraine, Kyiv

*Objective.* To develop a classification system for long bone defects resulting from combat limb injuries, establish criteria for predicting pathological fractures, and determine indicators for assessing the feasibility of converting the fixation method in combat-related injuries. *Methods.* The modern literature regarding the treatment of combat-related long bone defects resulting was analyzed in three databases: PubMed, Scopus, and Web of Science. The analysis was conducted using keywords such as combat injuries, bone defect, non-union, auto- and allograft transplantation, Ilizarov method — bone transport, Masquelet method — induced membrane, and fixation method replacement. The clinical material used for this study was derived from the evaluation and treatment of 457 patients with long bone defects at the III–IV medical intervention stage. *Results.* The determination of modern perspectives on the fundamental issues of combat injuries, combined with the analysis of treatment outcomes for such patients, enabled the development and validation of a classification of bone defects that incorporates the volume of bone tissue loss. Furthermore, a prognostic table for the risk of pathological fractures in cases of bone defects and a scoring scale for assessing the feasibility of fixation method conversion have been introduced and applied. *Conclusions.* The proposed classification allows the verification of all types of long bone defects. Its application in clinical practice offers the possibility of obtaining optimal and standardized treatment methods for different types of bone defects, thus improving outcomes by choice of appropriate technologies for their replacement. The objectification of fracture risk factors identification for bone defects enables the choice of the method and means of segment stabilization. The assessment of the feasibility of the fixation method change allows the evaluation of the patient's condition and the local status, facilitating the determination of the potential for method conversion — transition from external fixation devices to intramedullary osteosynthesis, significantly reducing complications during this stage.

*Мета.* Розробити класифікацію дефектів довгих кісток у разі бойової травми кінцівок, встановити критерії прогнозування патологічного перелому та показники оцінювання можливості проведення конверсії способу фіксації. *Методи.* У трьох базах даних (PubMed, Scopus і Web of Science) проаналізовано сучасну літературу щодо лікування дефектів довгих кісток за ключовими словами: бойові ушкодження, дефект кістки, незрощення, ауто- та алотрансплантація, метод Ілізарова — кістковий транспорт, метод Masquelet — індукована мембрана, заміна способу фіксації. *Клінічний матеріал* базується на обстеженні та лікуванні 457 пацієнтів із дефектами довгих кісток у наслідок бойових травм на III–IV рівнях надання медичної допомоги. *Результати.* Визначення сучасних поглядів на базові питання бойових ушкоджень, власний аналіз результатів лікування таких пацієнтів дозволив розробити й провести апробацію класифікації дефектів кісток, яка включає обсяг втрати кісткової тканини; прогностичну таблицю ризику патологічного перелому за дефектів кісткової тканини. *Упроваджено* бальну шкалу оцінювання можливості виконання заміни методу фіксації. *Висновки.* Запропонована класифікація дозволяє верифікувати всі типи дефектів довгих кісток і дає змогу отримати оптимальні та стандартизовані методи лікування різних їхніх типів для покращення результатів шляхом вибору адекватних технологій для заміщення остеопластики. Об'єктивізація показників визначення ризику перелому за дефектів кісткової тканини дозволяє обрати метод і спосіб стабілізації сегмента. Бальна оцінка дає змогу визначити загальний стан пацієнта та локальний статус можливості проведення заміни методу стабілізації перелому (апарат зовнішньої фіксації на заглиблений остеосинтез) та суттєво знизити ускладнення під час проведення цього етапу. *Ключові слова.* Бойові ушкодження, дефекти довгих кісток, заміна способу фіксації.

**Keywords.** Combat injuries, long bone defects, fixation method conversion

## Introduction

Bone defects represent a pathological condition characterized by a loss of a portion of bone tissue that lacks the capacity for self-regeneration, even when subjected to appropriate care and surgical stabilization [1].

Bone tissue defects can arise from various causes, such as tumors affecting the musculoskeletal system, infections, high-energy injuries, osteofibrous dysplasias, or congenital abnormalities, for instance, the Adams–Oliver syndrome [2].

According to statistical data, bone defects occur in approximately 0.4 % of all individuals with bone fractures, which translates to roughly one million cases of skeletal trauma. Bone defects most commonly develop in open high-energy injuries, constituting 11.4 % of all open fractures. [3].

A current significant concern is the treatment of bone defects caused by combat injuries, which occur due to the use of firearms or explosives. These injuries result from high-energy impacts and lead to complex structural damage [4].

Systematic studies of injuries among NATO allied forces in Iraq and Afghanistan reveal that limb injuries are the most common, accounting for approximately 39 to 49 % of all injuries, surpassing other types [5]. The treatment of such injuries necessitates a step-by-step and timely approach regarding soft tissue defects, bone tissue issues, infectious complications, and the long-term duration of restorative care [6].

To improve treatment outcomes, it is essential to establish methodological principles for diagnosis verification and develop a classification system for bone tissue defects, serving as the basis for the bone defect repair procedural algorithm and replacement technologies. Additionally, it's crucial to determine objective criteria for the choice between fixation methods, such as external fixation devices or intramedullary osteosynthesis.

*Objective:* to develop a classification system for long bone defects resulting from combat limb injuries, establish criteria for predicting pathological fractures, and determine indicators for assessing the feasibility of converting the fixation method in combat-related injuries.

## Material and methods

The modern literature regarding the treatment of combat-related long bone defects resulting was analyzed in three databases: PubMed, Scopus, and

Web of Science. The analysis was conducted using keywords such as combat injuries, bone defect, non-union, auto- and allograft transplantation, Ilizarov method — bone transport (BT), Masquelet method — induced membrane, and fixation method replacement.

The article inclusion criteria involved full-text articles with clinical studies confirming the treatment of patients with segmental bone defects and non-union using DO (Distraction Osteogenesis), IMT (Intramedullary Transport), FVFG (Free Vascularized Fibular Graft), or auto- and allograft transplantation. Articles were selected if they presented treatment results based on a sufficient number of patients (no less than twenty) and included comparative studies of the mentioned methods, provided they contained quantitative data for method evaluation.

The article non-inclusion criteria involved case reports, pilot studies, and preliminary research.

The clinical material is based on the examination and treatment of 457 patients with combat long bone defects at the III–IV medical intervention stage.

The work was carried out with the grant support of the Ministry of Health of Ukraine, project 0123U101089.

The work was performed in compliance with the current legislation and the article was approved at a meeting of the Bioethics Committee of the SI «Institute of Traumatology and Orthopedics» NAMS of Ukraine (Protocol № 4 dated 14.11.2023).

## Results

When developing the classification of long bone defects, the numerical coding for the humerus, femur, forearm bones, tibia, and their segments, we used the AO/ASIF classification of long bone fractures [7].

This approach is driven by the fact that the AO/ASIF classification is well-known and widely used, which simplifies the implementation and use of the proposed classification.

Figure 1 displays the numbering of long bones of the skeleton and their segments.

This approach also applies to the epimetaphyseal areas, as shown in figure 2.

*Classification of bone tissue defects in firearm injuries*

Epimetaphyseal defects of type A involve defects in the bone tissue of the epimetaphyseal area, characterized by the preservation of the articular surface and the integrity of the cortical layers (fig. 3).

Type B epimetaphyseal defects encompass defects in the bone tissue of the epimetaphyseal area and

the cortical layer with the preservation of the articular surface and without complete bone disintegration (fig. 4).

Type C epimetaphyseal defects encompass defects in the bone tissue of the epimetaphyseal area and the articular surface (fig. 5).

Type D epimetaphyseal defects encompass defects in the epimetaphyseal area, articular surface, and the cortical layer (fig. 6).

Type A diaphyseal defects involve bone defects without compromising the integrity of the bone (fig. 7).

Type B diaphyseal defects encompass bone defects with compromised bone integrity, but with preserved contact in the cortical layer (fig. 8).

Type C diaphyseal defects encompass bone defects with a compromised bone integrity and a complete defect of the segment's area (fig. 9).

An essential aspect of preoperative planning for bone defects is determining the volume of bone tissue loss ( $V \text{ cm}^3$ ).

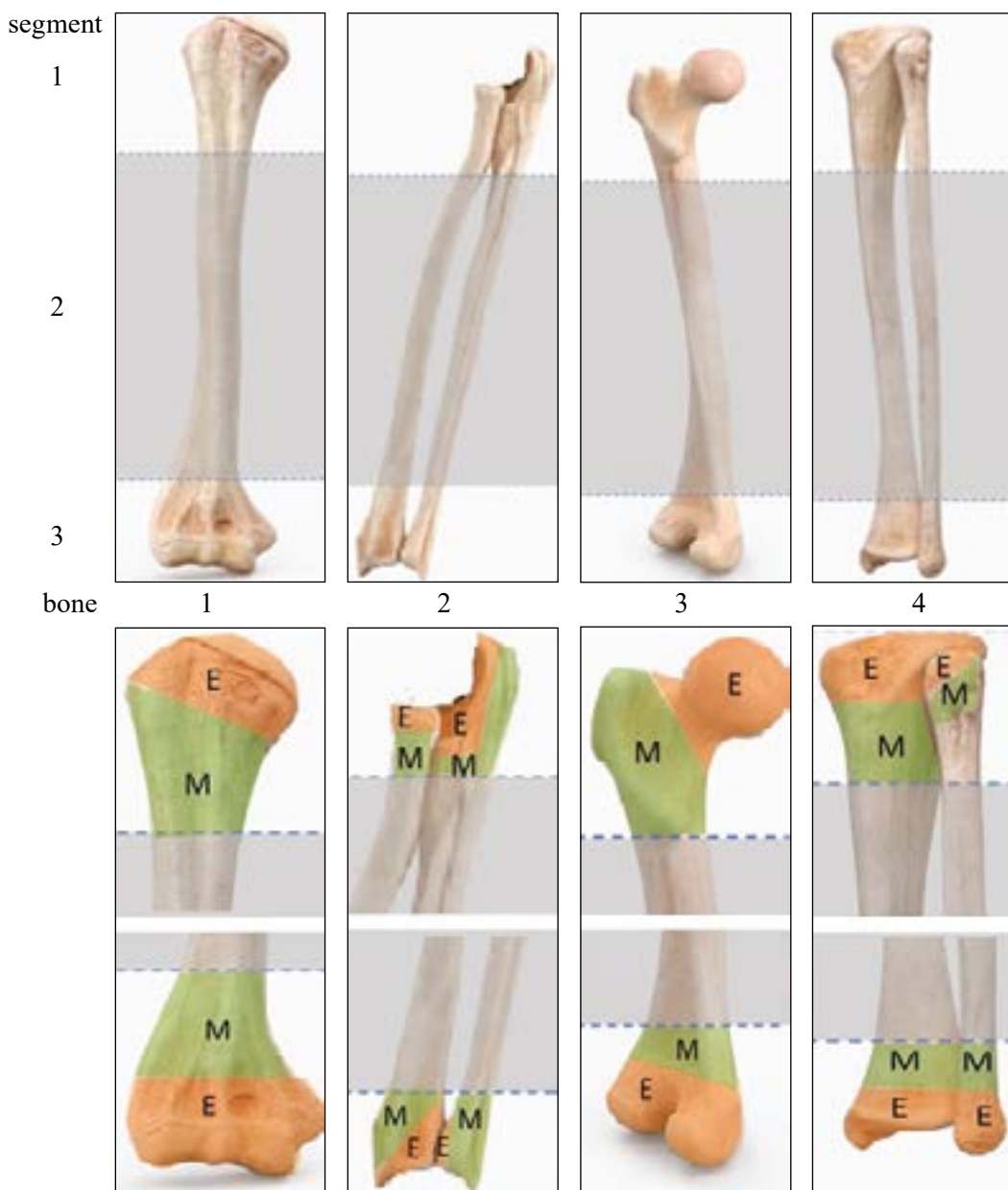
V.1 — bone tissue loss up to  $15 \text{ cm}^3$

V.2 — bone tissue loss from  $16 \text{ cm}^3$  to  $40 \text{ cm}^3$

V.3 — bone tissue loss exceeding  $40 \text{ cm}^3$

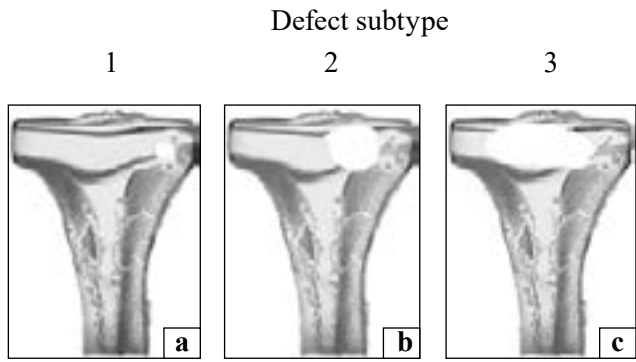
A table was developed to predict fractures in bone defects, specifically to determine the extent of surgical intervention required, whether external or internal stabilization of the segment area is necessary. The table includes defects of types A, B, and C for epimetaphyseal areas and excludes type D. For defects in the diaphyseal area, type A defects are included, while types B and C are excluded.

The primary criteria were identified and assessed using the Harrington methodology [8]. For ease of calculation, numerical characteristics were converted into scores represented by rounded numbers (table 1).

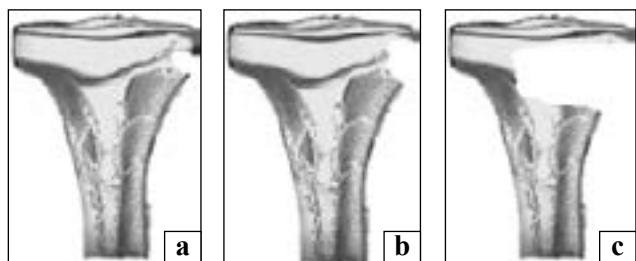


**Fig. 1.** Numbering of long bones of the skeleton and their segments

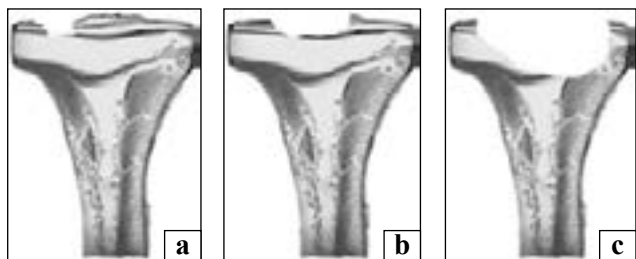
**Fig. 2.** Numbering of the epimetaphyseal sections of long tubular bones



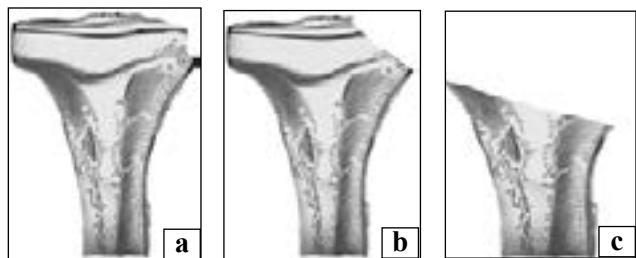
**Fig. 3.** Epimetaphyseal defects of type A, extrajoint epimetaphyseal defect involving: up to 10 % of bone tissue (a); 11–40 % of bone tissue (b); more than 40 % of bone tissue (c)




**Fig. 4.** Epimetaphyseal defects of type B, extrajoint epimetaphyseal defect involving: up to 10 % of bone tissue (a); 11–40 % of bone tissue (b); more than 40 % of bone tissue (c)




**Fig. 5.** Epimetaphyseal defects of type C, epimetaphyseal defect involving: up to 10 % of bone tissue, with an articular surface defect involving up to 25 % (a); 11–40 % of bone tissue, with an articular surface defect ranging from 26 to 50 % (b); more than 40 % of bone tissue, and more than 50 % of articular surface (c)



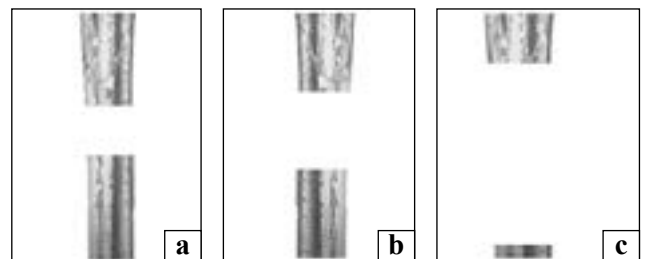
**Fig. 6.** Epimetaphyseal defects of type D: cortical-cancellous defect involving up to 10 % of the epiphyseal-metaphyseal area, with an articular surface defect involving up to 25 % (a); cortical-cancellous defect of the involving 11 to 40 % of the epiphyseal-metaphyseal area, with an articular surface defect involving 26 to 50 % (b); cortical-cancellous defect involving more than 40 % of the epiphyseal-metaphyseal area, with an articular surface defect involving more than 50 % (c)



**Fig. 7.** Diaphyseal defects of type A, bone tissue deficiency: up to 10 %, up to 25 % of the segment's circumference (a); 11–40 %, and 26–50 % in accordance (b); exceeding 40 % and 50 % in accordance (c)



**Fig. 8.** Diaphyseal defects of type B: bone tissue deficiency up to 10 % (a); bone tissue deficiency ranging from 11 to 40 % (b); bone tissue deficiency exceeding 40 % (c)



**Fig. 9.** Diaphyseal bone defects of type C: bone tissue deficiency around the circumference of the segment for up to 3 cm (a); bone tissue deficiency around the circumference of the segment, 3 to 5 cm (b); bone tissue deficiency exceeding 5 cm around the circumference (c)

Therefore, according to the calculations, the risk levels are as follows: extremely high 2.4–3.0 (12–15); high 1.92–2.4 (10–12); moderate 1.11–1.92 (6–10); low 0.6–1.11 (3–6).

An important step in the staged treatment of patients with gunshot injuries to long bones is determining the feasibility of changing the fixation method (conversion): external fixation apparatus to intramedullary osteosynthesis. To facilitate this, a scoring system, the «Assessment of the Possibility of Changing the Fixation Method» scale, has been developed (table 2).

According to the scale: «0» — a score that indicates confidence in performing conversion, «1» — a score that significantly does not affect conversion planning,

*Table 1*  
**Prognostic risk table for fractures in bone tissue defects**

Criterion	Descriptive characteristic	Numerical characteristic	Points
Upper limb	Moderate	0.37–0.64	2–3
Lower limb	High	0.64–0.80	3–4
EMA1	Low	0.20–0.37	1–2
EMA2	Moderate	0.37–0.64	2–3
EMA3	High	0.64–0.80	3–4
EMA1	Moderate	0.37–0.64	2–3
EMA2	High	0.64–0.80	3–4
EMA3	Extremely high	0.80–1.00	4–5
EMA1	Low	0.20–0.37	1–2
EMA2	Moderate	0.37–0.64	2–3
EMA3	Extremely high	0.80–1.00	4–5
DA1	Low	0.20–0.37	1–2
DA2	High	0.64–0.80	3–4
DA3	Extremely high	0.80–1.00	4–5
PTDSN	Extremely low	0.80–1.00	4–5

Note: EM — epimetaphysis area, D — diaphysis area, PTDSN — Post-Traumatic Dystrophy Syndrome.

«2» — characterizes the possible impact of this characteristic on conversion planning, «3» — allows for doubts about the feasibility of conversion, «5» — indicates the impossibility of performing conversion.

The final stage involves summing up all the obtained indicators and conducting an evaluation. In the range from 0 to 7, conversion is possible; from 8 to 10, it's questionable (the sum of scores doesn't rule it out, but may require additional examination or adjustment of therapeutic appointments); and over 10, conversion is contraindicated.

## Discussion

Segmental loss of bone tissue following trauma remains a challenging problem for orthopedic surgeons. The presence of bone defects, combined with infection, significant changes in soft tissue components, and/or their deficiency, create extremely unfavorable conditions for bone regeneration.

The classification of bone defects is an important component in addressing this issue. Its necessity is objectively driven because classification allows for standardizing approaches to treatment, establishing a system for regenerative therapy, defining the types of grafts based on the defect's characteristics, and evaluating results. This provides a foundation for further research and determining the most optimal methods.

Attempts to systematize bone defects and present the data as an effective and practical classification are

not new in modern orthopedics and traumatology. Two of the most well-known classifications, F. Waldvogel and G. Cierny, J. T. Mader, have been in use for over 40 years [9, 10].

Despite the fact that the Cierny and Mader classification was used to determine the surgical treatment strategy based on the bone defect model, the presented indicators showed little correlation with the prognosis after a 2-year observation among candidates for surgical intervention [11].

Considerable attention is given not only to the localization of the defect but also to its length. For example, L. Gordon and C. L. Romano used a 3 cm bone defect, while J. W. May and J. B. Jupiter used a 6 cm bone defect for their classification [12–14].

The parameters for defining small, medium, and large bone defects have remained largely unchanged over the last 30–40 years. The changes mainly relate to their encoding. For example, open fractures are classified based on orthogonal radiographs, assessing the degree and local geometry of bone loss, including: D1 — incomplete defects, D2 — minor/subcritical (complete) defects (< 2 cm), and D3 — segmental/critical defects — defect size ( $\geq 2$  cm).

Incomplete defects (D1) include D1A — < 25 % loss of the cortical shell, D1B — 25–75 %, and D1C — > 75 %. Minor/subcritical (complete) defects (< 2 cm) (D2) include D2A — 2 oblique ends allowing possible overlap, D2B — one oblique end/one transverse end, and D2C — 2 transverse ends. Segmental/critical size defects ( $\geq 2$  cm) include D3A — moderate defects, from 2 to < 4 cm; D3B — large defects, from 4 to < 8 cm; and D3C — massive defects,  $\geq 8$  cm [15].

The determination of the critical size of a bone defect is a topic of debate, and there is no universally agreed-upon definition of what constitutes a critical bone defect. By definition, a critical size bone defect is one that will not spontaneously heal. The SPRINT study identified a critical size defect as one that involves > 50 % of the cortical diameter of a long bone and > 1 cm in length [16].

However, D. W. Sanders et al., when evaluating patients with a «critical size defect» according to the SPRINT definition, found that defects in the diaphysis of long bones larger than 1 cm, and with a circumference involving > 50 % of the cortical area, healed without additional surgical intervention in 47 % of cases. Therefore, the initial definition of a critical size defect was not as «critical» as previously thought [17].

J. F. Keating et al. consider a critical size defect to be a bone deficiency longer than 2 cm and involving more than 50 % loss of circumference [18].

Table 2

**Assessment of the feasibility of changing the fixation method**

Criterion	Characteristics	Points
1	2	3
Wound size in a gunshot injury	Less than 5 cm    Stage 1 From 5 to 10 cm    Stage 2 From 10 to 20 cm    Stage 3 Over 20 cm	In Gustilo Anderson 0 1 3
Swelling during conversion planning	Absent Slight swelling Moderate swelling	0 1 3
Duration of healing for a gunshot injury	Less than 30 days 30–45 days 45–60 days	0 1 3
The surgical intervention area during conversion planning	Hardened scars Unremoved sutures, signs left from external fixation apparatus Signs of inflammation in the limb segment	0 3 5
Trophic changes in the skin of the limb	Absent Slightly expressed Moderately expressed Trophic ulcers	0 1 3 5
The condition of the tissues in the segment during the conversion procedure	No peculiarities Displaced flaps Scar-skin defect Muscle defect Consequences of compartment syndrome (ischemia, clinical manifestations)	0 1 2 3 5
Foreign bodies	Absent Small-sized, single Small-sized, multiple Bullets, large bone fragments within the segment area.	0 1 3 5
Associated pathologies	Varicose veins Major blood vessel occlusion Diabetes mellitus: compensated form Decompensated form	1 2 3 5
Structural bone changes	Absent Signs of local osteoporosis Signs of generalized osteoporosis	0 1 3
The degree of inflammatory changes in the area of removed pins (wires)	Absent Local inflammatory changes in soft tissues Pin-associated osteomyelitis	0 3 5
Injury to major arteries of the segment with signs of segmental ischemia	Absent Restoration of blood flow after injury. Partial absence of blood flow (artery ligation)	0 1 5
The presence of phlebothrombosis	Absent Post- phlebothrombosis syndrome Present	0 3 5
Characteristics of the microflora during the initial bacteriological examination of wound contents	Not detected Gram-positive microflora Gram-negative microflora MRSA (Methicillin-resistant Staphylococcus aureus)	0 2 3 5
Positive trend in body temperature normalization during the treatment of gunshot injuries	Present, with a tendency towards normalization Intermittent Absent	0 1 5
Body temperature during conversion planning	36.5–36.9 °C 37.0–37.3 °C 37.4–37.7 °C	0 3 5
C-reactive protein level during conversion planning	0–10 mg/l Less than 50 mg/l More than 50 mg/l	0 3 5

Continuation of Table 2

1	2	3
Level of white blood cells during conversion planning	Less than $8 \times 10^9$	0
	$9-10 \times 10^9$	3
	$10 \times 10^9$ and more	5
ESR level during conversion planning	Less than 15 mm/h	0
	15–30 mm/h	3
	More than 30 mm/h	5

According to N. Ferreira et al., the critical size defect depends on various variables, including the patient's age and condition, anatomical location, and the state of surrounding soft tissues, rather than just its size [19].

In our opinion, the length of the defect is a significant parameter for determining the treatment approach, but it lacks specificity. Firstly, a 3 cm bone defect in the humerus and femur represents substantially different conditions. In the first case, a potential treatment option might involve shortening the segment without significant functional loss, whereas in the case of a 3 cm femur defect, such an approach is usually inappropriate. Secondly, the volume of the bone tissue deficiency is crucial for selecting the defect-filling option, and it varies at the same length of 3 cm on different segments.

Based on the above, the most significant parameter of a bone defect is the volume of the bone mass deficiency. However, most classifications do regard this specific parameter, which is crucial when considering different treatment options. For example, the comprehensive classification of bone defects published by L. Solomin and T. Slongo in 2022, which is based on the letter-number system of long bone fractures by Muller-AO, also does not consider the volume of bone tissue loss.

Many researchers believe that there is a need for the development of a pragmatic classification system that can be used not only to refine treatment strategies but also to adequately characterize patient cohorts for research purposes. Furthermore, traditional bone defect classification systems are struggling to keep up with modern trends in reconstruction. For example, J. W. May and Jupiter JB's classification of post-infection defects of the tibia does not correspond to the induced membrane technique [24].

The distinction between a stable and an unstable cavity defect is essential when making practical decisions regarding the advisability of using additional fixation methods: external immobilization or intramedullary fixation [25]. An important consideration when treating fractures with bone defects resulting from combat trauma is the decision to convert the

fixation method: replacing an external fixation device with internal constructions [26].

Two-stage treatment of open fractures, especially those of combat origin, is a controversial topic due to the high risk of infectious and purulent complications after using internal constructions, which are likely due to the presence of pathogens in scars, and foreign metal bodies [27, 28]. Therefore, the search for objective criteria that can help make such an important decision is highly relevant.

S. Zhao et al. [29] in their study by the univariate analysis identified six risk factors associated with SSI, including Gustilo classification of fracture, EF time, WBC count, CRP level, ESR, and ALB level. Through the multivariate logistic regression analysis, we showed that CRP level, Gustilo fracture classification, and EF time were independently associated with SSI. Among the mentioned predictors, five risk factors were modifiable, and we observed that they played an important predictive role in protecting patients from postoperative infection.

When deciding on the implementation of the second stage, other researchers also mind the laboratory characteristics [30, 31]. We don't deny the significance of laboratory characteristics in deciding on the fixation method conversion, though, it is necessary to regard other parameters, which are presented in table 2.

## Conclusions

The proposed classification, which includes the volume of bone loss, allows the verification of all types of long bone defects. Its use in clinical practice enables the development of optimal and standardized treatment methods for different types of bone defects, aiming to improve outcomes by selecting suitable techniques for their replacement.

Objective parameters for determining the risk of fracture in bone defects allow to choose the method and means for segment stabilization.

The scoring evaluation of the feasibility of transition to an alternative fixation method provides a systematic approach to assess the patient's condition and the specific local factors. This assessment aids

in determining the potential for a conversion, involving the transition from external fixation to internal osteosynthesis. This approach substantially mitigates complications encountered during this stage of the procedure.

**Conflict of interest.** The authors declare no conflict of interest.

## References

- El-Rashidy, A. A., Roether, J. A., Harhaus, L., Kneser, U., & Boccaccini, A. R. (2017). Regenerating bone with bioactive glass scaffolds: A review of in vivo studies in bone defect models. *Acta Biomaterialia*, *62*, 1–28. <https://doi.org/10.1016/j.actbio.2017.08.030>
- Nauth, A., Schemitsch, E., Norris, B., Nollin, Z., & Watson, J. T. (2018). Critical-Size Bone Defects: is there a consensus for diagnosis and treatment? *Journal of Orthopaedic Trauma*, *32*, S7–S11. <https://doi.org/10.1097/bot.0000000000001115>
- Omar, M., Zeckey, C., Krettek, C., & Graulich, T. (2021). *Open fractures*. *Unfallchirurg*, *124* (8), 651–665. <https://doi.org/10.1007/s00113-021-01042-2>
- Mathieu, L., Bilichtin, E., Durand, M., de l'Escalopier, N., Murison, J. C., Collombet, J.-M., & Rigal, S. (2020). Masquelet technique for open tibia fractures in a military setting. *European Journal of Trauma and Emergency Surgery*, *46* (5), 1099–1105. <https://doi.org/10.1007/s00068-019-01217-y>
- Hoencamp, R., Vermetten, E., Tan, E. C. T. H., Putter, H., Leenen, L. P. H., & Hamming, J. F. (2014). Systematic review of the prevalence and characteristics of battle casualties from NATO coalition forces in Iraq and Afghanistan. *Injury*, *45* (7), 1028–1034. <https://doi.org/10.1016/j.injury.2014.02.012>
- Roberts, D. C., Jose, R. M., Duraku, L. S., Wordsworth, M., Foster, M., Mortiboy, D., Sellon, E., Stapley, S. A., & Power, D. M. (2022). Management of conflict injuries to the upper limb. Part 2: reconstruction and managing complications. *Journal of Hand Surgery (European Volume)*, *47* (8), 787–797. <https://doi.org/10.1177/17531934221105225>
- Martin, J. S., & Marsh, J. L. (1997). Current classification of fractures. *Radiologic Clinics of North America*, *35* (3), 491–506. [https://doi.org/10.1016/s0033-8389\(22\)00591-7](https://doi.org/10.1016/s0033-8389(22)00591-7)
- Samokhvalov, Y., & Burba, O. (2018). Evaluation Of The Effectiveness Of Scientific And Technical Projects Based On The Generalized Harrington Function. Control, navigation and communication systems. *Collection of scientific papers*, *4* (50), 77–85. <https://doi.org/10.26906/sunz.2018.4.077> (in russian)
- Waldvogel, F., Medoff, G., & Swartz, M. N. (1970). Osteomyelitis: a review of clinical features, therapeutic considerations and unusual aspects (first of three parts). *N. Engl. J. Med.*, *282* (4), 198–206. <https://doi.org/10.1056/NEJM197001222820406>
- Cierny, G., & Mader, J. T. (1984). Adult Chronic Osteomyelitis. *Orthopedics*, *7* (10), 1557–1564. <https://doi.org/10.3928/0147-7447-19841001-07>
- Hotchen, A. J., McNally, M. A., & Sendi, P. (2017). The Classification of Long Bone Osteomyelitis: A Systemic Review of the Literature. *Journal of Bone and Joint Infection*, *2* (4), 167–174. <https://doi.org/10.7150/jbji.21050>
- Gordon, L., & Chiu, E. J. (1988). Treatment of infected non-unions and segmental defects of the tibia with staged microvascular muscle transplantation and bone-grafting. *The Journal of Bone & Joint Surgery*, *70* (3), 377–386. <https://doi.org/10.2106/00004623-198870030-00009>
- Romano, C. L., Romano, D., Logoluso, N., & Drago, L. (2011). Bone and joint infections in adults: a comprehensive classification proposal. *European Orthopaedics and Traumatology*, *1* (6), 207–217. <https://doi.org/10.1007/s12570-011-0056-8>
- May, J. W., Jupiter, J. B., Weiland, A. J., & Byrd, H. S. (1989). Clinical classification of post-traumatic tibial osteomyelitis. *The Journal of Bone & Joint Surgery*, *71* (9), 1422–1428. <https://doi.org/10.2106/00004623-198971090-00027>
- Tetsworth, K. D., Burnand, H., Hohmann, E., & Glatt, V. (2021). Classification of Bone Defects: An extension of the orthopaedic trauma association open fracture classification *Journal of Orthopaedic Trauma, Publish Ahead of Print*, *35* (2), 71–76. <https://doi.org/10.1097/bot.0000000000001896>
- Feltri, P., Solaro, L., Di Martino, A., Candrian, C., Errani, C., & Filardo, G. (2022). Union, complication, reintervention and failure rates of surgical techniques for large diaphyseal defects: a systematic review and meta-analysis. *Scientific Reports*, *12* (1). <https://doi.org/10.1038/s41598-022-12140-5>
- Sanders, D. W., Bhandari, M., Guyatt, G., Heels-Ansdell, D., Schemitsch, E. H., Swionkowski, M., Tornetta, P., & Walter, S. (2014). Critical-Sized Defect in the Tibia. *Journal of Orthopaedic Trauma*, *28* (11), 632–635. <https://doi.org/10.1097/bot.0000000000000194>
- Keating, J. F., Simpson, A. H. R. W., & Robinson, C. M. (2005). The management of fractures with bone loss. *The Journal of Bone and Joint Surgery. British volume*, *87-B* (2), 142–150. <https://doi.org/10.1302/0301-620x.87b2.15874>
- Ferreira, N., & Tanwar, Y. S. (2020). Systematic Approach to the Management of Post-traumatic Segmental Diaphyseal Long Bone Defects: Treatment Algorithm and Comprehensive Classification System. *Strategies in Trauma and Limb Reconstruction*, *15* (2), 106–116. <https://doi.org/10.5005/jp-journals-10080-1466>
- Sheridan, G., Solomin, L., Komarov, A., Semenistyy, A., & Rozbruch, S. (2022). Universal long bone defect classification. *Journal of Limb Lengthening & Reconstruction*, *8* (1), 54. [https://doi.org/10.4103/jllr.jllr\\_3\\_22](https://doi.org/10.4103/jllr.jllr_3_22)
- Hotchen, A. J., McNally, M. A., & Sendi, P. (2017). The Classification of Long Bone Osteomyelitis: A Systemic Review of the Literature. *Journal of Bone and Joint Infection*, *2* (4), 167–174. <https://doi.org/10.7150/jbji.21050>
- Rupp, M., Biehl, C., Budak, M., Thormann, U., Heiss, C., & Alt, V. (2018). Diaphyseal long bone nonunions — types, aetiology, economics, and treatment recommendations. *International Orthopaedics*, *42* (2), 247–258. <https://doi.org/10.1007/s00264-017-3734-5>
- Nauth, A., Schemitsch, E., Norris, B., Nollin, Z., & Watson, J. T. (2018). Critical-size bone defects: Is there a consensus for diagnosis and treatment? *Journal of Orthopaedic Trauma*, *32*(3), S7-S11. <https://doi.org/10.1097/bot.0000000000001115>
- May, J. W., Jupiter, J. B., Weiland, A. J., & Byrd, H. S. (1989). Clinical classification of post-traumatic tibial osteomyelitis. *The Journal of Bone & Joint Surgery*, *71* (9), 1422–1428. <https://doi.org/10.2106/00004623-198971090-00027>
- Stafford, P. R., & Norris, B. L. (2010). Reamer-irrigator-aspirator bone graft and bi Masquelet technique for segmental bone defect nonunions: a review of 25 cases. *Injury*, *41*, S72S–77. [https://doi.org/10.1016/s0020-1383\(10\)70014-0](https://doi.org/10.1016/s0020-1383(10)70014-0)
- Dingemans, S. A., Sier, M. A. T., Peters, R. W., Goslings, J. C., & Schepers, T. (2018). Two-stage treatment in patients with patients with high-energy femoral fractures does not lead to an increase in deep infectious complications: a propensity score analysis. *European Journal of Trauma and Emergency Surgery*, *44* (1), 125–131. <https://doi.org/10.1007/s00068-017-0822-6>
- Kortram, K., Bezstarosti, H., Metsemakers, W.-J., Raschke, M. J., Van Lieshout, E. M. M., & Verhofstad, M. H. J. (2017). Risk factors for infectious complications after open fractures: a systematic review and meta-analysis. *International Orthopaedics*, *41* (10), 1965–1982. <https://doi.org/10.1007/s00264-017-3556-5>
- Ukai, T., Hamahashi, K., Uchiyama, Y., Kobayashi, Y., & Watanabe, M. (2020). Retrospective analysis of risk factors



- for deep infection in lower limb Gustilo–Anderson type III fractures. *Journal of Orthopaedics and Traumatology*, 21 (1). <https://doi.org/10.1186/s10195-020-00549-5>
29. Zhao, S., Ye, Z., Zeng, C., Zhang, L., Huang, J., Zhang, W., & Li, R. (2022). Retrospective Analysis of Infection Factors in Secondary Internal Fixation after External Fixation for Open Fracture of a Long Bone: A Cohort of 117 Patients in a Two-Center Clinical Study. *BioMed Research International*, 2022, 1–8. <https://doi.org/10.1155/2022/7284068>
30. Zhang, W., Chen, Z., Wang, W.W., Lu, W. Y., Shang, A. Q., & Hu, L. Q. (2020). Diagnostic value of ROC curve evaluating serum related indexes for bloodstream infection in patients with hematopathy. *Zhongguo Shi Yan Xue Ye Xue Za Zhi.*, 28 (5), 1746–49. <https://doi.org/10.19746/j.cnki.issn.1009-2137.2020.05.052>.
31. Zhao, X.-q., Wan, H.-y., Qin, H.-j., Jiang, N., & Yu, B. (2021). Interleukin-6 versus Common Inflammatory Biomarkers for Diagnosing Fracture-Related Infection: Utility and Potential Influencing Factors. *Journal of Immunology Research*, 2021, 1–11. <https://doi.org/10.1155/2021/1461638>

The article has been sent to the editors 03.11.2023

## МЕТОДОЛОГІЧНІ ПРИНЦИПИ ВЕРИФІКАЦІЇ ДІАГНОЗУ ТА ВИЗНАЧЕННЯ ТАКТИКИ ЛІКУВАННЯ В РАЗІ БОЙОВИХ УШКОДЖЕНЬ КІНЦІВОК ІЗ ДЕФЕКТАМИ КІСТКОВОЇ ТКАНИНИ

О. А. Бур'янов<sup>1</sup>, В. П. Кваша<sup>1</sup>, Ю. Л. Соболевський<sup>1</sup>, Ю. О. Ярмолук<sup>2</sup>,  
Ю. В. Клапчук<sup>3</sup>, Д. В. Лось<sup>4</sup>, В. О. Купрій<sup>5</sup>, Г. Б. Колов<sup>6</sup>

<sup>1</sup> Національний медичний університет імені О. О. Богомольця, Київ, Україна

<sup>2</sup> Національний військово-медичний клінічний центр Головного військового клінічного госпіталь, Київ, Україна

<sup>3</sup> Військово-медичний клінічний центр північного регіону, Харків, Україна

<sup>4</sup> Військово медичний клінічний центр Західного регіону, Львів, Україна

<sup>5</sup> Державна наукова установа «Центр інноваційних медичних технологій НАН України», Київ

<sup>6</sup> ДУ «Інститут травматології та ортопедії НАМН України», Київ

✉ Olexandr Burianov, MD, Prof. in Traumatology and Orthopaedics: [kaftraum@ukr.net](mailto:kaftraum@ukr.net)

✉ Volodymyr Kvasha MD, Doctor of Sci: [vlkvasha@ukr.net](mailto:vlkvasha@ukr.net)

✉ Yuriy Sobolevskiy, MD, PhD: [soburik@icloud.com](mailto:soburik@icloud.com)

✉ Yurii Yarmoliuk, MD, Prof. in Traumatology and Orthopaedics: [yuo1707@gmail.com](mailto:yuo1707@gmail.com)

✉ Yurii Klapchuk MD, PhD: [klapchuks@gmail.com](mailto:klapchuks@gmail.com)

✉ Dmytro Los MD, Doctor of Sci: [dmytrolos@gmail.com](mailto:dmytrolos@gmail.com)

✉ Valentyn Kuprii, MD: [drkuprii@gmail.com](mailto:drkuprii@gmail.com)

✉ Gennadii Kolov, MD, PhD: [Gennadiikolob@gmail.com](mailto:Gennadiikolob@gmail.com)