

SHORT REPORTS AND NOTES FROM PRACTICE

УДК 616.728.3-089.843:004.942](045)

DOI: <http://dx.doi.org/10.15674/0030-59872023180-85>

Use of an individual tool for kinematic alignment of the limb axis during knee arthroplasty (clinical case)

M. L. Golovakha ¹, S. A. Bondarenko ²

¹Zaporizhzhia State Medical University, Ukraine

²«Motor Sich» Clinic, Zaporizhzhia, Ukraine

Objective. To give a clinical example where, under the conditions of gonarthrosis, the patient underwent preoperative planning using modern technologies of three-dimensional modulation; outline the stages of individual instrument preparation and for kinematic alignment of the axis of the lower extremity and installation of knee joint endoprosthesis components. *Methods.* A 69-year-old patient was diagnosed with stage IV right-sided gonarthrosis. For preoperative planning, a computer tomography of the lower extremities was performed in the position of full extension in the knee joints and neutral rotation of the feet (slice thickness 1 mm). A 3D model of the lower extremities was built in the "STL" format in the RadiAnt DICOM Viewer Version 2021.2 program and imported into the FreeformPlus program. Preoperative planning was performed according to the principle of kinematic alignment to restore the constitutional axis of the limb and the inclination of the knee joint plane. The main stages of preparation of an individual instrument and carrying out operative intervention are given. Functional evaluation was performed before and after the operation at different stages according to the EuroQol-5D, KSS, HSS scales and a six-step functional test. *Results.* Individual navigation made it possible to precisely carry out resections of the articular ends and perform the planned kinematic alignment of the limb. According to the EuroQol-5D scale, the improvement of the patient's quality of life was determined, starting from the 3rd day after the operation. According to the KSS scale, an excellent result (85 points) was obtained 6 weeks after the surgical intervention, which remained after 3 months. The evaluation of the result of endoprosthesis according to the HSS scale after 6 weeks was 36 points, after 3 months — 38 points. *Conclusions.* A clinical example of the use of an original individual instrument for knee endoprosthesis showed the main advantages of the method — accurate installation of endoprosthesis components according to the preoperative design, which ensured high patient satisfaction and a good functional result.

Мета. Навести клінічний приклад, де за умов гонартрозу пацієнтові виконано передопераційне планування з використанням сучасних технологій тривимірного модулювання; викласти етапи підготування індивідуального інструмента для кінематичного вирівнювання осі нижньої кінцівки та встановлення компонентів ендопротеза колінного суглоба. *Методи.* У пацієнтки віком 69 років встановлено діагноз: правобічний гонартроз IV стадії. Для передопераційного планування виконано комп'ютерну томограму нижніх кінцівок у положенні повного розгинання в колінних суглобах і нейтральній ротації стоп (товщина зрізів 1 мм). Побудовано 3D-модель нижніх кінцівок у форматі «STL» у програмі RadiAnt DICOM Viewer Version 2021.2 та імпортовано в програму FreeformPlus. Передопераційне планування виконано за принципом кінематичного вирівнювання для відновлення конституціональної осі кінцівки та нахилу площини колінного суглоба. Наведено основні етапи підготовки індивідуального інструмента та проведення оперативного втручання. Функціональне оцінювання виконано до операції та після неї на різних етапах за шкалами EuroQol-5D, KSS, HSS та функціональною пробою шести кроків. *Результати.* Індивідуальна навігація дала змогу точно провести зпили суглобових кінців і виконати відповідне до запланованого кінематичне вирівнювання кінцівки. За шкалою EuroQol-5D визначено покращення якості життя пацієнтки, починаючи з 3-ї доби після операції. За шкалою KSS отримано відмінний результат (85 балів) через 6 тижнів після хірургічного втручання, який зберігся й через 3 міс. Оцінка результату ендопротезування за шкалою HSS через 6 тижнів склала 36 балів, через 3 міс. — 38 балів. *Висновки.* Клінічний приклад використання оригінального індивідуального інструмента для ендопротезування колінного суглоба показав основну переваги методу — точне встановлення компонентів ендопротеза згідно з передопераційним проектуванням, що забезпечило високу задоволеність пацієнта та добрий функціональний результат. *Ключові слова.* Колінний суглоб, гонартроз, ендопротезування, індивідуальний інструмент

Key words. Knee joint, gonarthrosis, total arthroplasty, patient specific instrument

Introduction

For many years, endoprosthetic repair of the knee joint has been an effective method of treating its diseases. Unfortunately, with the increase in the number of operations, the share of unsatisfactory results due to various reasons has also increased (up to 30 %) [1, 2]. In order to reduce the number of dissatisfied patients, high-tech systems for endoprosthetic repair are used, tools are modernized, surgeons improve their skills, etc.

For a very long time, mechanical alignment of the limb was considered optimal for installation of knee joint endoprosthesis [3]. However, even supporters of this idea point out that currently there is a large number of dissatisfied patients after arthroplasty (up to 20 %) [4]. Recently, new approaches to reducing the specific weight of such cases have been discussed and researched. These are computer navigation, an individual tool for endoprosthetic repair and the use of robotics, which increase the accuracy of the installation of endoprosthesis components, which in practice improves treatment results [5, 6].

The idea of individual endoprosthetic repair of the knee joint is most consistently implemented in the concept of kinematic alignment [7, 8]. It is not new, proposed by Hungerford, Kenna, and Krackow [9, 10] and approved by the Food and Drug Administration (FDA) in 1984, but due to the lack of suitable materials for the manufacture of implants, it was not implemented at that time. For the first time, kinematic alignment was performed in 2006 using conventional tools. The idea is to position the components of the endoprosthesis individually to restore the pre-arthritic, not always mechanically correct, limb axis and knee joint line. The femoral component is installed in the anatomical position, as it was before the appearance of the deformation. The position of the tibial component also corresponds to the anatomy of the knee, which always coincides with the restoration of good soft tissue balance. Many studies have already been published showing the clinical advantage of kinematic alignment over mechanical alignment [11–14]. It has also been proven that the frequency of revision interventions in such cases has not increased, but the functional results are better [15, 16].

Purpose: to provide a clinical example where, under the conditions of gonarthrosis, the patient underwent preoperative planning using modern technologies of three-dimensional modulation; outline the stages of preparation of an individual tool for kinematic alignment of the axis of the lower limb and installation of knee joint endoprosthesis components.

Material and methods

The study was approved by the local bioethics committee (Bioethics Committee of Zaporizhzhya State Medical University, Protocol No. 7 dated 26.10.2016).

A 69-year-old female patient D. presented with discomfort, pain while walking and at rest, lameness, restriction of movement, and deformation of the right knee joint (Fig. 1, a, b). She was ill for at least 8 years, received conservative treatment with temporary relief, reported exacerbations 1–2 times a year. Over the past year, the pain has increased, and the varus deformity has begun to progress. The X-ray showed signs of stage IV right-sided gonarthrosis (Fig. 1, c).

Concomitant abnormalities: first-degree obesity, compensated type 2 diabetes, high risk of thromboembolic complications (7 points on the Caprini score). Range of motion in the right knee joint: extension — 10°, flexion — 70°. Functional assessment was performed before and after the operation at different stages according to the EuroQol-5D, KSS, HSS scales and a six-step functional test.

For preoperative planning, a computer tomography of the lower extremities was performed in the position of full extension in the knee joints and neutral rotation of the feet (thickness of sections 1 mm). A 3D model of the lower extremities was built (Fig. 2).

Preoperative planning

The 3D model was created in STL format in RadiAnt DICOM Viewer Version 2021.2 and imported into FreeformPlus. Preoperative planning was performed according to the principle of kinematic alignment to restore the constitutional axis of the limb and the inclination of the knee joint plane. The resection plane of the distal and posterior parts of the femur was set at 7 mm, regardless of the obtained angle of deformation. So, we restored the physiological inclination of the plane of the distal part of the femur (in traditional planning in the two-dimensional coordinate system, it was called the line of the knee joint). Planning is done for the Zimmer Nex Gen CR endoprosthesis with a tibial liner thickness of 9 mm.

After modeling the resection of the articular ends, individual bone resection conductors were built, which take into account the design of the tool for endoprosthesis installation (Fig. 3). After making models and individual conductors, they were sent for 3D printing. The finished models were sterilized by the gas method.

Peculiarities of surgical technique

Under spinal anesthesia, an arthrotomy was performed using a standard operative approach, with

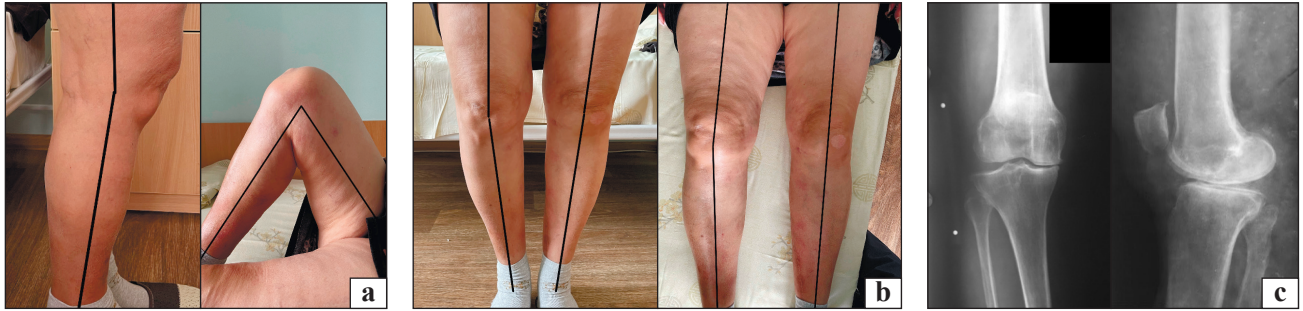

Fig. 1. Appearance of the lower limbs (a, b) and radiograph of the right knee joint (c) of patient D. before the operation: a) function of the knee; b) axes of limbs while standing and lying down

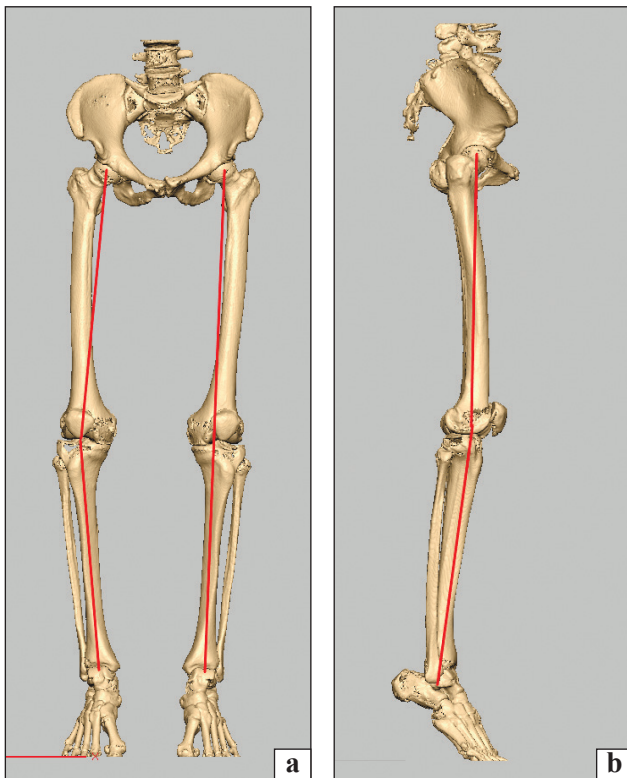


Fig. 2. Deformation of the right lower limb: a) varus 8° , b) flexion 10°

economical selection of the articular ends. For convenience and understanding of the individual navigation position, a bone model was used to check the appropriate fit of the individual conductor (Fig. 3). The conductor was inserted correctly, comparing its position with the model, and the guide pins were inserted, on which the femoral resection block was installed and the distal resection was performed (Fig. 4). The thickness of the resection was checked with a caliper: in our case, it was 8 mm on the lateral condyle, because cartilage remained there, and 7 mm on the medial one, where there was no cartilage (Fig. 4). Similarly, individual navigation was established on the tibial plateau and resection was performed. The thickness of the resected medial and lateral parts was checked,

comparing with the plan (7 mm laterally and 5 mm medially). The stability of the knee joint in the extended position was evaluated. Then it was installed on the final sawing blocks. Extensor and sagittal gaps were again assessed with a spacer. The operation lasted 50 minutes. Drainage was not installed.

Results and their discussion

After the operation, the patient was in the intensive care unit under supervision. On the first day, after the X-ray (Fig. 5) and return to the department, activation was started, the leg was allowed to bend freely in the knee joint (Fig. 6) until pain occurred. It was recommended to put weight on the operated limb until pain occurred while walking with one crutch. The time course of complete blood count indicators on the 1st, 3rd day; 6 weeks, 3 months showed their restoration by the 6th week after operations (Table 1). Radiographs were analyzed and the results were compared with the planned results (Fig. 5). Control radiographs after 1.5 months and 1 year are shown in Fig. 7.

According to the EuroQol-5D score before the operation, the patient had 5 points, which corresponded to the presence of difficulties while walking, constant discomfort, sometimes pain, depression. On the 3rd day, 6 weeks, and 3 months after surgery, according to the same score, there were already 0 points, that is, the patient's quality of life improved significantly. Evaluations of the result of endoprosthetic repair according to the KSS score in time course indicated an excellent result (85 points) as early as 6 weeks after the surgical intervention, the same result was preserved after 3 months.

The evaluation of the result of endoprosthetic repair according to the HSS scoring in 6 weeks was 36 points (indicating a significant improvement in the function of the knee joint, reduction of pain), and 38 points in 3 months.

In time course, according to the results of the «six steps» functional test, an improvement in function

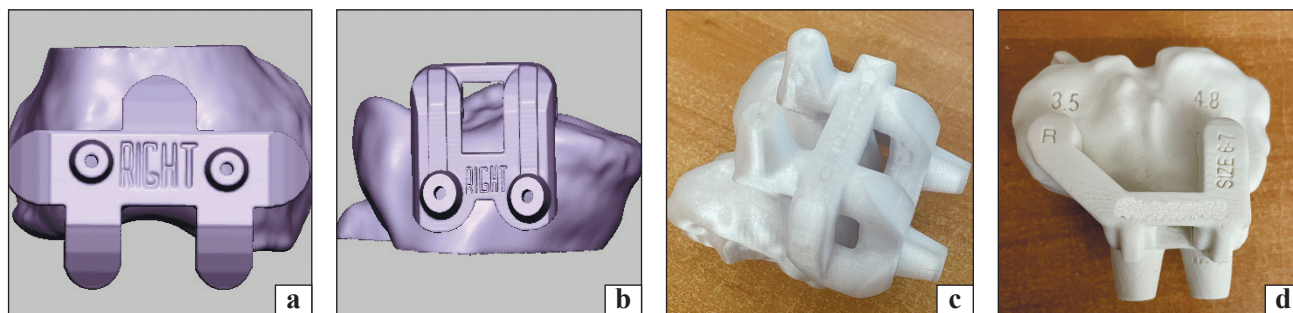


Fig. 3. The final stage of preoperative preparation of an individual instrument for knee endoprosthesis: ready-to-print templates of the hip (a) and lower leg (b); printed templates and models for the thigh (c) and lower leg (d)

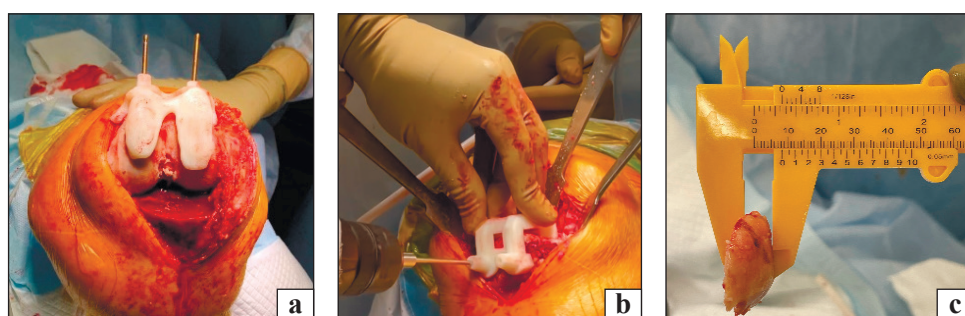


Fig. 4. An example of an operation using an individual tool: installing it for the hip (a) and lower leg (b) with the insertion of pins; caliper measurement of the thickness of the femoral condyles (c)

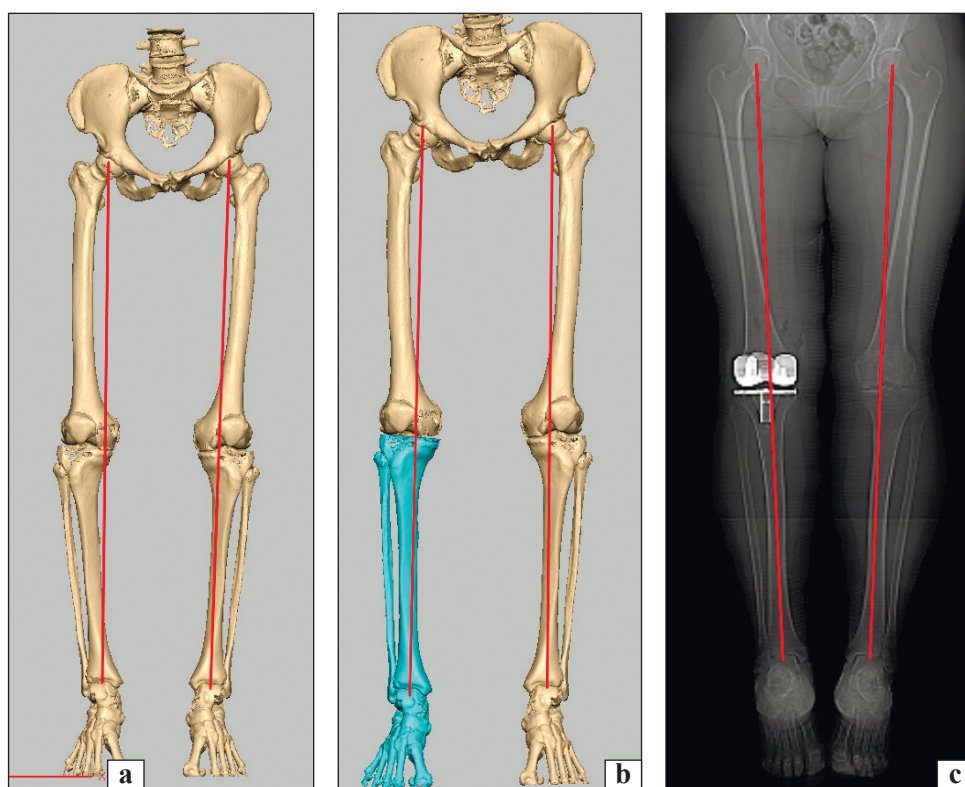


Fig. 5. Comparison of radiographs of patient D. after the operation with the planning result: a) view of the lower extremities before the operation; b) planning of kinematic alignment taking into account a healthy knee joint; c) X-ray of the lower extremities after surgery

was found every day, namely: on the 3rd day with one crutch on the healthy side, the result was 8 seconds; in the 6th week and 3rd month, the patient took six steps in 3 seconds without crutches (Table 2). On the question of satisfaction with the result 3 months after the operation, she chose the answer «very satisfied».

Discussion

Owing to 3D-modeling software, we printed an individual tool for kinematic alignment of the knee joint during endoprosthetic repair. The method made it possible to correctly assess the deformation of the patient's limb and determine the constitutional

Table 1

Time course of restoration of complete blood count indicators

Indicator	Before the operation	Period after the operation			
		1 day	3 days	6 weeks	3 months
Leucocytes, $\times 10^9/l$	5.6	6.0	6.0	6.5	5.6
Erythrocytes, $\times 10^6/mcl$	4.11	3.82	3.67	4.59	4.54
Hemoglobin, g/l	39	103	106	318	137
ESR, mm/h	14	25	17	5.3	3.1
Thrombocytes, $\times 10^9/l$	194	162	142	194	191

Table 2

Results of the «six steps» functional test

Use of additional support	Functional «six steps» test after the operation (amount of seconds spent)				
	1 day	3 days	5 days	6 weeks	3 months
One crutch	9	8	8	—	—
Without crutches	—	5	5	3	3

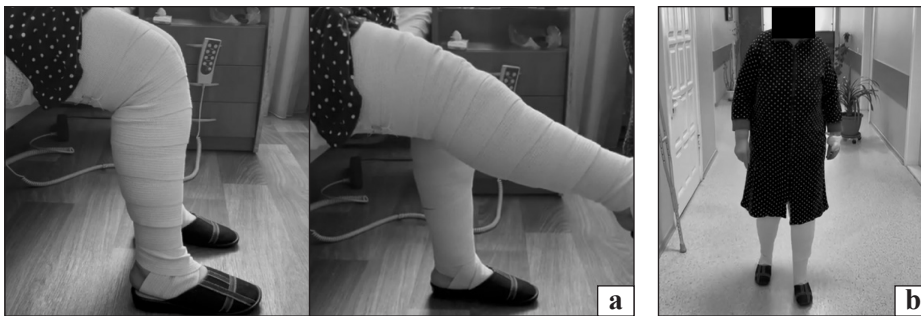

Fig. 6. The function of the knee joint of the patient D. after the operation: a) flexion and extension in the knee joint, 1st day; b) walking without crutches, 5th day

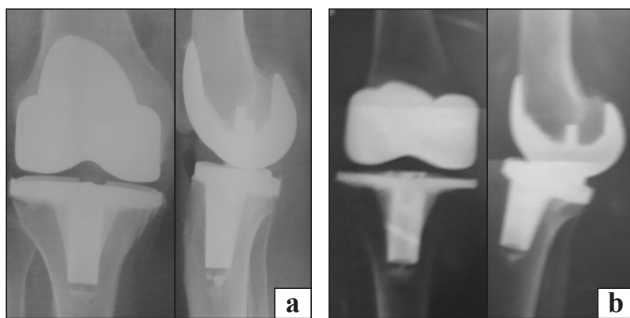


Fig. 7. Radiographs of the knee joint of patient D. after the operation: a) 1.5 months; b) 1 year

axis. The individual navigation made it possible to precisely carry out joint end fusions and perform the planned kinematic alignment of the limb. The use of an individual instrument can reduce the risks of incorrect installation of endoprosthesis components, as well as shorten the duration of the operation due to the possibility of not opening the medullary canal of the femur. With the help of the software, we established a varus deformity of 8° and a defect of the medial tibial condyle in the patient. According to the left lower limb, the kinematic axis was determined and an individual instrument was prepared. It

is worth noting that on the X-ray of the lower limb, the line of the right knee joint after endoprosthetic repair passed in the same way as the contralateral one (Fig. 5, c). At the same time, on radiographs, the line of the right knee joint had a slight varus inclination (Fig. 7). It is this kinematic alignment that allows for improved postoperative recovery, improved knee joint function, and hopefully high patient satisfaction, which we observed in this clinical example. It should be noted that the developed algorithm makes it possible to manufacture an individual tool in 1–2 days after receiving the result of computer tomography of the lower extremities.

Conclusion

A clinical example of the use of an original individual instrument for knee endoprosthesis showed the main advantages of the method, namely accurate installation of endoprosthesis components according to preoperative design, ensuring high patient satisfaction and a good functional result.

Conflict of interest. The authors declare no conflict of interest.

References

1. Patient satisfaction after total knee arthroplasty: who is satisfied and who is not? / R. B. Bourne, B. M. Chesworth, A. M. Davis [et al.] // *Clinical orthopaedics and related research*. — 2010. — Vol. 68 (1). — P. 57–63. — DOI: 10.1007/s11999-009-1119-9.
2. The John Insall Award: patient expectations affect satisfaction with total knee arthroplasty / P. C. Noble, M. A. Conditt, K. F. Cook, K. B. Mathis // *Clinical orthopaedics and related research*. — 2006. — No. 452. — P. 35–43. — DOI: 10.1097/01.blo.0000238825.63648.1e.
3. Total knee arthroplasty / J. N. Insall, R. Binazzi, M. Soudry, L. A. Mestriner // *Clinical orthopaedics and related research*. — 1985. — No. 192. — P. 13–22.
4. Gibon E. Patient satisfaction after total knee arthroplasty: a realistic or imaginary goal? / E. Gibon, M. J. Goodman, S. B. Goodman // *Orthopedic Clinics*. — 2017. — Vol. 48 (4). — P. 421–431. — DOI: 10.1016/j.ocl.2017.06.001.
5. Bellemans J. Neutral mechanical alignment: a requirement for successful TKA: opposes / J. Bellemans // *Orthopedics*. — 2011. — Vol. 34 (9). — P. e507–e509. — DOI: 10.1016/j.ocl.2017.06.001.
6. Residual varus alignment does not compromise results of TKAs in patients with preoperative varus / R. A. Magnussen, F. Weppe, G. Demey [et al.] // *Clinical orthopaedics and related research*. — 2011. — Vol. 469 (12). — P. 3443–3450. — DOI: 10.1007/s11999-011-1988-6.
7. Kinematic alignment in total knee arthroplasty: concept, evidence base and limitations / T. Calliess, M. Ettinger, C. Stukenborg-Colsmann, H. Windhagen // *Der Orthopade*. — 2015. — Vol. 44 (4). — P. 282–286. — DOI: 10.1007/s00132-015-3077-0.
8. Howell S. M. Kinematic alignment in total knee arthroplasty / S. M. Howell, M. L. Hull, M. R. Mahfouz // *Insall and Scott surgery of the knee*. — Philadelphia, PA : Elsevier, 2012. — P. 1255–1268.
9. Total knee arthroplasty: a comprehensive approach / D. S. Hungerford, K. A. Krackow, R. V. Kenna. — Williams & Wilkins, 1984.
10. Hungerford D. S. The porous-coated anatomic total knee / D. S. Hungerford, R. V. Kenna, K. A. Krackow // *Orthopedic Clinics of North America*. — 1982. — Vol. 13 (1). — P. 103–122.
11. PSI kinematic versus non-PSI mechanical alignment in total knee arthroplasty: a prospective, randomized study / T. Calliess, K. Bauer, C. Stukenborg-Colsman [et al.] // *Knee Surgery, Sports Traumatology, Arthroscopy*. — 2017. — Vol. 25 (6). — P. 1743–1748. — DOI: 10.1007/s00167-016-4136-8.
12. Courtney P. M. Early outcomes of kinematic alignment in primary total knee arthroplasty: a meta-analysis of the literature / P. M. Courtney, G. C. Lee // *The Journal of arthroplasty*. — 2017. — Vol. 32 (6). — P. 2028–2032. — DOI: 10.1016/j.arth.2017.02.041.
13. A randomised controlled trial of kinematically and mechanically aligned total knee replacements: two-year clinical results / H. G. Dossett, N. A. Estrada, G. J. Swartz [et al.] // *The bone & joint journal*. — 2014. — Vol. 96 (7). — P. 907–913. — DOI: 10.1302/0301-620X.96B7.32812.
14. Results of an initial experience with custom-fit positioning total knee arthroplasty in a series of 48 patients / S. M. Howell, K. Kuznik, M. L. Hull, R. A. Siston // *Orthopedics*. — 2008. — Vol. 31 (9). — P. 857–863. — DOI: 10.3928/01477447-20080901-15.
15. Slight undercorrection following total knee arthroplasty result in superior clinical outcomes in varusknees / L. Vanlommel, J. Vanlommel, S. Claes, J. Bellemans // *Knee Surgery, Sports Traumatology, Arthroscopy*. — 2013. — Vol. 21 (10). — P. 2325–2330. — DOI: 10.1007/s00167-013-2481-4.
16. Kinematically versus mechanically aligned total knee arthroplasty / H. G. Dossett, G. J. Swartz, N. A. Estrada [et al.] // *Orthopedics*. — 2012. — Vol. 35 (2). — P. e160–e169. — DOI: 10.3928/01477447-201201-04.

The article has been sent to the editors 18.11.2022

USE OF AN INDIVIDUAL TOOL FOR KINEMATIC ALIGNMENT OF THE LIMB AXIS DURING KNEE ARTHROPLASTY (CLINICAL CASE)

M. L. Golovakha¹, S. A. Bondarenko²¹ Zaporizhzhia State Medical University, Ukraine² «Motor Sich» Clinic, Zaporizhzhia, Ukraine

✉ Maxim Golovakha, MD, Prof. in Traumatology and Orthopaedics: golovaha@ukr.net

✉ Stanislav Bondarenko, MD: trauma.bon.s@gmail.com