

УДК 617.583:616.728.3-007.2-089.843](045)

DOI: <http://dx.doi.org/10.15674/0030-598720223-429-38>

Reconstructive surgeries in the case of the knee joint osteoarthritis

O. K. Popsuishapka¹, **V. O. Lytvynshko**^{2,4}, **O. O. Pidgaiska**³,
N. O. Ashukina³, **K. K. Romanenko**¹, **Z. M. Danyschuk**³

¹Kharkiv Medical Academy of Postgraduate Education. Ukraine

²Kharkiv National Medical University. Ukraine

³Sytenko Institute of Spine and Joint Pathology National Academy of Medical Sciences of Ukraine, Kharkiv

⁴CHI «Kononenko Chuguyev Central District Hospital», Kharkiv region. Ukraine

Objective. To clarify the indications and volume of reconstructive surgeries under conditions of knee joint arthritis and to improve the methods of surgical correction of peri-articular deformations using an external rod fixator. *Methods.* During the last 10 years (2012–2022), reconstructive surgeries were performed in 45 patients (49 joints). Indications for surgery were based on the study of pain and its localization, peri-articular deformation of the limb, ultrasound (USD) and X-ray examinations. *Results.* Indications for certain reconstructive surgical interventions on the knee joint are substantiated. The role of pathological changes of the meniscus in the development of knee joint arthritis has been determined. The positive clinical effect of paracapsular resection of the front part of the meniscus with hyperplastic growths of synovial tissue is shown. Deformation of the extremity (43 patients — with varus deformity, 2 — with valgus deformity) limited the function of the limb and caused pain. Surgical treatment in such cases were aimed at eliminating the deformation of the proximal part of the tibia. The types of osteotomies, the features of the author's rod external fixation device application, and the postoperative management of patients are presented. Due to external fixator, it is possible to perform, if necessary, angular correction of the limb axis during the period when the patient begins to walk with partial weight bearing, and the functional load of the limb makes it possible to achieve fusion of fragments within 3.5–4 months. A long-term positive clinical effect was obtained in 42 (93 %) patients. *Conclusions.* Indications for pathogenetic treatment should be based, first of all, on the identification of the source (or pathogenesis) of the pain syndrome, then on the analysis of the type and magnitude of peri-articular deformation of the limb, signs of functional insufficiency of the limb associated with it. In the third place, the X-ray signs should be analyzed. Elimination of angular peri-articular deformation of the limb has a positive effect on the course of knee arthritis, reduces pain, increases physical activity, and slows down the progression of cartilage destruction.

Мета. Уточнити показання та обсяг реконструктивних операцій за умов гонартрозу та удосконалити методики хірургічної корекції навколосуглобових деформацій із використанням зовнішнього стрижневого апарата. *Методи.* Упродовж 10 років (2012–2022) проведено реконструктивні втручання 45 пацієнтам (49 суглобів). Показання до операції ставили на підставі вивчення болю та його локалізації, навколосуглобової деформації кінцівки, ультразвукового і рентгенологічного обстежень. *Результати.* Обґрунтовано показання до певних реконструктивних хірургічних утручань на колінному суглобі. Визначено роль патологічних змін меніска в розвитку гонартрозу. Показано позитивний клінічний ефект паракapsлярної резекції передньої частини меніска з гіперпластичними розростаннями синовіальної тканини. Деформація кінцівки (43 пацієнти — варусна, 2 — вальгусна) обмежувала її функцію, спричинювала біль. Хірургічні втручання в таких випадках були спрямовані на усунення деформації проксимального відділу великогомілкової кістки. Наведено типи остеотомій, особливості встановлення авторського стрижневого апарата зовнішньої фіксації, післяопераційного ведення пацієнтів. Завдяки використанню апарата можна виконувати за необхідності кутову корекцію осі кінцівки в період, коли хворий починає ходити з частковою опорою, а функціональне навантаження кінцівки дозволяє досягти зрощення фрагментів упродовж 3,5–4 міс. Тривалий позитивний клінічний ефект отриманий у 42 (93 %) пацієнтів. *Висновки.* Показання до патогенетичного лікування мають ґрунтуватися, у першу чергу, на ідентифікації джерела (або патогенезу) больового синдрому, потім — аналізі виду, величини навколосуглобової деформації кінцівки, ознак функціональної недостатності кінцівки, пов'язаних із нею. У третю чергу слід аналізувати рентгенологічні ознаки. Усунення кутової навколосуглобової деформації кінцівки має позитивний вплив на перебіг гонартрозу, зменшує біль, підвищує фізичну активність, сповільнює прогресування деструкції хряща. *Ключові слова.* Гонартроз, біль, дегенерація меніска, навколосуглобова деформація, хірургічне лікування, стрижневий апарат зовнішньої фіксації.

Key words. Knee joint arthritis, pain, meniscus degeneration, peri-articular deformity, surgical treatment, external rod fixator

Introduction

Gonarthrosis (osteoarthritis of the knee joint) is a common disease that has an involuted nature and a progressive course. According to a recent systematic review and meta-analysis, the global prevalence of gonarthrosis is 16.0 % among people aged 15 years and older, and the incidence of new cases of the disease per year is 203 per 10,000 population; in particular, in 2020, there were about 654 million gonarthrosis patients over 40 years of age in the world population, and about 87 million were diagnosed for the first time [1].

All components of the joint are involved in the pathological process of gonarthrosis, from the articular surfaces (which consist of hyaline cartilage and subchondral bone) to periarticular structures [2, 3]. It is impossible to cure the disease, but slowing down the process of degeneration of articular surfaces and preserving the functional suitability of the joint for a certain time is real and expedient. Today, the most common method of treating gonarthrosis is total arthroplasty, as it results in a reduction (or elimination) of pain, good functional outcomes and, accordingly, improvement of the patient's quality of life. Based on the analysis of the national registers of the countries of three continents (Sweden, Australia, USA) for the years 2003–2017, a gradual increase in the number of primary and revision knee arthroplasty operations was established [4]. Among the reasons for the increase in the number of specified procedures are their greater acceptance by surgeons and patients [5]; increase in life expectancy [6], the incidence of osteoarthritis not only in people over 65, but also in people aged 30–65 [7, 8].

In our opinion, total endoprosthetic repair should be performed when all compensatory possibilities of the joint have been exhausted and irreversible symptoms have developed, significantly limiting the function of movement. Accordingly, it is necessary to identify signs that may be reversible and in which it is possible to reach a positive effect following reconstructive operations. The main symptom that disrupts the function of the limb is pain. It is known that hyaline cartilage contains neither pain nor proprioceptors [9]. But usually, both researchers and physicians do not pay attention to a specific source of pain in gonarthrosis. The lack of identification of the source of pain does not make it possible to effectively determine treatment tactics. Often, gonarthrosis is accompanied by periarticular deformations of the limb, which are a pathogenic factor of cartilage degeneration. Deformations are combined and multi-

planar. They must be eliminated by surgical interventions, the methods can be different and therefore there is a problem of choosing a technique.

The purpose of the study. To find out the indications and scope of reconstructive operations in gonarthrosis and to improve the methods of surgical correction of periarticular deformations using an external rod device.

Material and methods

The materials of the study were discussed and approved at the meeting of the Bioethics Committee at the State Institution Professor M. I. Sytenko Institute of Spine and Joint Pathology of the National Academy of Medical Sciences of Ukraine (Protocol No. 226 of 17.10.2022).

Over the course of 10 years (2012–2022), we performed reconstructive operations on 45 patients (49 joints) on the basis of State Institution Professor M. I. Sytenko Institute of Spine and Joint Pathology of the National Academy of Medical Sciences of Ukraine, Municipal Budgetary Institution M. I. Kononenko Chuhuiv Central Hospital.

We paid attention to certain pathological signs, based on which indications were given for reconstructive surgical treatment.

Pain and its localization were assessed using *palpation tests*.

The shape and size of the painful meniscus and adjacent tissues in static and dynamic (flexion-extension of the lower leg) conditions were studied using *ultrasonography* (US). Both knee joints were compared. The Toshiba Aplio-500 sonograph with a 5–12 Hz linear sensor was used, the study was conducted by Candidate of Medical Sciences S. M. Yakovenko.

Before *radiographic examination*, the form of the lower limbs in the standing position was clinically assessed. Attention was drawn to the presence of angular deformations in the frontal plane and the possibility of full extension and hyperextension in the knee joint.

X-rays of the knee joint and adjacent areas of the bones were performed in a standing position with equal support on each limb and under the conditions of maintaining an individual distance between the feet. The following indicators were evaluated and measured using the obtained radiographic images:

- the orientation of the joint gap in the frontal plane in relation to the vertical, which was measured by the mechanical proximal medial tibial angle [10] (the edge of the X-ray film was used as a vertical marker, since it coincided with the vertical position of the cassette holder);

- the value of the anatomical medial tibial angle (intersection of the joint line with the anatomical axis of the tibial bone);

- the orientation of the angles of inclination of the tibial plateau in the sagittal plane in relation to the anatomical axis of the tibia and the vertical (mechanical axis of the limb);

- the value of the femoral-tibial angle (intersection of the joint line with the anatomical axis of the femur).

Menisci removed during surgical interventions were subjected to *histological examination*. To do this, they were fixed for 4 days in 10 % neutral formalin, decalcified in a 10 % formic acid solution, dehydrated in alcohols of increasing concentration, soaked in paraffin with xylene and embedded in paraffin. The prepared histological sections 5–6 μm thick were stained with hematoxylin and eosin and analyzed under a BX63 light microscope (Olympus, Japan). A DP73 camera (Olympus) and Cell Sens Dimension 1.8.1 software (Olympus, 2013) were used to obtain digital images.

Results and their discussion

Justification of indications for reconstructive surgical interventions

The type of surgical intervention was chosen following the analysis of the following pathological signs (symptoms and syndromes).

Pain, its localization, nature and origin

Our observations, based on the examination of patients with gonarthrosis (not only in the specified 45), give reason to distinguish at least three variants of the manifestation of the painful symptom:

1. The pain extends to the entire knee joint or to most of it, radiates to the lower leg, is constant, and intensifies during movement and sometimes at night. On palpation, the patient feels pain around the peri-

meter of the joint or part of the perimeter, there is tissue swelling in these areas. Limited flexion function due to synovitis. Such pain gradually decreases or disappears on its own, or under the influence of conservative treatment. Its origin can be explained by a generalized reaction of acute inflammation of the synovial membrane, which lines the inner surface of the joint capsule. Presumably, the irritant of inflammation is the destruction products of hyaline cartilage. *This condition can be called generalized inflammation of the synovial membrane and periarthicular tissues.*

2. The pain has a local character and is most often localized in the projection of the anterior horn of the internal meniscus, less often in the projection of the external or, sometimes, the posterior horn. This pain can be reproduced by palpation of tissues in the projection of the joint gap. In particular, the phenomenon manifests itself in positive Baikov symptom. It can be checked as follows: in the bending position of the shin at a right angle, the projection of the front horn of the meniscus is pressed with the first finger and is slowly unbent. Normally, this procedure is painless; in the case of a positive test local gradually increasing pain appears under the finger during extension. This symptom is described for meniscal tears [11], but as evident, it also appears in the case of gonarthrosis and is associated with pathomorphological changes in this part of the meniscus and adjacent tissues. The mechanogenesis of the indicated symptom, based on clinical, radiometric and ultrasound studies, is as follows: in the knee joint, unlike others, during flexion–extension, the rotation axis of the lower leg simultaneously moves tangentially in the anterior-posterior direction [12]. This is due to the elliptical profile of the femoral condyles. In the knee extension position, the part of the condyle contacts the tibial plateau with a larger radius of curvature, and in the flexion position with a smaller one (Fig. 1).

As a result, in the extended position of the knee, the space between the articular surfaces of its front part decreases, and in the extended position, it increases. At the same time, the menisci with the capsule, deforming accordingly, play the role of a dynamic volume-contact compensator. When, as a result of the degenerative-proliferative process, the volume of the meniscus increases and its mechanical properties change, a conflict appears in the corresponding part of the joint, which manifests itself as a positive Baikov symptom.

Ultrasound shows that normally the anterior horn of the inner meniscus moves back and forth in

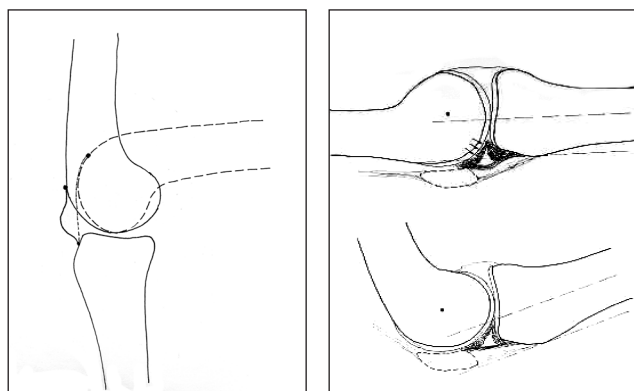


Fig. 1. Skiagram from radiographic images, showing the relationship of the articular surfaces of the knee joint in the position of flexion and extension, and a diagram illustrating the clamping of the pathologically changed meniscus

the sagittal plane relative to the articular surfaces during flexion-extension. In the presence of a positive Baikov symptom during real-time ultrasonography, we can see the front horn of the meniscus increased in volume compared to the symmetrical one, and in the process of knee extension, it is «bitten» by the articular surfaces.

Histological changes in the meniscus and adjacent capsule. During the microscopic examination, irreversible dystrophic changes were detected in the tissues of the meniscus and the capsule adjacent to it (Fig. 2) [13]. In particular, the capsule of the joint, adjacent to the meniscus, consisted of randomly arranged bundles of collagen fibers, between which there were vessels with a thin lumen and a thick hyalinized wall, interstitial edema was noted (Fig. 2, b). This indicates a violation of blood supply and disassembly of collagen structures. Diffuse, multiple cracking of the matrix with the formation of vascular slits, its uneven coloring, areas

without cells were found throughout the entire area of the meniscus. The surface zone of the meniscus was made of dense connective tissue, represented by thick bundles of collagen fibers. Fibroblasts with hyperchromatic nuclei and elongated cytoplasm were located between them. In contrast to the normal structure of the surface zone of the meniscus, vessels with thickened hyalinized walls and narrow lumens were found in it. Proliferation of fibroblasts was recorded around them (Fig. 2, c). This indicates fibrotization of the meniscus.

In the deeper layers of the meniscus, an increase in the basophilia of the intercellular substance is found, among which there are rounded cells with flattened nuclei, areas without cells (Fig. 2, d).

Thus, it turns out that in gonarthrosis, pathomorphological changes occur around the front horn of the meniscus, as well as in the meniscus itself, which change its shape and mechanical properties. Proliferation of synovial tissue occurs near the red

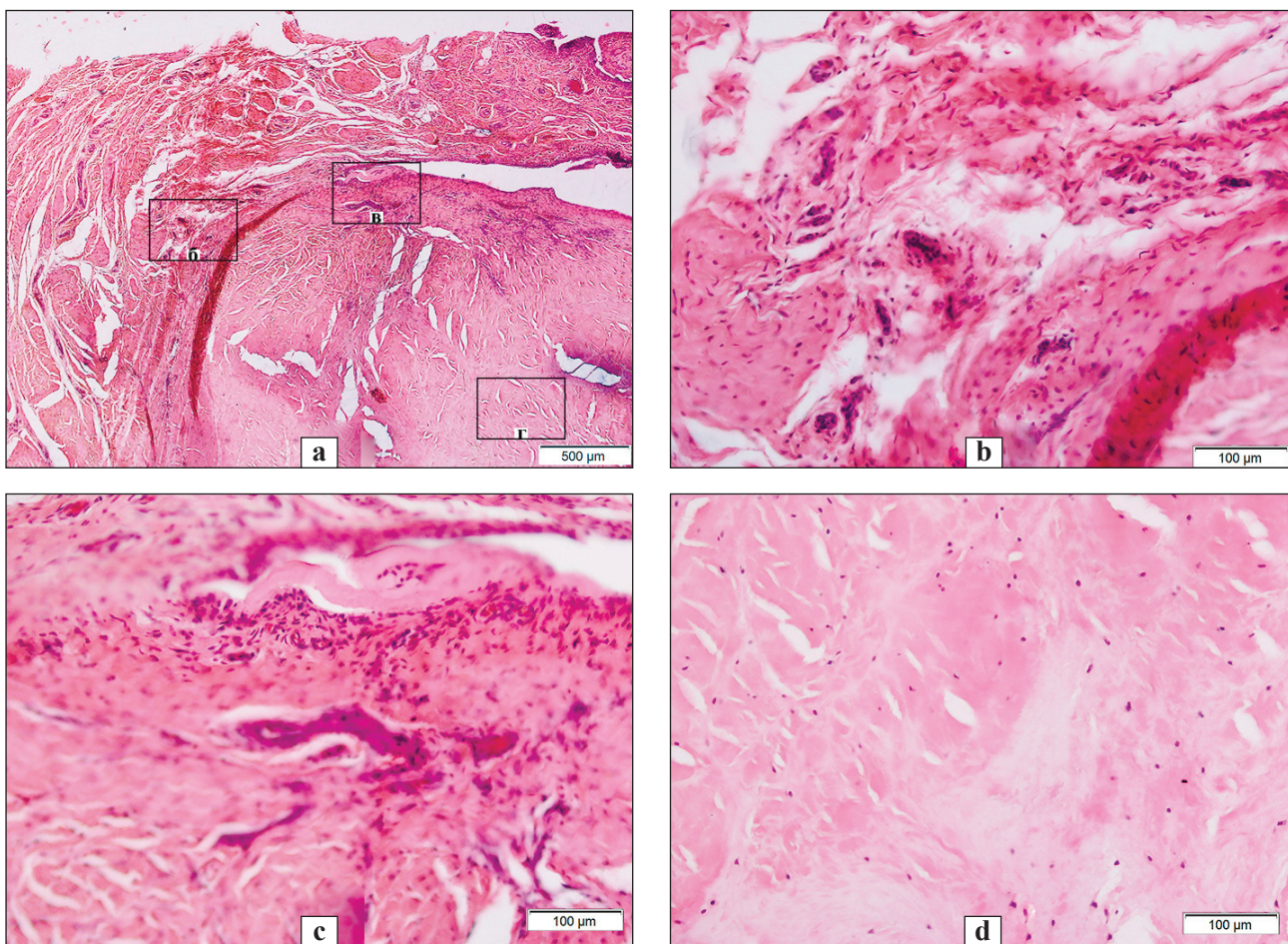


Fig. 2. A fragment of the meniscus and the joint capsule adjacent to it with destructive disorders: a) delamination and cracking of the matrix with the formation of vascular gaps, areas without cells; b) joint capsule: scattered bundles of collagen fibers, vessels with a thin lumen and a hyalinized wall, interstitial edema; c) the surface zone of the meniscus is filled with dense connective tissue, perivascular proliferation of fibroblasts, hyalinized vessel walls; d) basophilic intercellular substance, round cells with flattened nuclei, areas without cells. Fig. 2 b, 2 c and 2 d are fragments of Fig. 2, a. H&E stain

(pericapsular) part of the meniscus, vascularization, infiltration and proliferation with fibrous degeneration occurs in the pericapsular part of the meniscus. The pericapsular part of the meniscus thickens, its elastic properties change, resulting in the stranglehold effect, which becomes an obstacle to full extension of the knee joint. The source of pain is the hyperplastic synovial tissue, which is under pressure when the leg is fully extended, and as evident, this is clinically manifested by a positive Baikov symptom. During arthrotomy with transection of the meniscus, we observed the effect of the separation of its fragments, and the pericapsular resection of the front part of the meniscus with hyperplastic growths of synovial tissue gave a positive clinical effect — the pain disappeared when standing on a fully extended leg.

In this case, the pain is associated with a local mechanical conflict and a reactive inflammatory-proliferative process in the perimeniscal zone. In such a situation, it is also possible to obtain a temporary positive effect from periarticular blockade with a steroid drug.

The third option is available in the case of periarticular deformation of the limb. In this case, according to patients, the pain is localized on the outer or inner side of the knee joint and lower leg. It appears during or after loading the limb *or is associated with a degenerative and inflammatory process in ligaments and muscles as a result of their mechanical overfatigue.* It can be eliminated only by restoring the correct axis of the limb.

The above variants of pain can be found both separately and combined in various combinations, creating a pain syndrome. Understanding the origin of pain symptoms makes it possible to choose pathogenic treatment.

Character of limb deformation. According to the type of periarticular deformity, the patients were distributed as follows. The group of patients with gonarthrosis, which was accompanied by varus deformation of the limb at the level of the knee joint, turned out to be the most numerous – 43 individuals. Among them, in 28 patients, the deformation was formed due to the asymmetry of the joint space; in the rest of the patients it was associated with the asymmetry of the joint space and a change in the anatomical shape of the proximal part of the tibia. The value of the mechanical medial tibial angle in them was 68°–85°. Gonarthrosis combined with valgus deformity was present in two patients. Their mechanical medial tibial angle was 97°–112°.

More than half of the patients (29) noted the development or increase of limb deformity during the last

1–2 years. It should be noted that the deformation bothered the patients no less than the pain; it interfered with movement and caused pain in other parts of the limb.

The degree of damage to the joint by the degenerative process was different — from the initial manifestations to those expressed in the form of narrowing of the joint space and limitation of the amplitude of movements, instability.

The types and volume of reconstructive surgical interventions (see Table) were determined by persistent pathological signs that limited the function of the limb. They are mainly aimed at eliminating the deformation of the proximal part of the tibia. In second place was the removal of the hyperplastically changed part of the meniscus, which is the source of the pain syndrome.

Surgical interventions

Let us start with the removal of the pathologically changed meniscus. More often, we arthroscopically removed the front part of the meniscus, which gave the presentation of its painful strangulation, detected the day before clinically and ultrasonographically. But this procedure has certain limitations. In particular, with the help of an arthroscopic tool, it is not possible to remove the thickened part of the meniscus, adjacent to the capsule and clamped («bitten») between the articular surfaces during full knee extension. In addition, with arthroscopic access, the phenomenon of strangulation of this part of the meniscus, firmly connected to the capsule, remains. This continues to cause pain or is accompanied by its rapid recurrence. To free the joint space from the retracted capsular meniscus strangulation, it must be cut in the sagittal plane. We understood this from the persistence of joint pain in two patients during full knee extension after arthroscopic partial meniscal resection. They also had a positive Baikov symptom and a picture of strangulation of the remnants of the anterior horn of the meniscus on ultrasound scans. We were forced to perform a repeated operation — arthrotomy with pericapsular resection of the remnants of the anterior part of the fibrotic degenerate medial meniscus with hyperplastic growths. In both cases, the repeated operation gave a positive effect, the next day, when leaning on the straight limb, the pain disappeared. Therefore, in the future, in cases where the patient had a positive Baikov symptom and there was no overextension of the tibia, we preferred arthrotomy and pericapsular resection of the anterior part of the meniscus, usually medially. Dissection of the skin and capsule was performed vertically along the anterior inner surface of the joint up to 4 cm

long. The meniscus was crossed, after which its edges diverged. Then, pericapsularly, the anterior and medial parts of the meniscus together with the hyperplastic synovial membrane were cut off alternately with surgical scissors. The edges of the cut capsule of the joint were sewn with three stitches without tightening the threads.

The next stage was the osteotomy of the proximal part of the tibia. But first, let us justify our choice of the type of osteotomy (opening or closing) and its level. In patients with gonarthrosis, we performed an isolated opening osteotomy of the tibial bone in the case of a small deformity, when the medial tibial angle was not less than 78° and the joint was not limited by physiological overextension. A closing osteotomy of the tibia was used after resection of a small area of the fibula, under conditions of a medial tibial angle of less than 78° and a flexion contracture in the knee joint.

Regarding the level of the osteotomy, in all cases its plane passed slightly below the top of the *tuberositas tibiae* (Fig. 3), although in many publications

the authors recommend performing it above the *tuberositas tibiae* [10].

Our arguments in favor of the chosen level of osteotomy are:

- the zone is easily accessible, in terms of peeling off the periosteum, inserting the protector on the back surface of the tibia. Detachment of tissues from the bone in the proximal direction is more traumatic, since muscles are attached here with entrance of epiphyseal vessels;

- this level makes it possible to eliminate the deformation, achieve the necessary correction without disturbing the anatomical shape of the proximal part of the tibia;

- the proximal fragment is of sufficient size for its effective fixation with two rods inserted in different planes;

- exclusion of additional hyperpressure in the joint due to stretching of the quadriceps muscle of the thigh, in contrast to the osteotomy, which would pass above the tuberosity.

Table

Types and volume of reconstructive surgical interventions

Surgical intervention	Amount
Pericapsular resection of the hyperplastically changed part of the inner meniscus	4
Resection of the area of the fibula, closing «devarizing» osteotomy of the proximal part of the tibia with fixation of the fragments with an external rod apparatus	4
Pericapsular resection of the hyperplastically changed part of the inner meniscus. Opening «devarizing» osteotomy of the proximal part of the tibia with fixation of fragments with an external rod apparatus	9
Arthroscopic partial resection of the internal meniscus. Opening «devarizing» osteotomy of the proximal part of the tibia with fixation of fragments with an external rod apparatus	5
Pericapsular resection of the hyperplastically changed part of the inner meniscus. Resection of the area of the fibula, closing «devarizing» osteotomy of the proximal part of the tibia with fixation of the fragments with an external rod apparatus	18
Arthroscopic partial resection of the internal meniscus. Resection of the area of the fibula, closing «devarizing» osteotomy of the proximal part of the tibia with fixation of the fragments with an external rod apparatus	7
Closing devarizing osteotomy with fixation with an external rod apparatus	2
Total amount of interventions	49

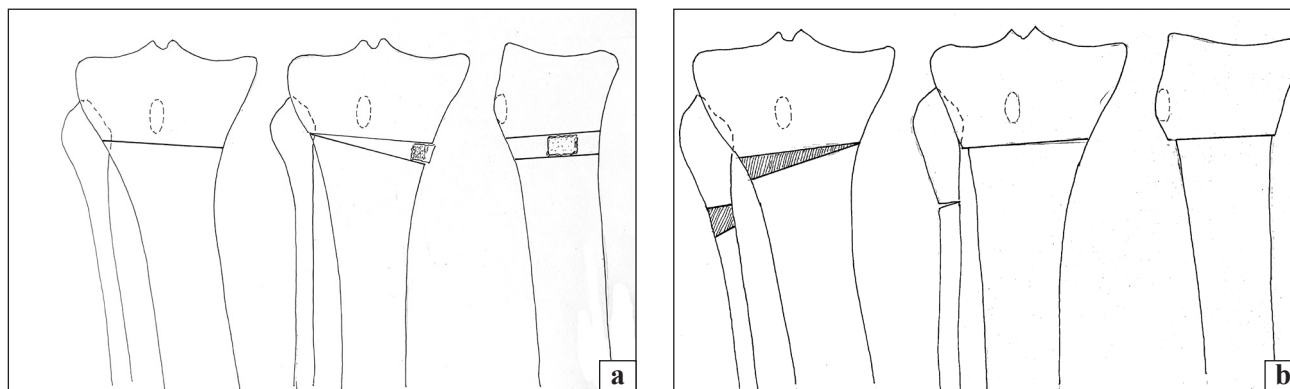


Fig. 3. Schematic representation of the location of the tibia osteotomy plane: a) opening, b) closing

During the *opening osteotomy*, an arcuate soft tissue dissection was performed along the antero-medial surface of the proximal part of the tibia with a length of 5–6 cm. The periosteum was partially exfoliated along the inner front surface. The osteotomy was carried out using two burs, followed by drilling of the bone with a 3.5 mm drill to prevent cracking of the proximal part. First, a wider chisel (30 mm) was used to cut the back of the tibia, deepening it to the outer cortical layer. For this, marks on the surface of the bit were used. Then the front part of the bone was cut with a second chisel. After that, applying effort, it was broken, the chisels were taken out and correction of the axis of the limb was performed. The edges of the bone on the inner surface diverged by a distance of 7 to 20 mm, depending on the degree of correction. The achieved position was fixed with a cortical-cancellous allograft, which was inserted in the form of a spacer between the fragments on the inner surface. According to the osteotomy performed in this way, the fragments can move at an angle in the frontal plane due to their fixation by the periosteum on the outer part and the entire fibula.

The next stage of the operation was fixation of the fragments with an external rod device [14]. The extremity was placed in the position of full extension on the horizontal surface of the operating table. First, the upper rod (1) was screwed in the frontal plane at a distance of 1–1.2 cm from the joint gap after pre-drilling the channel with a 3.5 mm drill. It is advisable to check the place where the drill is inserted radiologically. A semi-ring support was fixed to it so that it was on the front surface of the lower leg. The second (distal) one was attached to it at a distance of 14–18 cm with the help of two screw rods, which were inserted into the outermost holes. The second rod (2) was inserted from the anterior inner surface of the tibia through the hole of the clamp. Drilling and screwing of the second rod was performed in the position of the necessary correction. It is important to ensure that the semi-ring supports are parallel. At this stage, it is advisable to perform X-ray control to assess the degree of correction of the deformity. If the fragments are in a satisfactory position, the third rod (3) is screwed in the plane close to the frontal one into the proximal fragment. It is placed 1–2 cm below the first and connected to the support either by pressing against its lower surface or by means of a removable vertical plate with holes. After threading the third rod, the wound is sutured and the rod is installed. The fourth rod is screwed in the frontal plane from the medial surface at a distance of 8–10 cm from

the lower support and connected to it with a vertical plate.

The location of the apparatus elements on the lower leg is shown in the photograph and diagrams (Fig. 4).

Closing osteotomy

The limb was flexed at the knee joint and internally rotated to perform resection of the fibula. The surgeon was in a sitting position. Access was performed from the posterior outer surface in the projection of the upper part of the fibula. Its area was identified subosseously at a distance of 4–5 cm below the top of the head, and at this level a trapezoidal resection of its area was performed. First, we made perforations of the bone with a drill at two levels and removed the central part with Liston or Luer nippers. The wound was sewn up.

The second dissection, 5–6 cm long, was performed along the anterior outer surface of the tibia at the level of the tuberosity and below. Its outer surface was isolated subosseously and a wedge-shaped osteotomy was made with the help of a pendulum saw and a chisel. The height of the base was calculated the day before according to radiographs. It is not necessary that the top of the wedge reaches the inner cortical layer. It is important that the planes of the sections are even and in close contact after correction of the deformation. It should be warned that it is undesirable to remove a wedge larger than what is needed to achieve a slight valgus of 5°–8°. The presence of diastasis between the fragments on the outer surface requires an increase in the terms of their fixation by the apparatus. It is better when the wedge is smaller than necessary, while additional correction can be made with the device in the postoperative period. In the presence of a flexion contracture, the limb was corrected also in the sagittal plane. After performing osteotomies and correcting the deformity, the fragments were fixed with a rod device, just as in the case of an opening osteotomy.

The next day after the operation, the patients began to stand and walk with a dosed load on the operated limb, using crutches. The magnitude of the load was dosed according to the pain symptom. During the first weeks, it is very important to evaluate the cosmetic functional result of the correction, focusing on the axis of the limb during support and the subjective feelings of the patient regarding its bearing capacity and pain sensations. In the postoperative period, some patients underwent additional correction of the angular relationships between the fragments, focusing on clinical and radiological indicators and on the patient's feelings and wishes.

X-ray control to study the condition of the regenerate at the osteotomy site was performed within 2–2.5 months after surgery. Usually, during this term, patients were already walking with full support on the operated limb, but using crutches. The external fixation device was removed when it was possible to walk with full weight on the operated limb and X-ray signs of bone regeneration between the fragments. In doubtful cases, a clinical trial was conducted within 2 weeks.

Treatment results

On the 2nd–3rd day after the operation, the patients began to walk with a dosed support on the operated limb. Patients who underwent partial or pericapsular resection of the meniscus noted the disappearance of pain that existed before the operation. We can confidently state that all patients tolerated fixation with an external device without any particular problems and maintained motor activity. In 1.5–2.5 months they already walked with full support on the operated limb, using one crutch or stick. The bearing capacity of the limb was previously restored after the opening osteotomy due to the preservation of the integrity of the fibula. The term of fixation of the tibia with the device is as follows: up to 4 months in 36 patients, up to 5 months in 7, 6 in 2. In the latter two patients, the long term was associated with the absence of bone regenerate between the fragments on the inner part after the opening osteotomy.

In the course of treatment and in the near future after removal of the device, patients developed the following complications that did not require surgical intervention: long-term (for 10–15 days) swelling of the lower leg with pain syndrome in 2 cases; inflammation of soft tissues around one rod in 5 cases (10 %).

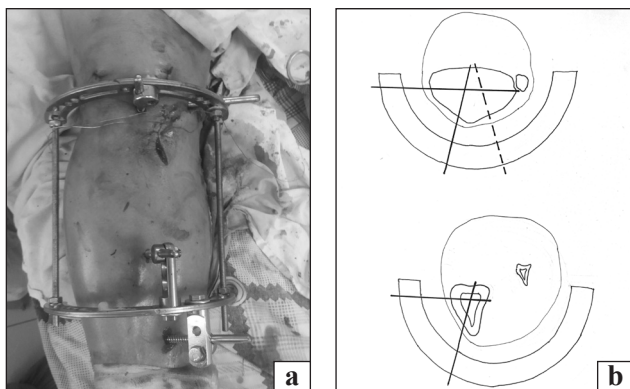


Fig. 4. View of the limb with the apparatus after the opening devarising osteotomy intervention (a) and the layout of the rods in horizontal planes (b)

In one patient, bony union did not occur after the opening osteotomy, although the correct axis of the limb was preserved. The main symptom was pain at the osteotomy site when walking. The patient underwent repeated surgical intervention in the form of resection of the area of the fibula and fixation of the fragments with a rod device in the position of slight valgus hypercorrection. In 2 months of the use of the device the union occurred.

A 72-year-old female patient with type 2 diabetes mellitus developed acute sepsis in the surgical area during the fourth month of treatment, and she died 3 weeks later.

The course of gonarthrosis after surgery. Among 45 patients, a long-term positive clinical effect was obtained in 42, which was 93%. For 3–8 years after the operation, the patients did not contact us regarding the deterioration of the condition of the operated limb. Three subjects in 8 and 18 months continued to suffer from pain and limitation of movements, requiring endoprosthesis repair of this joint. Three patients within 1–1.5 years after surgery on one joint contacted us for the same intervention on another.

Conclusions

On the basis of experience and obtained results of treatment, we state that the indications for certain surgical intervention should be based, first of all, on the identification of the source (or pathogenesis) of the pain syndrome, then on the presence of periarticular angular deformation of the limb and its type, size, as well as signs of functional insufficiency of the limb associated with it. And only in the third place, such X-ray signs as narrowing of the joint space, subchondral sclerosis and deformations of the joint surfaces should be analyzed. The idea that the pain is directly related to the degeneration and thinning of the hyaline cartilage may be wrong.

Most often, pain in conditions of gonarthrosis is associated with chronic blocking of the joint changed in volume and mechanical properties of the meniscus due to its degeneration. This can be considered as the beginning of gonarthrosis, followed by degeneration of articular cartilage. Pathological changes of the meniscus can be detected clinically by checking Baikov symptom, as well as with the help of ultrasonography. Pericapsular removal of the pathologically changed part of the meniscus gives a positive effect.

Elimination of angular periarticular deformation of the limb has a positive effect on the course of gonarthrosis, reduces pain, increases physical activity and slows down the progression of cartilage destruction.

The use of an external rod apparatus developed by us makes it possible to perform osteotomies of the proximal part of the tibia with minimal surgical access, and if necessary, angular correction of the axis of the limb in the postoperative period, when the patient begins to walk with partial support. The functional load of the affected limb makes it possible to achieve fusion of the fragments within 3.5–4 months.

Conflict of interest. The authors declare no conflict of interest.

References

1. Global, regional prevalence, incidence and risk factors of knee osteoarthritis in population-based studies / A. Cui, H. Li, D. Wang [et al.] // *EclinicalMedicine*. — 2020. — P. 29–30. — DOI: 10.1016/j.eclinm.2020.100587.
2. Osteoarthritis: a disease of the joint as an organ / R. F. Loeser, S. R. Goldring, C. R. Scanzello, M. B. Goldring // *Arthritis and rheumatism*. — 2012. — Vol. 64(6). — P. 1697–1707. — DOI: org/10.1002/art.34453.
3. Vina E. R. Epidemiology of osteoarthritis: literature update / E. R. Vina, C. K. Kwok // *Current opinion in rheumatology*. — 2018. — Vol. 30 (2). — P. 160–167. — DOI: 10.1097/BOR.0000000000000479.
4. Increases in the rates of primary and revision knee replacement are reducing: a 15-year registry study across 3 continents / P. L. Lewis, S. E. Graves, O. Robertsson [et al.] // *Acta Orthopaedica*. — 2020. — Vol. 91 (4). — P. 414–419. — DOI: 10.1080/17453674.2020.1749380.
5. Dealing with the predicted increase in demand for revision total knee arthroplasty: challenges, risks and opportunities / D. F. Hamilton, C. R. Howie, R. Burnett [et al.] // *The Bone & Joint Journal*. — 2015. — Vol. 97-B (6). — P. 723–728. — DOI: 10.1302/0301-620X.97B6.35185.
6. The epidemiology of revision total knee and hip arthroplasty in England and Wales: a comparative analysis with projections for the United States. A study using the National Joint Registry dataset / A. Patel, G. Pavlou, R. E. Mújica-Mota, A. D. Toms // *The Bone & Joint Journal*. — 2015. — Vol. 97-B (8). — P. 1076–1081. — DOI: 10.1302/0301-620X.97B8.35170.
7. Osadchuk T. I. Gonarthrosis: prevalence and differential approach to endoprosthesis [Honartroz: poshyrenist' ta dyferentsiyunny pidkhid do endoprotezuvannya] / T. I. Osadchuk, A. V. Kalashnikov, O. V. Khyts // *Український Медичний Часопис*. — 2021. — Vol. 6 (146) – XI/XII. — P. 80–84. — DOI: 10.32471/umj.1680-3051.146.222998. (in Ukrainian)
8. Total knee arthroplasty in patients less than 50 years of age: results at a mean of 13 years / V. Karas, T. E. Calkins, A. J. Bryan [et al.] // *The Journal of Arthroplasty*. — 2019. — Vol. 34 (10). — P. 2392–2397. DOI: 10.1016/j.arth.2019.05.018.
9. The joints [Sustav] / V. N. Pavlova, G. G. Pavlov, N. A. Shostak, L. I. Slutskiy. — Moscow : Meditsinskoye informatsionnoye agentstvo, 2011. — C. 43–44. (in russian)
10. Orlyansky V. Osteotomy in the area of the knee joint [Osteotomii v oblasti kolennogo sustava] / V. Orlyansky, M. L. Golovakha. — Zaporizhzhia, 2020. — 321 p. (in russian)
11. Krupko I. L. Internal injuries of the knee joint [Vnutrenniye povrezhdeniya kolennogo sustava] / I. L. Krupko // *Orthopaedics, Traumatology and Prosthetics*. — 1964. — No 2. — C. 3–14. (in russian)
12. Yanson Kh. A. Biomechanics of the human lower limb [Biomehanika nizhney konechnosti cheloveka] / Kh. A. Yanson. — Riga, 1975. (in russian)
13. Korzh N. A. Osteoarthritis: conservative therapy [Osteoartroz: konservativnaya terapiya] / N. A. Korzh, N. V. Dedukh, I. A. Zupanets. — Kharkiv : Gold pages, 2007. — P. 14–43. (in russian)
14. State registration certificate 10276/211 "Rod devices for connecting bone fragments in the treatment of limb fractures" TU.U 33.1-35700506-001:2011. According to the order of the State Medical Inspectorate of the Ministry of Health of Ukraine from 15.03.2011 [Svidotstvo pro derzhavnu reyestratsiyu 10276/211 «Prystroyi stryzhnevi dlya z'yednannya kistkovykh vidlamkiv pry likuvanni perelomiv kintsivok» TU.U 33.1-35700506-001:2011. Zhidno z nakazom Derzhlikinspektsiyi MOZ Ukrayiny vid 15.03.2011]. (in Ukrainian)

The article has been sent to the editors 17.10.2022

RECONSTRUCTIVE SURGERIES IN THE CASE OF THE KNEE JOINT OSTEOARTHRITIS

O. K. Popsuishapka¹, V. O. Lytvynshko^{2,4}, O. O. Pidgaiska³,
N. O. Ashukina³, K. K. Romanenko¹, Z. M. Danyshchuk³

¹ Kharkiv Medical Academy of Postgraduate Education. Ukraine

² Kharkiv National Medical University. Ukraine

³ Sytenko Institute of Spine and Joint Pathology National Academy of Medical Sciences of Ukraine, Kharkiv

⁴ CHI «Kononenko Chuguyev Central District Hospital», Kharkiv region. Ukraine

✉ Olexii Popsuishapka, MD, Prof. in Traumatology and Orthopaedics: alexecorn@gmail.com

✉ Valerii Lytvynshko, MD, DMSci in Traumatology and Orthopaedics: lvaort@yandex.ua

✉ Olga Pidgaiska, PhD in Traumatology and Orthopaedics: podgayo@yahoo.com

✉ Nataliya Ashukina, PhD in Biol. Sci.: natalya.ashukina@gmail.com

✉ Kostiantyn Romanenko, MD, PhD in Traumatology and Orthopaedics: romanen_kost@yahoo.com

✉ Zinaida Danyshchuk, MD: zinada1962@gmail.com