

УДК 617.572:616.717.4-007.234-001.5](045)

DOI: <http://dx.doi.org/10.15674/0030-598720223-413-21>

Results of a differential approach to surgical treatment of proximal humerus fractures in patients with osteoporosis

M. O. Korzh¹, V. B. Makarov², I. G. Gupalov²,
O. M. Pertseva², K. P. Boyko², O. O. Pidgaiska¹

¹ Sytenko Institute of Spine and Joint Pathology National Academy of Medical Sciences of Ukraine, Kharkiv

² Municipal non-profit enterprise «City Clinical Hospital № 16» of the Dnipro City Council. Ukraine

Objective. To conduct a comparative retrospective analysis of the anatomical and functional results of surgical treatment of proximal humerus fractures AO/OTA 11-B, 11-C using different methods in patients over 50 years old with osteoporosis to justify a differential approach. *Methods.* The study included 102 patients aged 50 years and older with osteoporosis and proximal humerus fractures AO/OTA 11-B, 11-C. The patients were divided into three groups: I — 50 (16 men, 34 women) whom were performed open reduction and internal fixation (ORIF) with the PHILOS plate; II — 44 (8 men, 36 women) — ORIF with the PHILOS plate and using 3D polylactide (PLA) porous implants were applied; III — 8 (2 men, 6 women) whom were performed primary reversed total shoulder arthroplasty (RTSA) with developed total reversible endoprosthesis. The results of treatment were evaluated according to the Constant-Murley Shoulder Score system after 3, 6, 12 months. *The results.* Positive results in the first group were obtained in 72.0 % of patients (the average Constant-Murley Shoulder Score after 12 months was 78.4 points); in the second — in 81.8 % (88.0 points); in the third — 75.0 % (82.0 points). A differentiated approach to the choice of surgical treatment of patients aged 50 years and older with fractures AO/OTA 11-B, 11-C is proposed. The clinical trial of the reverse total modular shoulder endoprosthesis developed by us using porous 3D titanium parts, manufactured by additive technologies, showed positive short-term results. The design features of the device increase the reliability and durability of proposed endoprosthesis. *Conclusions.* RTSA in the case of unstable proximal humerus fracture or in the case of metal structure migration after primary ORIF in patients with low bone mineral density is the effective surgical intervention that allows to achieve satisfactory functional results in up to 3 years.

Мета. Провести порівняльний ретроспективний аналіз анатомо-функціональних результатів хірургічного лікування переломів проксимального відділу плечової кістки (ППВПК) типів AO/OTA 11-B, 11-C із використанням різних методів у пацієнтів старших за 50 років із остеопорозом для обґрунтування диференційного підходу. *Методи.* У дослідження включено 102 пацієнти віком 50 років і старше з остеопорозом і трити чотирифразментарними ППВПК за класифікацією Neer або типу AO/OTA 11-B, 11-C. Хворих розподілили на три групи: I — 50 (16 чоловіків, 34 жінки), виконано відкриту репозицію, накістковий металоостеосинтез пластиною PHILOS; II — 44 (8 чоловіків, 36 жінок), застосовано відкриту репозицію та накістковий металоостеосинтез пластиною PHILOS із використанням 3D-імплантатів PLA; III — 8 (2 чоловіки, 6 жінок), первинне RTSA розробленим тотальним реверсивним ендопротезом. *Результати лікування* оцінювали за системою Constant-Murley Shoulder Score через 3, 6, 12 міс. після хірургічного втручання. *Результати.* Позитивні результати в I групі отримані в 72,0 % пацієнтів (середня оцінка за Constant-Murley Shoulder Score через 12 міс. склала 78,4 бала); у II — у 81,8 % (88,0 балів); III — 75,0 % (82,0 бала). Запропоновано диференційований підхід до вибору хірургічного лікування пацієнтів віком 50 років і старше з переломами типу AO/OTA 11-B, 11-C. Клінічна апробація розробленого нами реверсивного модульного ендопротеза плечового суглоба з пористого 3D-титану, виготовленого за допомогою адитивних технологій, показала позитивні найближчі результати. Конструктивні особливості пристрою підвищують надійність і довговічність його роботи. *Висновки.* Тотальне реверсивне ендопротезування плечового суглоба в разі незрслх ППВПК, міграції металоконструкції, розвитку аваскулярного некрозу головки плечової кістки на фоні низької мінеральної щільності кістки є ефективним хірургічним втручанням, яке дає змогу досягти задовільних функціональних результатів у термін до 3 років. *Ключові слова.* Перелом проксимального відділу плечової кістки, пластини з кутовою стабільністю PHILOS, 3D-імплантат, полілактид, пористий титан, DLC-покриття, PEEK, реверсивний ендопротез плечового суглоба, остеопороз.

Key words. Proximal humerus fracture, PHILOS, 3D-implant, polylactide, PLA, porous Titanium, DLC Coating, PEEK, reverse shoulder total arthroplasty, osteoporosis

Introduction

Proximal humerus fractures (PHF) make up 5–6 % of injuries of the musculoskeletal system [1–3]. It is known that 80 % of AO/OTA A2/A3 type PHF are stable, and conservative treatment in such cases results in good functional outcomes [4–5]. But in unstable three- and four-fragment PHF according to Neer or type AO/OTA 11-B, 11-C this can be achieved only with the help of surgical intervention [4–6]. For patients with osteoporosis, there are no standards for the selection of surgical treatment methods in types B and C PHF, and the issue remains debatable. The main types of surgical intervention for them are open reduction and internal fixation (ORIF) using various plates with angular stability and the mandatory use of various auto- or allografts, bone cement [7–13], including structural porous implants made of polylactide (PLA) [14–16]. Hemiarthroplasty of the shoulder joint for three- and four-fragment PHF is now used much less often compared to reverse total shoulder arthroplasty (RTSA). This is due to a significant number of unsatisfactory results and complications [17–19]. In recent years, RTSA of the shoulder joint, proposed by Grammont [20–21], is the main method of surgical treatment in patients with types AO/OTA 11-B, 11-C PHF secondary to osteoporosis [22–25]. However, there are few studies comparing the clinical results of RTSA and ORIF in patients with type B and C proximal humeral fractures (AO/OTA).

The purpose of the study: to conduct a comparative retrospective assessment of the anatomical and functional results of surgical treatment of types AO/OTA 11-B, 11-C fractures of the proximal humerus using different methods in patients over 50 with osteoporosis to substantiate a differential approach.

Material and methods

The research materials were reviewed and approved by the Bioethics Committee at the State Institution Professor M. I. Sytenko Institute of Spine and Joint Pathology of the National Academy of Medical Sciences of Ukraine (Protocol No. 191 of 22.04.2019). All patients involved in the study were familiarized with the plan of surgical interventions and signed the informed consent.

The study involved evaluation of anatomical and functional results of surgical treatment of 102 patients aged 50 years and older with osteoporosis and three- and four-fragmented PHF according to the Neer classification [26] or AO/OTA types 11-B, 11-C [27]. Patients were divided into three groups:

– Group I — 50 individuals (16 men, 34 women, from 50 to 76 years old). In the period 2009–2022, open reduction, osseous metal-osteosynthesis with the PHILOS plate was performed. 32 patients had a three-fragment fracture according to the Neer classification (AO/OTA 11-B), 18 had a four-fragment fracture (AO/OTA 11-C). 4 subjects underwent RTSA (UNIC, Evolutis, France) within 6 to 12 months after primary surgical intervention due to an unfavorable result of ORIF (lack of consolidation signs, migration of the metal structure with the development of avascular necrosis of the humeral head) [28];

– II — 44 individuals with osteoporosis (8 men, 36 women, from 50 to 78 years old). In 2015–2022, open reduction and osseous metal-osteosynthesis with the PHILOS plate using 3D PLA implants were performed [14, 15, 29]. 32 patients were diagnosed with a three-fragment fracture according to the Neer classification (AO/OTA 11-B), 6 patients had a four-fragment fracture (AO/OTA 11-C);

– III — 8 individuals with osteoporosis (2 men, 6 women, from 50 to 76 years old) in the period from 2020 to 2022 underwent primary RTSA with the elaborated total reversible endoprosthesis [30]. In all cases, the indication for RTSA was fractures of type AO/OTA 11-B (2 subjects) or AO/OTA 11-C (6 subjects) secondary to severe osteoporosis.

In the pre- and postoperative period, all patients underwent a standard clinical examination and radiography. Spiral computed tomography was performed in some cases in multifragmentary fracture-dislocations to determine the defect of the articular surface. The severity of osteoporosis was assessed by X-rays of the humerus in the anterior-posterior projection with the calculation of the cortical index (CI) [31, 32].

Radiographic standard examination of the proximal part of the humerus in 2 projections was performed in 1, 3, 6, 12 months. The results of treatment were evaluated according to the Constant-Murley Shoulder Score system within 3, 6, 12 months after surgery [33].

Operations were performed in the «beach chair» position under general anesthesia and nerve block. Intraoperative X-ray control was provided using C-arm.

Deltopectoral access was performed in 85 patients, anterolateral one in 23.

In Group II patients, two porous 3D PLA implants with a diameter of 8 or 10 mm and a length of 20 to 45 mm were mostly used. In the case of severe osteoporosis ($CI \leq 0.29$) [31, 32] and a large diameter of the humeral canal (more than 15 mm), a third PLA 3D implant with a diameter of 12–15 mm was previously installed in the canal as a support for the other

two. In some cases, in a significant post-traumatic defect of the cancellous tissue of the humeral head, the space between the 3D PLA implants was additionally filled with allobone, a cortical-spongy granulate OMS-A-KGG produced at the State Institution Professor M. I. Sytenko Institute of Spine and Joint Pathology of the National Academy of Medical Sciences of Ukraine.

In primary or revision RTSA, a standard deltopectoral access was used. Immobilization in a Dezo bandage lasted 4–6 weeks with the possibility of oscillating and pendulum movements in the shoulder and elbow joints with a small amplitude of 10–20°. Vacuum drainage was left for 24–48 hours. Active movements in the elbow joint were allowed on the 2nd to 3rd day after surgery, passive movements in the shoulder joint on the 3rd to 5th day. Active movements in the shoulder joint were usually allowed 4 weeks after the operation and in significant post-traumatic defects of the humeral head and severe osteoporosis ($CI \leq 0.29$) in 6 weeks.

Group III patients underwent surgical intervention using the elaborated reversible total modular endoprosthesis of the shoulder joint [30]. The following tasks were set while improving the design of the endoprosthesis: to upgrade the stability of fixation in the bone; to enhance the durability of the device; to increase the life of the friction pair to prevent the pos-

sible development of aseptic instability due to wear of the polyethylene liner.

The use of additive technologies makes it possible to print parts of endoprostheses of complex geometric shapes with the required porosity. In the proprietary endoprosthesis, the glenoid support plate, printed on a 3D printer from titanium powder (similar to VT-5), has a central rod covered with conical ribs and pores with a pore rib length of 350–500 µm. The surface of the glenoid component is also completely porous (pore edge length 350–500 µm) to a depth of 2 mm. The outer surface of the glenoid support plate is made in the form of a Morse cone for the fitting of the glenoid head, which also has a Morse cone surface on the inner side (Figs. 1, 2).

The proposed endoprosthesis contains a glenoid head (hemisphere) made of a titanium alloy covered with a diamond-like coating (Fig. 2) or made of polyether ether ketone (PEEK). It is fixed to the glenoid support plate with a screw through the central hole. Coating of the external friction surfaces of the glenoid head with a diamond-like carbon coating from a filtered vacuum-arc cathode plasma with the application of high-voltage pulse potentials of negative shear to the deposited surfaces ensure high adhesion of these coatings to the surfaces, a low level of internal stresses against the background of ensuring a high hardness of not less than 40 GPa and a low

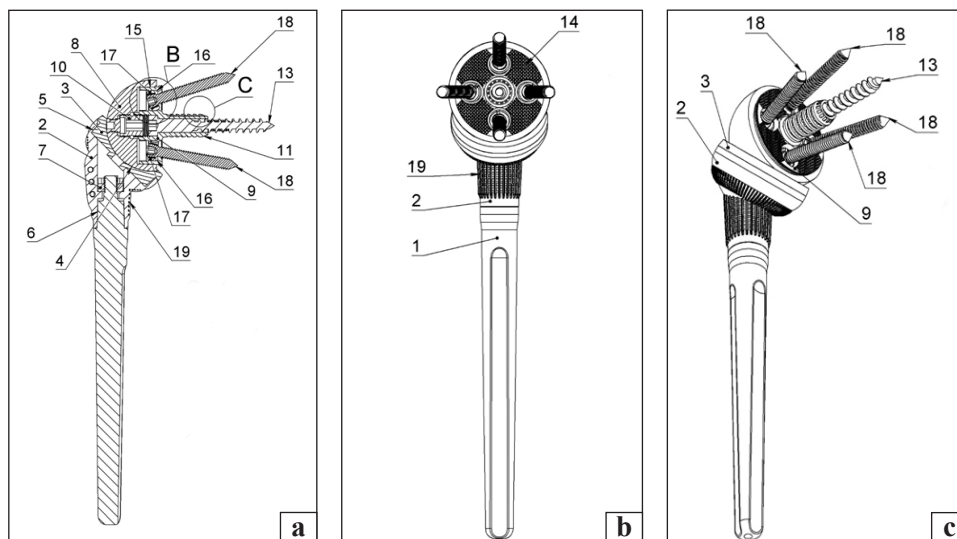


Fig. 1. Reversible modular endoprosthesis of the shoulder joint: 1 — a leg made in the form of a conical three-lobed rod; 2 — porous proximal part, printed on a 3D printer from titanium powder (similar to VT-5); 3 — an PEEK insert in the form of a conical cylinder; 4 — concave spherical surface of the liner; 5 — Morse cone; 6 — the proximal part of the endoprosthesis is fixed using a Morse cone to the proximal part of the leg; 7 — locking nut; 8 — glenoid head; 9 — glenoid support plate; 9 — the outer edge of the support plate, made in the form of a Morse cone; 10 — fixing screw; 11 — central rod; 12 — cone-shaped ribs with a pore rib length of 350–500 µm; 13 — central screw; 14 — the porous surface of the glenoid support plate with a pore edge length of 350–500 µm to a depth of 2 mm; 15 — the outer surface of the glenoid support plate in the form of a Morse cone; 16 — spherical holes of the glenoid support; 17 — spherical washers; 18 — screws; 19 — proximal part with ribbed porous outer surface [30]; a) appearance; b) frontal projection; c) side view




Fig. 2. Appearance of the reversible modular endoprosthesis of the shoulder joint: a) glenoid support plate; b) porous proximal part; c) glenoid head

coefficient friction ~ 0.1 [34, 35]. When this coating slides over the titanium nitride coating, the coefficient of friction between them decreases several times and becomes less than 0.1. The thickness of protective coatings, made of diamond-like carbon coating is not less than $1.5 \mu\text{m}$, provides not only reliable protection of the metal surface from electrochemical corrosion, but also a sufficiently high service life due to a significant reduction in the coefficient of friction of these surfaces during their mutual sliding.

Results and their discussion

Results of treatment of Group I patients according to the Constant-Murley Shoulder Score system 3, 6, 12 months after the operation averaged 71.3; 76.6; 78.4 points respectively. In 3 patients, varus migration of the head occurred without significant impairment of the function of the shoulder joint, in 2 patients complete destabilization of the metal structure occurred, resulting in its removal 3 months after surgery. In 5 operated patients, a secondary displacement of the greater tubercle occurred up to 10–15 mm one month after surgery. Avascular necrosis of the head of the humerus was determined in 4 patients within 6 to 12 months, resulting in the removal of metal structures and implementation of RTSA [28]. The conducted evaluation showed that the use of PHILOS plates made it possible to obtain positive results (excellent and good) in 36 Group I patients (72.0 %) within 6 to 12 months after surgery, 8 (16.0 %) were satisfactory, 6 (12.0 %) were unsatisfactory.

In Group II patients the average indicator according to the Constant-Murley Shoulder Score system within 3 months after the operation was an average of 78.0 points, 81.8 points within 6 months and 88.0 points within 12 months. Fragment consolidation was achieved in all patients. No signs of avascular necrosis of the humeral head were observed. One woman experienced perforation of a fragment of the head with a screw 6 weeks after surgery, which was removed under C-arm control through a skin puncture under local anesthesia [28]. 2 patients deve-

veloped a superficial infection, which was eliminated by local and systemic antibacterial therapy. One patient in 3 months was found to have a secondary displacement of the lesser tubercle up to 8–10 mm, 8 subjects had a varus displacement up to 5 mm without functional impairment. In all patients of this group, a plate of the PHILOS type, 2–3 PLA implants were used, and in 14, cortical-spongy granulate OMS-A-KGG was additionally employed. The conducted analysis showed that the use of PHILOS plates using additional reinforcement with 3D PLA implants allowed to obtain positive results (excellent and good) in 36 (81.8 %) patients, satisfactory results in 8 (18.2 %) and to reduce the number of complications (88.0 points by the Constant-Murley Shoulder Score) within 6 to 12 months after surgery.

Clinical example No. 1

Patient G., born in 1963, was hospitalized to the Department of Polytrauma, Endoprosthetics and Rehabilitation of the Medical Center City Clinical Hospital No. 16 of Dnipro City Council on 28.02.2022 with the diagnosis: closed craniocerebral injury, concussion, intra-articular fragment fracture of the proximal part of the left humerus (AO/ OTA 11C21) (Fig. 3). On 01.03.2022 an open reposition under general anesthesia was performed followed by nerve block using osseous metal-osteosynthesis with the PHILOS plate and two porous 3D PLA implants. She was immobilized with a Dezo type bandage for 4 weeks. Active movements in the left elbow joint were allowed on the 2nd day after surgery, passive movements in the shoulder joint under the control of a physical therapy instructor in the first week after surgery, and active movements in 4 weeks. The function of the right shoulder joint was restored according to the Constant-Murley system 78 points within 3 months, 85 points within 6 months (Fig. 4).

In Group III patients the average score according to the Constant-Murley Shoulder Score system within 3 months after the operation was 76 points, 80 points within 6 months, 82 points within 12 months. Restoration of the shoulder joint function was achieved

in all of them in the absence of signs of instability of the endoprosthesis components. One patient developed neuropathy of the radial nerve, the function of which was restored in 3 months following neurotropic therapy. In the period from 6 to 12 months after surgery, 6 patients (75 %) had good results, 2 (25 %) had satisfactory results.

Clinical example No. 2

Patient O., born in 1962, was admitted to the Department of Polytrauma, Endoprosthetics and Rehabilitation of the Medical Center City Clinical Hospital No. 16 of Dnipro City Council on 15.12.2021 with a diagnosis of chronic fracture, fragment fracture of the right proximal humerus (AO/OTA 11C21) (domestic injury of 04.11. 2021), pronounced pain syndrome, absence of abduction function and flexion of the right upper limb in the shoulder joint. On 16.12.2021, an operation under general anesthesia was performed followed by nerve block: total cementless endoprosthetic repair of the right shoulder joint with an elaborated modular reversible endoprosthesis (Figs. 5, 6).

Patient O. was immobilized with a Dezo bandage for 4 weeks. She began active movements in the right elbow joint on the 3rd day after the operation, pas-

sive movements in the shoulder joint under the control of a physical therapy instructor on the 4th week, and active movements in 6 weeks. The function of the right shoulder joint was restored according to the Constant-Murley system: 75 points within 3 months, 78 points within 6 months, 80 points within 12 months (Fig. 7).

Discussion

PHF makes up almost 30 % of all fractures in the elderly. Due to the aging of the population, the incidence of these fractures will continue to increase [36]. Although the majority of such injuries are treated conservatively, some patients with type AO/OTA 11-B, 11-C fractures are recommended surgical treatment. However, debate continues regarding its indications and ideal strategy. The Section of Skeletal Trauma and Sports Injuries of the European Society of Traumatology and Emergency Surgery (ESTES) appointed a working group to reach a consensus among European countries on PHF management. The recommendations compare conservative and four possible options for surgical treatment — ORIF, intramedullary blocked osteosynthesis, hemi- and total reversible endoprosthesis [37]. People over 50 with osteoporosis are recommended to undergo either

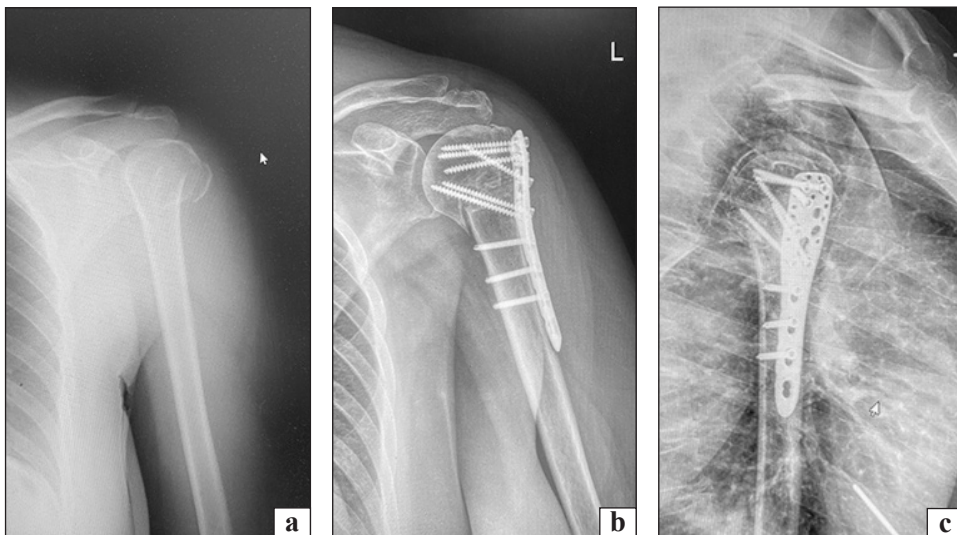


Fig. 3. X-rays of patient G.: a) AO/OTA 11C21 (injury of 24.02.2022); b, c) within 6 months after surgery



Fig. 4. Photo of patient G. within 6 months after ORIF. Functional result

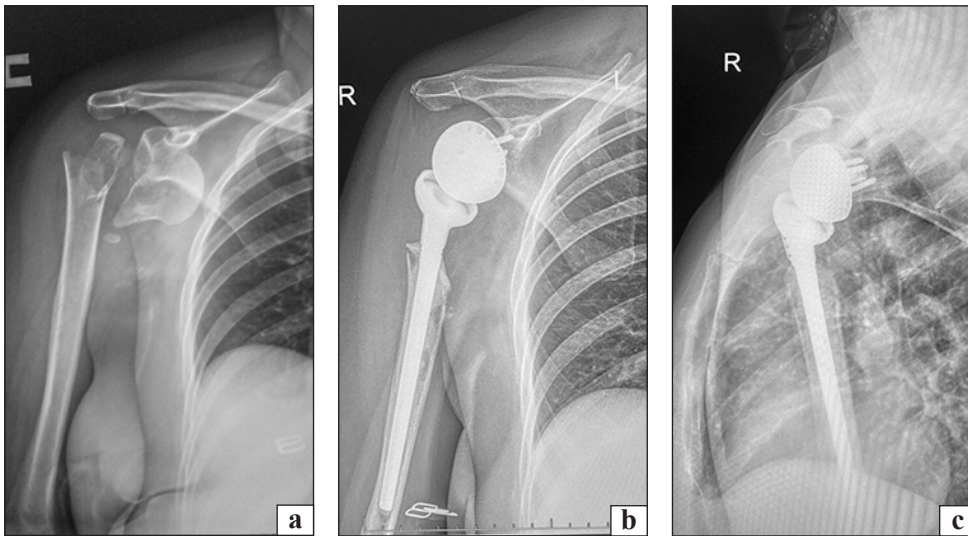


Fig. 5. X-rays of patient O.: a) AO/OTA 11C21 (domestic injury of 04.11.2021); b, c) after total hybrid endoprosthetic repair of the right shoulder joint with a developed modular reversible endoprosthesis (operation of 16.12.2021)

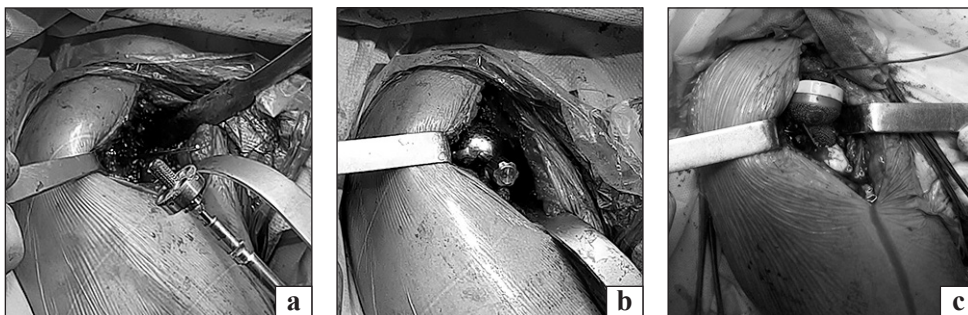


Fig. 6. Stages of surgical intervention: a) implantation of a cementless glenoid support plate; b) fixation of the glenoid head to the support plate; c) implantation of a cement leg with a proximal porous part and an insert

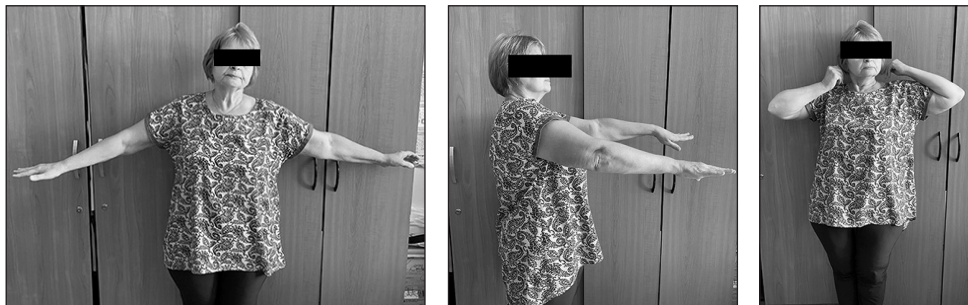


Fig. 7. Photo of patient O.: functional result in 12 months

hemiarthroplasty or RSTA due to the impossibility of osteosynthesis. Hemiarthroplasty has been shown to result in worse functional outcomes compared to RTSA. Secondary RTSA after other surgical treatment also results in outcomes comparable to primary RTSA [37].

A retrospective assessment of the treatment outcomes of patients who underwent shoulder arthroplasty due to PHF from 2010 to 2019 showed no significant differences in the function of the shoulder joint after RTSA and hemiarthroplasty. The authors concluded that this could be explained by the restrictive indications for hemiarthroplasty [38]. In another retrospective study [39] of the results of treatment of patients with PHF from 2010 to 2017, the authors

differentially analyzed osteosynthesis or endoprosthetic repair. Osteosynthesis of type AO/OTA 11-B, 11-C fractures was carried out when technically possible. Either a deltopectoral access or minimally invasive plate osteosynthesis (MIPO) was used. Hemiarthroplasty was used if it was possible to reconstruct the tubercles and there were no signs of osteoarthritis. In all other cases, RTSA was performed. The authors believe that both osteosynthesis and primary arthroplasty can lead to a good or even excellent functional result, noting a high frequency of revisions after osteosynthesis. Revision procedures, which involve endoprosthetic repair after failed osteosynthesis, provide much lower functional results [39]. Thus, it has been proven that surgical treatment of PHF in the elderly

and senile secondary to osteoporosis creates problems for decision-making regarding the choice of a surgical intervention method.

The use of RTSA has led to a paradigm shift in the treatment of PHF in the elderly. The unique biomechanical principles and design features of RTSA make it a suitable treatment option for PHF in the elderly with osteoporosis and tubercle defects. The method is considered a reliable approach after failed hemiarthroplasty or failed ORIF [40]. RTSA has clear advantages over hemiarthroplasty and internal fixation, providing pain relief and reliable recovery or significant improvement in functional outcomes. As a result, an increase in the number of RTSAs in elderly patients has been observed over the last decade [41].

Our evaluation of surgical treatment of patients with PHF over 50 showed that the use of 3D PLA implants as a reinforcing material during ORIF results in positive outcomes with a minimum number of complications in the majority of patients. In an unfavorable result of ORIF, repeated intervention involves revision, removal of metal structures, arthrolysis and reversible total endoprosthetic repair of the shoulder joint. Our experience proves that the initial use of RTSA in chronic type AO/OTA 11-B, 11-C fracture-dislocations and the technical impossibility of conducting ORIF results in positive outcomes up to 3 years after the operation.

Thus, on the basis of a retrospective assessment of our own results and special literature, we offer a differentiated approach to the selection of surgical treatment for patients aged 50 years and older with type AO/OTA 11-B, 11-C fractures:

1. In the absence of expressed osteoporosis according to densitometry data (or $CI = 0.4-0.5$), ORIF is justified and necessary.

2. In expressed osteoporosis ($CI < 0.4$), ORIF is possible, but with the mandatory use of allo- and autografts or bone cement.

3. Severe osteoporosis ($CI < 0.4$) and technical impossibility of conducting a stable ORIF require primary reversible total endoprosthetic repair.

Conclusions

Positive results of open repositioning and osseous fixation of PHF with PHILOS type plates in patients over 50 with osteoporosis were obtained in 72 % of cases, satisfactory in 16 and unsatisfactory in 12 %. Average Constant-Murley Shoulder Score was 78.4 points within 12 months.

The use of PHILOS plates for osteosynthesis of PHF with additional reinforcement using the elabo-

rated porous 3D polylactide implants in patients with osteoporosis allowed to obtain positive results (excellent and good) in 81.8 % of cases, satisfactory in 18.2 %, and to reduce the number of complications within 6 to 12 months after the operation. The average Constant-Murley Shoulder Score was 88 points.

In all Group III patients, restoration of the function of the shoulder joint was achieved in the absence of signs of instability of the endoprosthesis components. In the period from 6 to 12 months after the operation, 6 (75 %) patients had good results, 2 (25 %) had satisfactory results. The outcome reached 82 points according to Constant-Murley Shoulder Score.

Total reversible endoprosthetic repair of the shoulder joint is an effective surgical intervention in case of nonunion PHF, migration of the metal structure, development of avascular necrosis of the humeral head secondary to low bone mineral density, damage to the rotator cuff or muscle hypotrophy, allowing to achieve satisfactory functional results in up to 3 years.

The clinical trial of our proposed reversible modular endoprosthesis of the shoulder joint from porous 3D titanium, manufactured using additive technologies, showed positive near-term results. Design features of the proposed reversible endoprosthesis will increase the reliability and duration of its work with improved functional and clinical properties.

The proposed differentiated approach to choosing a treatment method for patients with PHF aged 50 years and older according to the type of fracture according to the AO/OTA classification and osteoporosis results in mostly positive anatomical and functional outcomes and prevention of the negative consequences of surgical treatment.

Conflict of interest. The authors declare no conflict of interest.

References

1. Outcomes for type C proximal humerus fractures in the adult population: comparison of nonoperative treatment, locked plate fixation, and reverse shoulder arthroplasty / S. A. Samborski, B. E. Haws, S. Karnyski [et al.] // *JSES International*. — 2022. — Vol. 6 (5). — P. 755–762. — DOI: 10.1016/j.jseint.2022.05.006.
2. Proximal humeral fractures in Sweden—a registry-based study / B. O. Sumrein, T. T. Huttunen, A. P. Launonen [et al.] // *Osteoporosis International*. — 2017. — Vol. 28 (3). — P. 901–907. — DOI: 10.1007/s00198-016-3808-z.
3. How age and gender influence proximal humerus fracture management in patients older than fifty years / A. H. Patel, J. H. Wilder, S. A. Ofa [et al.] // *JSES International*. — 2021. — Vol. 6 (2). — P. 253–258. — DOI: 10.1016/j.jseint.2021.11.007.
4. Nationwide trends in management of proximal humeral fractures: an analysis of 77,966 cases from 2008 to 2017 / A. S. McLean, N. Price, S. Graves [et al.] // *Journal of Shoulder and Elbow Surgery*. — 2019. — Vol. 28 (11). — P. 2072–2078. — DOI: 10.1016/j.jse.2019.03.034.
5. Operative treatment of proximal humeral fractures with reverse total shoulder arthroplasty in patients ≥ 65 years old:

- a critical analysis review / C. C. Lin, E. Karlin, M. A. Boin [et al.] // *JBJS Rev.* — 2022. — Vol. 10 (5). — DOI: 10.2106/JBJS.RVW.21.00245.
6. Trends in surgical management of proximal humeral fractures in adults: a nationwide study of records in Germany from 2007 to 2016 / A. Klug, Y. Gramlich, D. Wincheringer [et al.] // *Archives of Orthopaedic and Trauma Surgery.* — 2019. — Vol. 139 (12). — P. 1713–1721. — DOI: 10.1007/s00402-019-03252-1.
 7. Treatment of proximal humeral fractures - a review of current concepts enlightened by basic principles / D. Maier, M. Jäger, P. C. Strohm, N. P. Sudkamp // *Acta Chirurgiae orthopaedicae et Traumatologiae Cechoslovaca.* — 2012. — Vol. 79 (4). — P. 307–316.
 8. Jo Y. H. Surgical trends in elderly patients with proximal humeral fractures in South Korea: a population-based study / Y. H. Jo, K. H. Lee, B. G. Lee // *BMC Musculoskeletal Disorders.* — 2019. — Vol. 20 (1). — Article ID : 136. — DOI: 10.1186/s12891-019-2515-2.
 9. Complex proximal humerus fractures: Hertel's criteria reliability to predict head necrosis / G. Campochiaro, M. Rebuzzi, P. Baudi, F. Catani // *Musculoskeletal Surgery.* — 2015. — Vol. 99 (Suppl 1). — P. S9–S15. — DOI: 10.1007/s12306-015-0358-z.
 10. Archer L. A. Rate of avascular necrosis and time to surgery in proximal humerus fractures. / L. A. Archer, A. Furey // *Musculoskeletal Surgery.* — 2016. — Vol. 100 (3). — P. 213–216. — DOI: 10.1007/s12306-016-0425-0.
 11. Risk factors for humeral head necrosis and non-union after plating in proximal humeral fractures / S. Boesmueller, M. Wech, M. Gregori [et al.] // *Injury.* — 2016. — Vol. 47 (2). — P. 350–355. — DOI: 10.1016/j.injury.2015.10.001.
 12. Operative treatment of 2-part surgical neck fractures of the proximal humerus (AO 11-A3) in the elderly: Cement augmented locking plate Philos™ vs. proximal humerus nail MultiLoc® / T. Helfen, G. Siebenbürger, M. Mayer [et al.] // *BMC Musculoskeletal Disorders.* — 2016. — Vol. 17 (1). — Article ID: 448. — DOI: 10.1186/s12891-016-1302-6.
 13. Current concepts in locking plate fixation of proximal humerus fractures / C. J. Laux, F. Grubhofer, C. M. L. Werner [et al.] // *Journal of Orthopaedic Surgery.* — 2017. — Vol. 12 (1). — Article ID: 137. — DOI: 10.1186/s13018-017-0639-3.
 14. An experimental study of the mechanical properties of polylactide / M. Korzh, M. Shidlovsky, V. Makarov [et al.] // *Trauma (Ukraine).* — 2019. — Vol. 20 (6). — P. 5–11. — DOI: 10.22141/1608-1706.6.20.2019.186029. (in Ukrainian)
 15. Makarov V. Osteosynthesis around the polylactide, implanted into the metadiaphysis defect of the femur (experimental study) / V. Makarov, N. Dedukh, O. Nikolchenko // *Orthopaedics, Traumatology and Prosthetics.* — 2018. — No. 2. — P. 102–107. — DOI: 10.15674/0030-598720182102-107. (in russian)
 16. The results of clinical trial with polylactide implants for osteosynthesis of proximal humerus fractures in patients with osteoporosis / M. Korzh, V. Makarov, O. Tankut, O. Pidgaiska // *Orthopaedics, Traumatology and Prosthetics.* — 2019. — No. 4. — P. 26–36. — DOI: 10.15674/0030-59872019426-36. (in russian)
 17. Five-year outcome after conversion of a hemiarthroplasty when used for the treatment of a proximal humeral fracture to a reverse total shoulder arthroplasty / M. Holschen, M. K. Siemes, K. A. Witt, J. Steinbeck // *The Bone & Joint Journal.* — 2018. — Vol. 100-B (6). — P. 761–766. — DOI: 10.1302/0301-620X.100B6.BJJ-2017-1280.R1.
 18. Revision of failed shoulder hemiarthroplasty to reverse total arthroplasty: analysis of 157 revision implants / G. Merolla, E. Wagner, J. W. Sperling [et al.] // *Journal of Shoulder and Elbow Surgery.* — 2018. — Vol. 27 (1). — P. 75–81. — DOI: 10.1016/j.jse.2017.06.038.
 19. Reverse shoulder replacement versus hemiarthroplasty for proximal humeral fracture in elderly patients: a systematic review / M. Vall, L. Natera, C. Witney-Lagen [et al.] // *Musculoskeletal Surgery.* — 2022. — Vol. 106 (4). — P. 357–367. — DOI: 10.1007/s12306-022-00761-y.
 20. Grammont reverse prosthesis: design, rationale, and biomechanics / P. Boileau, D. J. Watkinson, A. M. Hatzidakis, F. Balg // *Journal of Shoulder and Elbow Surgery.* — 2005. — Vol. 14 (1 Suppl S). — P. 147S–161S. — DOI: 10.1016/j.jse.2004.10.006.
 21. Prostheses for reverse total shoulder arthroplasty / J. M. Kazley, K. P. Cole, K. J. Desai [et al.] // *Expert Review of Medical Devices.* — 2019. — Vol. 16 (2). — P. 107–118. — DOI: 10.1080/17434440.2019.1568237.
 22. Reverse Shoulder Arthroplasty for the treatment of Proximal humeral fractures in the Elderly (ReShAPE trial) : study protocol for a multicentre combined randomised controlled and observational trial / G. C. Smith, E. Bateman, B. Cass [et al.] // *Trials.* — 2017. — Vol. 18 (1). — Article ID: 91. — DOI: 10.1186/s13063-017-1826-6.
 23. Reverse shoulder arthroplasty for proximal humeral fractures: outcomes comparing primary reverse arthroplasty for fracture versus reverse arthroplasty after failed osteosynthesis / S. F. Shannon, E. R. Wagner, M. T. Houdek [et al.] // *Journal of Shoulder and Elbow Surgery.* — 2016. — Vol. 25 (10). — P. 1655–1660. — DOI: 10.1016/j.jse.2016.02.012.
 24. Salvage reverse total shoulder arthroplasty for failed operative treatment of proximal humeral fractures in patients younger than 60 years: long-term results / L. Ernstbrunner, S. Rahm, A. Suter [et al.] // *Journal of Shoulder and Elbow Surgery.* — 2020. — Vol. 29 (3). — P. 561–570. — DOI: 10.1016/j.jse.2019.07.040.
 25. Reverse total shoulder arthroplasty for failed open reduction and internal fixation of fractures of the proximal humerus / F. Grubhofer, K. Wieser, D. C. Meyer [et al.] // *Journal of Shoulder and Elbow Surgery.* — 2017. — Vol. 26 (1). — P. 92–100. — DOI: 10.1016/j.jse.2016.05.020.
 26. Neer C. S. 2nd. Displaced proximal humeral fractures. I. Classification and evaluation / C. S. Neer 2nd // *The Journal of Bone and Joint Surgery. American volume.* — 1970. — Vol. 52 (6). — P. 1077–1089.
 27. Translation between the Neer- and the AO/OTA-classification for proximal humeral fractures: do we need to be bilingual to interpret the scientific literature? / S. Brorson, H. Eckardt, L. Audige [et al.] // *BMC Research Notes.* — 2013. — Vol. 6. — Article ID: 69. — DOI: 10.1186/1756-0500-6-69.
 28. Results of open repositioning and bony fixation with plates with angular stability of fractures of the proximal part of the humerus in patients with osteoporosis / N. A. Korzh, V. B. Makarov, A. V. Sabsai [et al.] // *Orthopedics, Traumatology and Prosthetics.* — 2020. — No. 3 (620). — P. 44–53. — DOI: 10.15674/0030-59872020344-53. (in russian)
 29. Pat. 147449 UA. A61F 2/04 Porous biodegradable implant / V. B. Makarov, M. O. Korzh, A. M. Kovalev, D. O. Chupryna. — No. u202101236; statement 12.03.2021; published 05.05.2021, Bul. No. 18. (in Ukrainian)
 30. Pat. 147264 UA. Reversible total modular endoprosthesis of the shoulder joint / V. R. Ermakov, Yu. M. Nikitin, K. O. Grebennikov, D. O. Chupryna. — No. u202101238; statement 12.03.2021; published 04.21.2021, Bul. No. 16. (in Ukrainian)
 31. Influence of trabecular microstructure and cortical index on the complexity of proximal humeral fractures / G. Osterhoff, G. Diederichs, A. Tami [et al.] // *Archives of Orthopaedic and Trauma Surgery.* — 2012. — Vol. 132 (4). — P. 509–515. — DOI: 10.1007/s00402-011-1446-7.
 32. The influence of bone mineral density and cortical index on the complexity of fractures of the proximal humerus / J. W. den Teuling, B. S. Pauwels, L. Janssen [et al.] // *Bone & Joint Research.* — 2017. — Vol. 6. — P. 584–589. — DOI:

- 10.1302/2046-3758.610.
33. Standardised test protocol (Constant Score) for evaluation of functionality in patients with shoulder disorders / I. Ban, A. Troelsen, D. H. Christiansen [et al.] // *Danish Medical Journal*. — 2013. — Vol. 60 (4). — Article ID : A4608.
 34. Vasiliev V. V. Application of diamond-like coatings (APP) on the end surfaces of silicon carbide rings for dry gas-sealed high-pressure compressors / V. V. Vasiliev, A. A. Luchaninov, V. E. Strelnytskyi // *Problems of Atomic Science and Technology*. — 2018. — No. 1 (113). — P. 88–92. — (Serie : “Vacuum, pure materials, superconductors”). — Available from: https://vant.kipt.kharkov.ua/TABFRAME2_themes.html
 35. DLC Coatings on Spherical Elements of HIP Endoprostheses / V. V. Vasiliev, V. E. Strelnytskyi, V. B. Makarov [et al.] // *European Journal of Engineering and Formal Sciences*. — 2022. — Vol. 5. — P. 80–88.
 36. Trending a decade of proximal humerus fracture management in older adults / A. H. Patel, J. H. Wilder, S. A. Ofa [et al.] // *JSES Int*. — 2021. — Vol. 6 (1). — P. 137–143. — DOI: 10.1016/j.jseint.2021.08.006.
 37. ESTES recommendations on proximal humerus fractures in the elderly / K. W. Wendt, M. Jaeger, J. Verbruggen [et al.] // *European Journal of Trauma and Emergency Surgery*. — 2021. — Vol. 47 (2). — P. 381–395. — DOI: 10.1007/s00068-020-01437-7.
 38. Shoulder arthroplasty for proximal humeral fracture treatment: a retrospective functional outcome analysis / S. Weber, H. Grehn, R. Hutter [et al.] // *European Journal of Trauma and Emergency Surgery*. — 2022. — Advance online publication. — DOI: 10.1007/s00590-022-03313-z.
 39. Proximal humeral fracture-dislocation: Outcome analysis in osteosynthesis and arthroplasties / S. Haupt, S. Weber, H. Frima [et al.] // *European Journal of Trauma and Emergency Surgery*. — 2022. — Advance online publication. — DOI: 10.1007/s00590-021-03183-x.
 40. Reverse shoulder arthroplasty for proximal humeral fractures: outcomes comparing primary reverse arthroplasty for fracture versus reverse arthroplasty after failed osteosynthesis / S. F. Shannon, E. R. Wagner, M. T. Houdek [et al.] // *Journal of Shoulder and Elbow Surgery*. — 2016. — Vol. 25 (10). — P. 1655–1660. — DOI: 10.1016/j.jse.2016.02.012.
 41. Larose G. The evolution of reverse total shoulder arthroplasty and its current use in the treatment of proximal humerus fractures in the older population / G. Larose, M. S. Virk // *Journal of Clinical Medicine*. — 2022. — Vol. 11 (19). — Article ID: 5832. — DOI: 10.3390/jcm11195832.

The article has been sent to the editors 31.10.2022

RESULTS OF A DIFFERENTIAL APPROACH TO SURGICAL TREATMENT OF PROXIMAL HUMERUS FRACTURES IN PATIENTS WITH OSTEOPOROSIS

M. O. Korzh¹, V. B. Makarov², I. G. Gupalov², O. M. Pertseva², K. P. Boyko², O. O. Pidgaiska¹

¹ Sytenko Institute of Spine and Joint Pathology National Academy of Medical Sciences of Ukraine, Kharkiv

² Municipal non-profit enterprise «City Clinical Hospital № 16» of the Dnipro City Council. Ukraine

✉ Mykola Korzh, MD, Prof. in Traumatology and Orthopaedics: mykola.korzh47@gmail.com

✉ Vasyly Makarov, MD, PhD in Orthopaedics and Traumatology: vasylmakarov2010@gmail.com

✉ Igor Gupalov, MD: iggupalov@gmail.com

✉ Olena Pertseva, MD: ompertseva@gmail.com

✉ Konstantin Boyko, MD: kpboyko@gmail.com

✉ Olga Pidgaiska, MD, PhD in Traumatology and Orthopaedics: podgayo@yahoo.com