

SHORT REPORTS AND NOTES FROM PRACTICE

УДК 616.727.2-089.843:004.942*3D](045)

DOI: <http://dx.doi.org/10.15674/0030-598720221-293-98>**The first experience of individual revers shoulder arthroplasty in case of post-traumatic glenoid deformation (case from practice)****M. L. Golovakha¹, S. A. Bondarenko², O. O. Grytsenko³, A. Yu. Pogarsky⁴**¹ Zaporizhzhia State Medical University, Ukraine² «Motor Sich» Clinic, Zaporizhzhia, Ukraine³ «Ekodnipro LLC», Dnipro, Ukraine⁴ Collegial Studio, Zaporizhzhia, Ukraine

Total shoulder arthroplasty (anatomical or reversible) has gained considerable popularity, but the difficulty of installing the glenoid component determines the development of 30–50 % of mechanical complications and revision operations. To simplify glenoid installation, an individual tool of an unusual design is used. Objective. To show clinical case of individual modeling of a glenoid implant, made by 3D printing, for the patient with old fixed humeral dislocation. Methods. A 52-year-old patient complained of severe pain and impaired limb function 4 years after a fracture-dislocation of the left humeral head, that was not reduced. The difficulty was in the presence of a significant HillSachs impression and huge anterior glenoid defect, IV stage osteoarthritis. Results. To solve the problem, a three-dimensional model of the scapula was built based on the results of computer tomography, and its plastic model was printed. Designed individual augment for glenosphere installation. Lateralization of the center of rotation by 5 mm and downward inclination of the glenosphere by 5° was performed in the implant. The implant stem channel and screw holes are modeled to pass through the most massive parts of the scapula. An individual tool has been developed for installing this component and drillings for the screws. During the surgical intervention, the prepared tools and implant allowed to install a revers total shoulder implant and obtain the nearest positive result. Conclusions. It is advisable to use three-dimensional modelling with 3D printing in cases of reversible shoulder arthroplasty for patients with old fixed humeral dislocation and significant glenoid defect. Key words. Shoulder, chronic dislocation, revers shoulder arthroplasty.

Тотальне ендопротезування плечового суглоба (анатомічне або реверсивне) набуло значної популярності, але складність встановлення гленоїдного компонента обумовлює розвиток 30–50 % механічних ускладнень і виконання ревізійних операцій. Для спрощення встановлення імплантата гленоїда використовують індивідуальний інструмент не звичного дизайну. Мета. Навести клінічний випадок індивідуального моделювання імплантата гленоїда, виготовленого методом 3D-друку, для реверсивного ендопротезування плечового суглоба хворого на застарілий вивих головки плечової кістки. Методи. Пацієнт, 52 роки, звернувся зі скаргами на сильний біль і порушення функції кінцівки через 4 роки після переломовивиху головки лівої плечової кістки, який не був вправлений. Складністю надання допомоги була наявність значного імпресійного дефекту Hill-Sachs та переднього краю суглобової поверхні лопатки, остеоартроз IV ст. Результати. Для вирішення проблеми було побудовано тривимірну модель суглобової западини лопатки на основі результатів комп'ютерної томографії та виготовлений її пластиковий макет за допомогою 3D-друку. Спроектований індивідуальний аугмент для встановлення гленосфери реверсивного ендопротеза. В імплантаті виконано латералізацію центра обертання на 5 мм і нахил гленосфери донизу на 5°. Канал для ніжки імплантата й отвори для гвинтів змодельовані так, щоб вони пройшли в наймасивніших частинах лопатки. Розроблено індивідуальний інструмент для встановлення цього компонента та проведення фіксувальних гвинтів. Під час хірургічного втручання підготовлені інструменти й імплантат дозволили встановити пацієнту реверсивний ендопротез і отримати найближчий позитивний результат. Висновки. Застосування тривимірного моделювання з 3D-друком доцільно використовувати у випадках реверсивного ендопротезування плечового суглоба в пацієнтів зі застарілими вивихами головки плечової кістки та значними дефектами суглобової поверхні лопатки. Ключові слова. Плечовий суглоб, застарілий вивих, ендопротезування.

Key words. Shoulder, chronic dislocation, revers shoulder arthroplasty

Introduction

The history of endoprosthetic repair of the shoulder joint dates back to the 19th century. In Paris International Hospital on 11 March 1893, the surgeon Jules Emile Pean performed it for the first time [1]. He replaced the shoulder joint destroyed by tuberculosis with an implant made of platinum and rubber. His work was based on Themistocles Gluck's research on the development of shoulder joint endoprosthesis designs [2]. In 1921, Albee tried to replace the defect of the proximal part of the shoulder with a graft from the fibula bone [3]. In 1933, L. Jones described arthroplasty in the case of fragment fractures of the proximal end of the humerus [4]. He resected all fragments of the head and tubercles and rounded the remainder of the humerus and sutured components of the musculotendinous cuff to it, but this rarely resulted in good restoration of function. Since those times, the history of orthopedics has known many attempts to transplant an artificial shoulder joint, but the starting point is considered to be the works of Charles Neer [5]. In 1951, he successfully replaced the humeral head with a unipolar endoprosthesis with a 44 mm radius of curvature, made of vitalium. The first result of the operation was published in 1955 [5]. Surgical treatment made it possible to significantly improve the function of the limb compared to previously known arthroplasty interventions. Currently, the following are used in clinical practice: unipolar endoprosthesis (hemiarthroplasty), total, which is also called anatomical, and reversible. Usually, modular implants are used for a better opportunity to anatomically adapt the size of the endoprosthesis to the patient's joint.

In Ukraine, the first endoprosthesis of the shoulder joint was developed by V. A. Rodichkin (1981) [6], who reported on three successful operations to replace the shoulder joint due to chronic fracture-dislocations of the proximal part of the humerus. The next domestic implant of the shoulder joint was also a unipolar endoprosthesis ORTEN [7].

Reversible shoulder joint replacement is the most important achievement in shoulder surgery over the past 30 years. The method was developed by R. Grammont et al. [8], but the first operations of reversible endoprosthesis showed not too encouraging results due to wear and loosening of the components.

However, later the technique of reversible shoulder arthroplasty was technologically improved, which made it possible to expand its surgical capa-

bilities, the number and complexity of operations [9]. Improvement of implant fixation methods, creation of new materials for osseointegration of support surfaces increased the service life of these endoprostheses [10–12]. The development of new implant designs has expanded the possibilities during surgery. New modifications have appeared: different angles of the neck and diameter of the glenosphere, the length of the leg, modular leg systems that transform from an anatomical endoprosthesis into a reversible one, and asymmetric pads for installing the glenosphere [13–16]. In addition, software for preoperative planning has significantly improved, allowing the development of 3D printed individual templates and implants [16–19].

Total shoulder arthroplasty (anatomic or reversible) is becoming increasingly popular, but the placement of the glenoid component remains problematic, resulting in 30–50% of mechanical complications requiring revision surgery. Incorrect positioning of the glenoid component is one of the main errors in the case of defects and deformations of the glenoid, therefore, an individual tool is used to simplify and optimize the installation of the implant. But in significant deformations of the articular surface of the scapula, it is not possible to install a glenoid implant of the usual design. In this case, it is made individually.

Purpose: to cite a clinical case of individual modeling of a glenoid implant made by 3D printing for reversible endoprosthetic repair of the shoulder joint in a patient with chronic dislocation of the humeral head.

Material and methods

A 52-year-old patient B. suffered a household injury in 2017 as a result of a fall on his left shoulder. He was diagnosed with a fracture of the head of the left humerus, and was referred to closed reduction and fixation with a bandage. In 2 weeks, a repeated dislocation occurred, which was also closed. Further, he received conservative treatment; however, according to the patient he felt limited movement and pain.

Later, the pain worsened, and in 2020 the patient presented with pain and restriction of movement. Following X-ray and computed tomography (CT), an old anterior dislocation of the head of the left humerus, an improperly restored fracture of the greater tubercle, a significant impression defect of Hill-Sachs, a defect of the anterior edge of the glenoid, IV stage osteoarthritis were diagnosed (Fig. 1). The patient had no neurological deficit; there was moderate

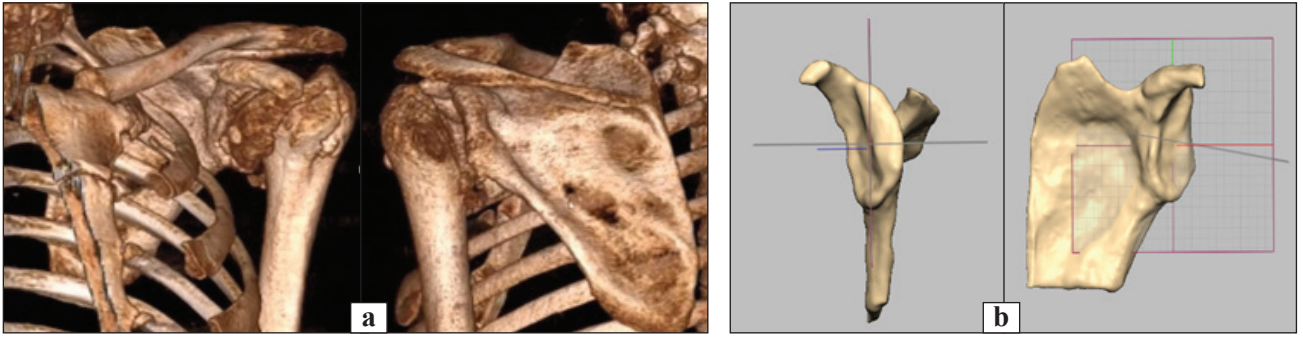


Fig. 1. CT reconstruction of the shoulder joint (a) and 3D reconstruction of the joint cavity of the scapula (b) in a 52-year-old patient B.

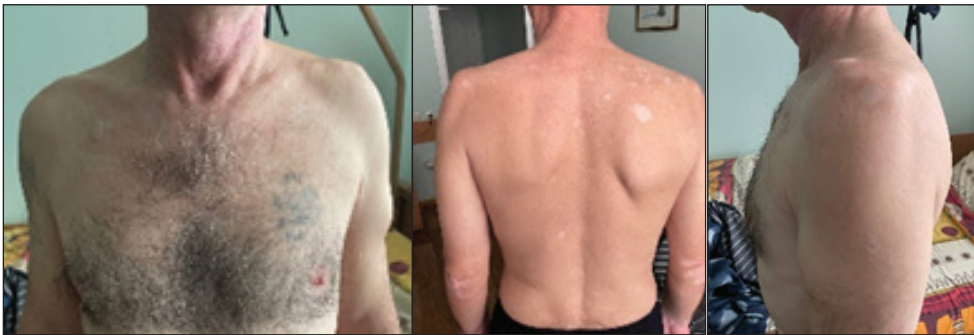

Fig. 2. Appearance of the left shoulder joint of a 52-year-old patient B.



Fig. 3. A plastic model of the scapula, printed according to the built model of the patient, simulating the installation of a standard reversible scapular endoprosthesis component


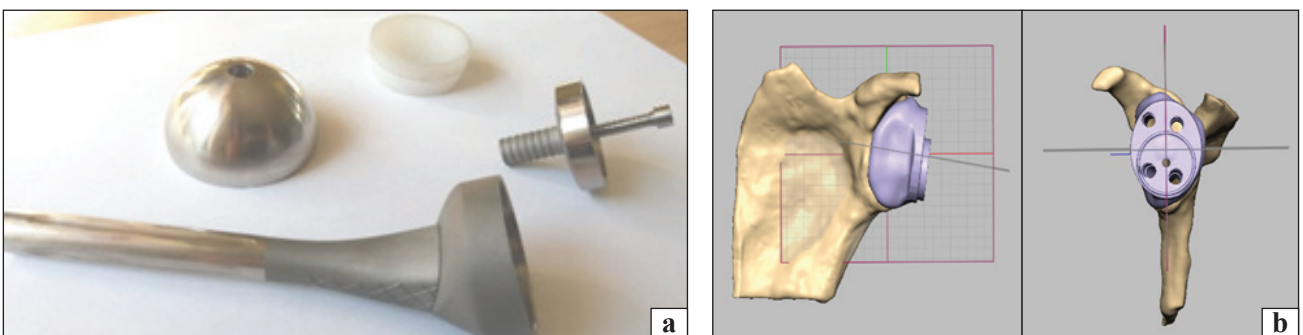


Fig. 4. Modeling of an individual augmentation for fixing the glenosphere of a reversible shoulder joint prosthesis: a) general view of the endoprosthesis; b) three-dimensional model of augment; c) designing the position of the leg of the endoprosthesis and the directions of the fixing screws




Fig. 5. Conductors for positioning the leg of the endoprosthesis and fixing screws: a) for guiding the spoke under the leg; b) for drilling channels for screws printed from titanium; c) plastic model of augment

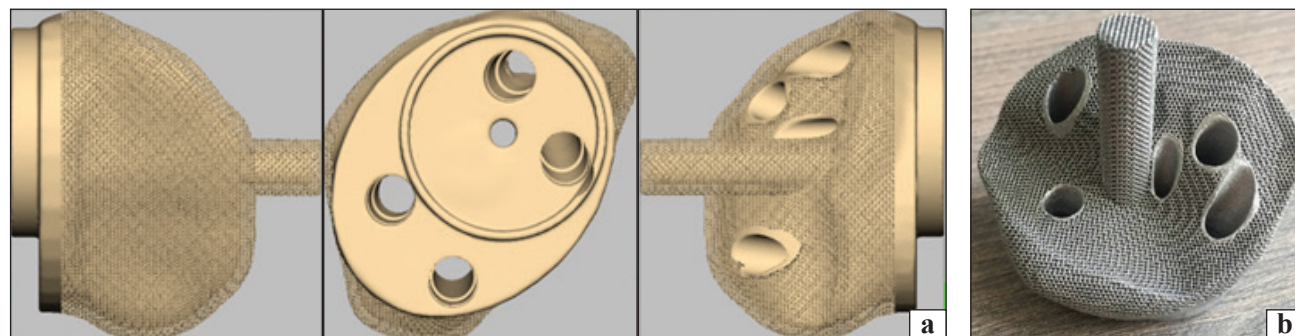


Fig. 6. Individual augment for fixing the glenosphere of the reversible endoprosthesis of the shoulder joint: a) computer model; b) implant

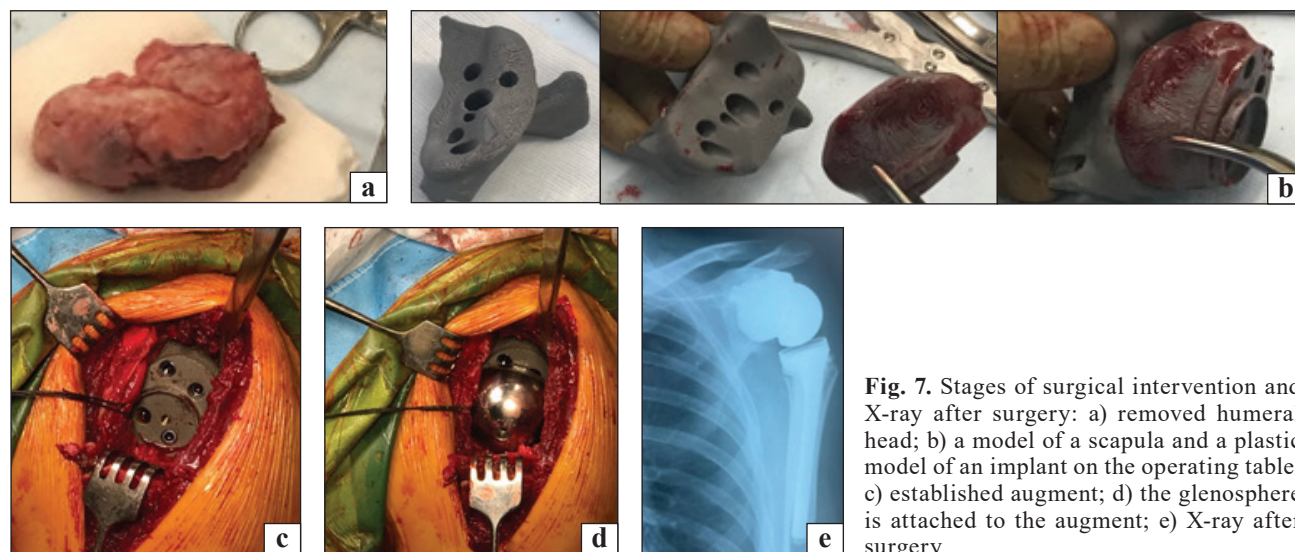


Fig. 7. Stages of surgical intervention and X-ray after surgery: a) removed humeral head; b) a model of a scapula and a plastic model of an implant on the operating table; c) established augment; d) the glenosphere is attached to the augment; e) X-ray after surgery

atrophy of the supraspinatus, subspinatus and deltoid muscles (Fig. 2).

Visual examination of the glenoid defect showed that it was impossible to use a standard implant for a reversible endoprosthesis.

Results and their discussion

At the first stage, we built a three-dimensional model of the articular cavity of the scapula and produced a plastic sample using additive technology (Fig. 3). This was done in order to find the possibility of installing a glenoid implant using bone plastic.

Installation of an implant with the maximum allowable retroversion angle of 100 was practically impossible, since there was no possibility to install the leg of the endoprosthesis in the body of the scapula.

Using three-dimensional modeling technology, we manufactured a custom implant that replicated the shape of the articular surface of the remaining scapula and additionally supported the base of the coracoid process. The position of the implant leg was designed in the place where the largest mass of bone remained at the base of the glenoid. This augment was built under the glenosphere with a 42 mm

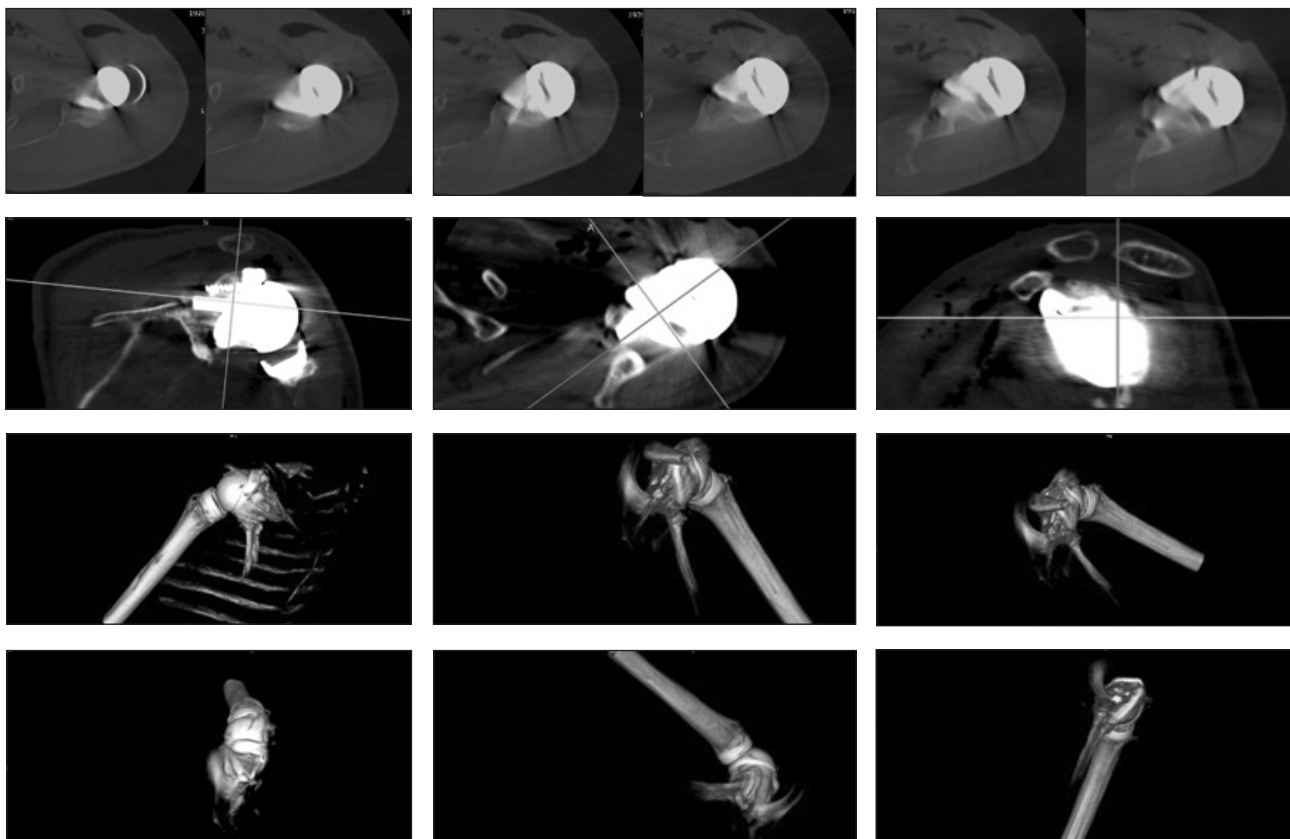


Fig. 8. CT scan of the shoulder joint after surgery

«reversible shoulder prosthesis». Lateralization of the center of rotation by 5 mm and downward inclination of the glenosphere by 5° was performed in the implant (Fig. 4). The endoprosthesis stem channel and screw holes were pre-molded to pass through the most massive parts of the scapula. Conductors were printed during intraoperative positioning of the canal for the endoprosthesis stem and drilling of screws (Fig. 5). After building the model, a trabecular mesh was applied to its attachment surface and sent for 3D printing from pure titanium (Fig. 6).

Under general anesthesia, the patient underwent an arthrotomy of the left shoulder joint, after isolation and economical resection of the head of the humerus, a capsulotomy was performed and the articular cavity of the scapula was isolated. The latter was freed from soft tissues, and according to individual guides printed on a 3D printer, channels were drilled for the leg of the endoprosthesis and for fixing screws (Fig. 7). The augment was inserted with the leg into the opening of the articular surface of the scapula, fixed with screws, and the glenosphere was attached to it. The leg of the endoprosthesis was installed, the adjustment was performed and the range of motion and stability of the joint was checked. Passive movements were in full force on the operating table.

After the operation, the patient underwent a CT scan to assess the position of the augmentation of the joint cavity. The results of the study are shown in Fig. 8. On the selected sections and reconstructions, it can be seen that the implant fits tightly to the surface of the scapula, and the screws are located in the most massive parts of the scapula, which fully corresponds to the preoperative modeling.

In the postoperative period, immobilization with a kerchief bandage was applied for three weeks. Active movements in the hand and elbow joint were recommended to the patient, in the shoulder joint, abduction was allowed no more than 45° and external rotation was prohibited. After 3 weeks, the range of motion in the shoulder joint was partially restored. The patient did not have pain at rest or during movement. He began to use his hand, gradually restoring muscle tone and limb function.

Conclusions

It is advisable to use three-dimensional modeling with 3D printing in cases of reversible endoprosthetic repair of the shoulder joint in case of chronic dislocations of the head of the humerus and a significant defect of the articular surface of the scapula, which makes it possible to obtain a good clinical and functional result.

Conflict of interest. The authors declare no conflict of interest.

References

1. Pean J. E. Des moyens prosthétiques destinés à obtenir la réparation de parties osseuses / J. E. Pean // *Gaz de Hop Paris*. — 1894. — Vol. 67. — P. 291.
2. Bankes M. J. Pioneers of shoulder replacement: Themistocles Gluck and Jules Emile Pean / M. J. Bankes, R. J. Emery // *Journal of shoulder and elbow surgery*. — 1995. — Vol. 4 (4). — P. 259–262. — DOI: 10.1016/s1058-2746(05)80018-7.
3. Albee F. H. Restoration of shoulder function in cases of loss of head and upper portion of humerus / F. H. Albee // *Surgery, Gynecology and Obstetrics*. — 1921. — Vol. 32. — P. 1.
4. Jones L. Reconstructive operation for non-reducible fractures of the head of the humerus / L. Jones // *Annals of surgery*. — 1933. — Vol. 97 (2). — P. 217–225. — DOI: 10.1097/00000658-193302000-00006.
5. Neer C. S. 2nd. Articular replacement for the humeral head / C. S. Neer 2nd // *The Journal of bone and joint surgery. American volume*. — 1955. — Vol. 37-A (2). — P. 215–228.
6. Rodichkin V. A. Treatment of fractures of the proximal end of the humerus : Abstract of the thesis Candidate of Medical Sciences / V. A. Rodichkin. — Kharkov, 1987. — 20 p.
7. Loskutov A. E. Endoprosthesis replacement at the polyfragmental fractures of the humeral head [Jendoprotezirovanie pri polifragmentarnyh perelomah golovki plechevoj kosti] / A. E. Loskutov, V. N. Tomilin // *Travma*. — 2010. — Vol. 11 (4). — P. 436–440. (in Russian)
8. Study and development of a new shoulder prosthesis / P. Grammont, P. Trouilloud, J. Laffay, X. Deries // *Rheumatologie*. — 1987. — Vol. 39. — P. 407–418. (in French)
9. Carpenter S. R. Porous metals and alternate bearing surfaces in shoulder arthroplasty / S. R. Carpenter, I. Urits, A. M. Murthi // *Current reviews in musculoskeletal medicine*. — 2016. — Vol. 9 (1). — P. 59–66. — DOI: 10.1007/s12178-016-9319-x
10. Nashikkar P. S. Role of intraoperative navigation in the fixation of the glenoid component in reverse total shoulder arthroplasty : a clinical case-control study / P. S. Nashikkar, C. J. Scholes, M. D. Haber // *Journal of shoulder and elbow surgery*. — 2019. — Vol. 28 (9). — P. 1685–1691. — DOI: 10.1016/j.jse.2019.03.013
11. Comparing conventional and computer-assisted surgery base-plate and screw placement in reverse shoulder arthroplasty / G. Venne, B. J. Rasquinha, D. Pichora [et al.] // *Journal of shoulder and elbow surgery*. — 2015. — Vol. 24 (7). — P. 1112–1119. — DOI: 10.1016/j.jse.2014.10.012
12. Platform systems in shoulder arthroplasty / B. C. Werner, J. S. Dines, D. M. Dines, B. C. Werner // *Current reviews in musculoskeletal medicine*. — 2016. — Vol. 9 (1). — P. 49–53. — DOI: 10.1007/s12178-016-9317-z
13. The reverse shoulder arthroplasty angle: a new measurement of glenoid inclination for reverse shoulder arthroplasty / P. Boileau, M. O. Gauci, E. R. Wagner [et al.] // *Journal of shoulder and elbow surgery*. — 2019. — Vol. 28 (7). — P. 1281–1290. — DOI: 10.1016/j.jse.2018.11.074.
14. 3D printing in shoulder surgery / V. Campana, V. Cardona, V. Vismara [et al.] // *Orthopedic reviews (Pavia)*. — 2020. — Vol. 12 (Suppl 1). — Article ID : 8681. — DOI: 10.4081/or.2020.8681
15. Use of Patient-Specific Instrumentation (PSI) for glenoid component positioning in shoulder arthroplasty. A systematic review and meta-analysis / G. Villatte, A. S. Muller, B. Pereira [et al.] // *PLoS One*. — 2018. — Vol. 13 (8). — Article ID: e0201759. — DOI: 10.1371/journal.pone.0201759
16. Three-dimensional planning and use of patient-specific guides improve glenoid component position: an in vitro study / G. Walch, P. S. Vezeridis, P. Boileau [et al.] // *Journal of shoulder and elbow surgery*. — 2015. — Vol. 24 (2). — P. 302–309. — DOI: 10.1016/j.jse.2014.05.029
17. GPS guided reverse shoulder arthroplasty / G. B. Colasanti, F. Moreschini, C. Cataldi [et al.] // *Acta Biomedica*. — 2020. — Vol. 91 (4-S). — P. 204–208. — DOI: 10.23750/abm.v91i4-S.9377
18. Does computerized CT-based 3D planning of the humeral head cut help to restore the anatomy of the proximal humerus after stemless total shoulder arthroplasty? / F. Grubhofer, A. R. Muniz Martinez, J. Haberli [et al.] // *Journal of shoulder and elbow surgery*. — 2021. — Vol. 30 (6). — P. e309–e316. — DOI: 10.1016/j.jse.2020.08.045
19. Custom-made reverse shoulder arthroplasty for severe glenoid bone loss: review of the literature and our preliminary results / G. Porcellini, G. M. Micheloni, L. Tarallo [et al.] // *Journal of orthopaedics and traumatology*. — 2021. — Vol. 22 (1). — Article ID: 2. — DOI: 10.1186/s10195-020-00564-6

The article has been sent to the editors 08.10.2021

THE FIRST EXPERIENCE OF INDIVIDUAL REVERS SHOULDER ARTHROPLASTY IN CASE OF POST-TRAUMATIC GLENOID DEFORMATION (CASE FROM PRACTICE)

M. L. Golovakha ¹, S. A. Bondarenko ², O. O. Grytsenko ³, A. Yu. Pogarsky ⁴

¹ Zaporizhzhia State Medical University. Ukraine

² «Motor Sich» Clinic, Zaporizhzhia. Ukraine

³ «Ekodnipro LLC», Dnipro. Ukraine

⁴ Collegial Studio, Zaporizhzhia. Ukraine

✉ Maxim Golovakha, MD, Prof. in Traumatology and Orthopaedics: golovaha@ukr.net

✉ Stanislav Bondarenko, MD: trauma.bon.s@gmail.com

✉ Olexandra Grytsenko, MD: alexandra_grit@hotmail.com

✉ Anton Pogarsky: anton.pogarskiy@gmail.com