

УДК 616.717.5-001.5(045)

Treatment of extra-articular distal radius fractures with the Targon DR Nail (intramedullary fixation)

Georg Gradl¹, Steffi S. I. Falk², Martina Wendt¹, Nadja Mielsch¹, Thomas Mittlmeier¹

¹ Department of Trauma and Reconstructive Surgery, University of Rostock. Germany

² Institute for Biostatistics and Informatics in Medicine and Ageing Research, University of Rostock. Germany

In this prospective study 82 patients at the mean age of 65 years (range 17 to 91 years) were treated with the Targon DR. Inclusion criteria were extra-articular A3 fractures. All patients were treated by closed reduction and intramedullary nailing using the Targon DR nail. The major outcome of this study was that intramedullary fixation with a hybrid between plate and nail comes along with excellent functional outcome and very low pain. The minimally invasive technique allows anatomical restoration and safe reduction permitting an early range of motion. At follow up of 1 year all patients had a functioning joint and resumed their previous activities. In x-ray analysis all fractures united with a reconstructed articular facet without any steps. There was no secondary loss of reduction by treatment with the Targon DR nail. We had no cases of hardware failures, tendon irritation or tendon rupture. The Targon DR is competitive in terms of fracture reduction, maintenance of reduction and functional outcome. Key words: intramedullary nailing, Targon DR, distal radial fracture.

В проспективном исследовании изучены результаты лечения 82 пациентов, средний возраст 65 лет (от 17 до 91), с помощью устройства Targon DR. Критериями включения были внесуставные повреждения дистального отдела лучевой кости А3 типа. Лечение заключалось в закрытой репозиции и интрамедуллярном остеосинтезе с использованием гвоздя Targon DR. Основным результатом исследования — интрамедуллярная фиксация гибридной конструкцией между пластиной и гвоздем сопровождается превосходным функциональным результатом и очень низкой интенсивностью боли. Эта минимально инвазивная методика позволяет провести анатомичную репозицию и безопасное восстановление целостности кости, что дает возможность ранних движений в суставе. Через 1 год отмечали хорошую функцию лучезапястного сустава у всех пациентов, которые вернулись к своей прежней деятельности. По данным рентгенологического обследования, все переломы срослись с реконструкцией суставной поверхности без каких-либо неровностей. Вторичного смещения в результате проведенного лечения гвоздем Targon DR не было. Не зафиксированы поломка конструкции и ирритация или разрыв сухожилий. Устройство Targon DR обеспечивает положительный клинический эффект за счет восстановления кости после перелома, сохранения вправления и достижения хорошего функционального результата. Ключевые слова: интрамедуллярный остеосинтез, Targon DR, перелом дистального отдела лучевой кости.

Key words: intramedullary nailing, Targon DR, distal radial fracture

Introduction

The distal radius is the most commonly fractured bone in the human body [1–4]. Type-A fractures are the most common in all ages [3, 5]. The objectives of

treatment are restoration of unrestricted, lasting and pain-free function of the wrist, lower arm and avoidance of typical complications. Successful functional outcomes for distal radius fractures are a result of

appropriate surgical treatment which strives for as an anatomically accurate result as possible [6, 7] as well as timely rehabilitation [8]. The results of [5] underline the need and usefulness of differentiating operative therapies according to the fracture type in the AO classification system. The ideal surgical treatment would provide stable fixed-angle fragment-specific support with minimal soft tissue disturbance and exact anatomical restoration and allow safe and early active wrist rehabilitation. Surgical treatment strategies available for unstable distal radius fractures include percutaneous pinning, external fixation, dorsal plating, and volar fixed-angle plating as well as minimally invasive techniques. External fixation may improve the maintenance of reduction but not the functional outcome [9, 10]. Fixed angle locking plates are widely used for the management of extra-articular fractures and have become the standard of treatment [11, 12].

Many studies report good and excellent clinical results [13–15]. But volar and dorsal locking plate fixation is associated with tendon irritations or ruptures. The use of locked plates can also result in breakage of plate, screw loosening, CTS or complex regional pain syndrome [16–19]. Furthermore, the loss of radial inclination of the distal radius is an infrequent but serious complication of volar fixed-angle plating. With this in mind we were interested in looking up the functional outcome of our hybrid between plate and nail — the Targon DR.

Intramedullary nailing is the latest technique that has been developed to manage distal radius fractures. It combines the soft-tissue advantages of a less invasive surgical approach with the biomechanical advantages of locking screw technology [20]. The nail has been developed to minimize the surgical exposure and to prevent tendon irritations and to give the patient a fast return to activity. Currently preliminary clinical data is emerging in the form of short-term follow-up studies with small groups of patients [21]. Our aim was to study the outcomes of the Targon DR nail for extra-articular A3 fractures and for a larger number of study participants.

This prospective study assessed the quality of fracture care using the Targon DR. We present the experience of 82 managed patients with follow up after 8 weeks, 6 and 12 months. Fractures were classified according to the AO system [22].

Material and methods

Patients

In this prospective randomized study 82 patients with AO Type A3 fractures were treated with the intramedullary Targon DR. The patient population consisted of 67 women and 15 men at the averaged




Fig. 1. Skin incision on the radius

age of 65 years (range 17 to 91 years). The inclusion criteria were extra-articular A3 fractures. Patients that sustained a dorsal or volar sharing fracture or fracture of the radial styloid (B fractures) or presented with a history of previous wrist trauma were excluded from the study. All patients were treated by closed reduction and intramedullary nailing using the Targon DR nail (B. Braun Aesculap, Tuttlingen, Germany).

Surgical Technique

Surgery was performed under general or brachial plexus anaesthesia. The patient was placed in supine position and the affected arm lay on an arm-table. The arm was abducted in 90 degrees and supinated. After that a 4 cm skin incision was made from the tip of the radial styloid (fig. 1). The superficial branch of the radial nerve was identified and protected for the duration of the procedure. The dissection is deepened to the processus styloideus radii between first and second extensor compartment. The fracture was reduced by insertion of a Kirschner wire (1.7 mm) from the tip of the styloid across the fracture line. The Fixation of the Kirschner wire should be bicortical with 30–40 degrees to the longitudinal axis of the radii.

The position of the Kirschner wire was controlled by using the x-ray image intensifier. If satisfactory reduction was achieved the intramedullary canal was opened with a cannulated drill using the Kirschner wire as a guide (fig. 2). Afterwards the intramedullary canal was stepwise widened with profilers by positioning the forearm in flexion and ulnar deviation (fig. 3). The flaking of a little bone fragment while widening the intramedullary canal can be tolerated. The fragment can be fixed in its anatomical position by the interlocking of the Targon DR with screws. During the preparation of the nail bed the fracture reduction was maintained by either a Kapandji wire or manual traction of the surgeon assistant. The Targon DR device was then implanted and four K-wire were inserted under control of an image intensifier. The

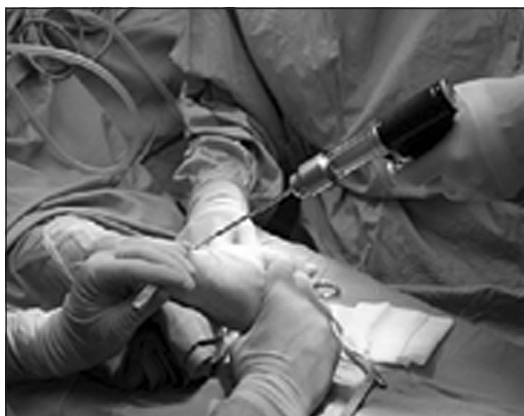

Fig. 2. Closed reduction of the fracture by insertion of a Kirschner wire

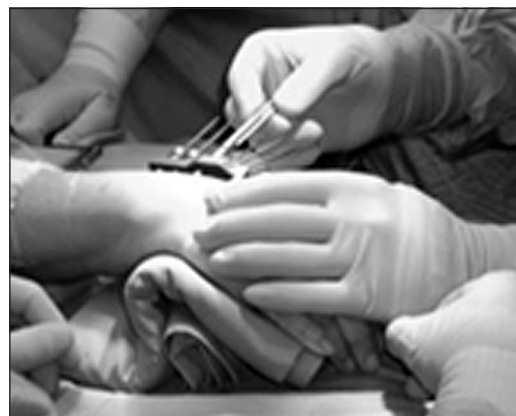

Fig. 4. Replacing the Kirschner wires with screws

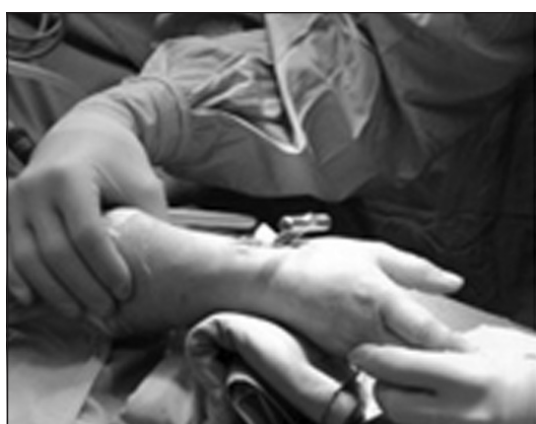

Fig. 3. Stepwise widening of the intramedullary canal

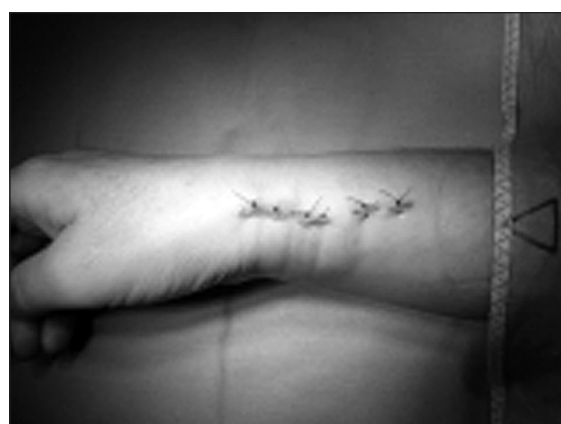

Fig. 5. Skin closure after the procedure

ideal position for the first wire is the subchondral bone area. The K-wires should not penetrate the opposite corticalis. In case of need a Repositioning of the radial length is now possible by pulling the device.

If the optimal length was achieved, the Targon DR was interlocked using an aiming device and Kirschner wires.

At this stage a fixed angle device was attained.

Surgery was completed by replacing the Kirschner wires with screws (fig. 4), removal of the aiming device and wound closure. Fig. 5 shows a representative picture of the ipsilateral forearm after wound closure.

Additional volar splinting was provided for not longer than three days to allow immediate functional aftertreatment. Implant removal was not encouraged.

Follow up Assessment

Follow up examinations at eight weeks, six months and one year after surgery included range of wrist motion measurements (extension, palmar flexion, pronation, supination, radial deviation, ulnar deviation) and analysis of grip strength using a grip dynamometer. Values were expressed as a percentage of the uninjured side [23].

Pain scores were assessed by a Visual Analog Scale (VAS, range 0–10) in rest and motion. In addition,

utilizing radiological, functional and subjective results, the Castaing Score [24] and the Gartland and Werley Score [25] were obtained at all times. Standard posterior-anterior and lateral radiographs were taken one day, eight weeks, six months and 1 year after surgery. All radiographs were digitally recorded and analysed regarding to palmar inclination, radial length and radial shortening. The measurements were performed relative to a central axis that was constructed on the lateral and posteroanterior films [26]. Radiological analysis included fracture AO classification.

Radial length was assessed by measuring the distance between the ulnar border of the distal radius and the distal articular surface of the ulna. In comparison to the uninjured side the difference in length of both sides was reported [27].

Results

From September 2005 to May 2008, 82 patients were treated with a Targon DR nail. 78 patients experienced the 8-week and the 6-month follow-up, 76 patients the 1-year follow-up. The mean time for surgery was (45.41 ± 0.98) min. All fractures united. Radiologic analysis revealed a mean palmar inclination

of (2.16 ± 0.59)°. As soon as 8 weeks after surgery the arc of extension/flexion reached 80/76 % of the uninjured side and 96/92 % one year after. Mean Gartland-Werley Score one year after surgery was excellent (1.64 ± 0.37).

Follow-up 8 weeks

79 Patients out of 82 (96.3 %) completed 8 weeks follow-up and 3 patients were lost. The mean follow-up period was 55 ± 1 days. One patient had died and 2 did not respond to the invitation. Seven patients out of 79 did not want to show up for the control and a medical interview was done via telephone. At follow-up the patients had a mean extension \pm SEM of (79.91 ± 2.28) %, flexion of (76.67 ± 2.45) %, pronation of (98.00 ± 1.02) %, supination of (87.34 ± 2.25) %, radial deviation of (76.93 ± 2.99) %, ulnar deviation of (80.42 ± 1.95) % and grip strength of (43.71 ± 3.91) %.

On the pain Visual Analogue Scale (VAS) the patients scored 0.08 ± 0.06 at rest and in activity 2.12 ± 0.26 . The mean of the Castaing Score was 4.16 ± 0.38 and of the Gartland & Werley Score was 5.66 ± 0.47 (table).

Radiological examination showed that mean radial shortening was (0.03 ± 0.02) mm, means that 2 Patients had a shortening of 1 or 2 mm.

Follow-up 6 months

79 Patients out of 82 (96.3 %) completed 6 months follow-up and 3 patients were lost. The average follow-up period was (184 ± 3) days. One patient had died and 2 did not respond to the invitation. Seventeen patients out of 79 did not want to show up for the control and had a medical interview via telephone. Average motion was: extension (91.36 ± 1.61) %, flexion (84.59 ± 2.13) %, pronation (100.00 ± 0.00) %, supination (96.29 ± 0.89) %, radial deviation (89.76 ± 2.25) %, ulnar deviation (89.36 ± 1.88) % and grip strength (77.21 ± 3.05) %. On the pain Visual Analogue Scale (VAS) the patients scored 0.10 ± 0.07 at rest and in activity 1.14 ± 0.24 . The mean of the Castaing Score was 2.08 ± 0.32 and of the Gartland & Werley Score

was 2.26 ± 0.33 . Radiological findings were: radial shortening were seen in two patients with 1 and 2 mm respectively.

Follow-up 1 year

76 Patients out of 82 (92.7 %) completed one year follow-up and 6 patients were lost. The mean follow-up period was (373 ± 4) days. One patient had died and 5 did not respond to the invitation. Eighteen patients out of 79 did not want to show up for the control and had a medical interview via telephone. At follow-up the patients had a mean extension \pm SEM of (95.69 ± 1.22) %, flexion of (91.83 ± 1.98) %, pronation of (99.75 ± 0.25) %, supination of (95.46 ± 1.10) %, radial deviation of (95.57 ± 1.44) %, ulnar deviation of (91.09 ± 1.74) % and grip strength of (87.76 ± 2.32) %. On the pain Visual Analogue Scale (VAS) the patients scored 0.13 ± 0.10 at rest and in activity 0.65 ± 0.23 . The mean of the Castaing Score was 1.41 ± 0.25 and of the Gartland & Werley Score was 1.64 ± 0.37 .

Radiological findings showed: The mean radial shortening was (0.07 ± 0.05) mm, means that 1 patient had a shortening of 1 mm and another patient with a shortening of 2 mm. The mean radial inclination was (2.16 ± 0.60) degrees (range, +15 to -5 degrees).

Complication

We found one case of superficial cutaneous infection at 8 week follow up. No chronic or deep soft-tissue infections were observed. One patient developed a carpal tunnel syndrome (CTS). Paraesthesia or dysaesthesia of the superficial radial nerve resolved in 15 cases. Full nerve recovery occurred in eight cases. In one case the dysaesthesia was already seen before surgery. We removed one locking screw in outpatient treatment that did not dynamised the fracture. There were two cases of screw loosening, in one case the implant was removed. We also found two cases of screw penetration: one into the ulna and one into the DRUJ, both were recommended to implant removal. Two Patients requested, due to discomfort at the wrist region, that their implant is removed. In this study 4 patients developed CRPS

Results 8 weeks, 6 months and 1 year after surgery

Table

Characteristics	Follow-up period		
	8 weeks	6 months	1 year
Extension (%)	79.91 ± 2.28 (17.67)	91.36 ± 1.61 (11.80)	95.69 ± 1.22 (8.12)
Flexion (%)	76.67 ± 2.45 (19.17)	84.59 ± 2.13 (15.82)	91.83 ± 1.98 (13.30)
Pronation (%)	98.00 ± 1.02 (7.99)	100.00 ± 0.00 (0.00)	99.75 ± 0.25 (1.66)
Supination (%)	87.34 ± 2.25 (17.61)	96.29 ± 0.89 (6.62)	95.46 ± 1.10 (7.36)
Radialabd (%)	76.93 ± 1.95 (15.22)	89.76 ± 2.25 (16.70)	95.57 ± 1.44 (9.68)
Ulnarabd (%)	80.42 ± 2.28 (17.67)	89.36 ± 1.88 (13.96)	91.09 ± 1.74 (11.65)
Grip strength (%)	43.71 ± 3.91 (30.04)	77.21 ± 3.05 (22.63)	87.76 ± 2.32 (15.37)
VAS rest	0.08 ± 0.06 (0.46)	0.10 ± 0.07 (0.54)	0.13 ± 0.10 (0.64)
VAS motion	2.12 ± 0.26 (0.05)	1.14 ± 0.24 (1.77)	0.65 ± 0.23 (1.54)
Casting	4.16 ± 0.38 (2.89)	2.08 ± 0.32 (2.31)	1.41 ± 0.25 (1.69)
Gartland & Werley	5.66 ± 0.47 (3.60)	2.26 ± 0.33 (2.38)	1.64 ± 0.37 (2.45)

(4.76 %). In one case the patient was treated with an additional plaster cast for 6 weeks. Targon DR breakage, Tendon irritation or tendon rupture wasn't seen.

Discussion

The major outcome of this study was that intramedullary fixation with a hybrid between plate and nail comes along with excellent functional outcome and very low pain. Therefore, the internal fixation with the Targon DR is a fair option for an alternative treatment to open reduction and volar plating. The main advantage of intramedullary fixation is the fast functional recovery that is attributed to the limited surgical approach at the radial styloid. The minimally invasive technique allows anatomical restoration and safe reduction permitting an early range of motion. There are very limited data available about intramedullary nailing procedures for the distal radius. Ilyas et al. and Tan et al. described a good functional outcome after intramedullary nailing [28, 29]. We experienced also good or excellent results in wrist motion and grip strength (data shown in table). Our clinical and radiological results are good to excellent. Immediate functional aftertreatment resulted in restoration of 77 to 98 % wrist function when compared to the uninjured side after 8 weeks. At follow up of 1 year all patients had a functioning joint and resumed their previous activities. In x-ray analysis all fractures united with a reconstructed articular facet without any steps. There was no secondary loss of reduction by treatment with the Targon DR nail. In contrary after intramedullary nailing with «Mikronail Wright Medical Corporation» in 13 % of cases secondary loss of reduction was seen and reoperation was necessary [28, 30]. The exactly performed operative technique using the Targon DR allows an anatomical restoration. The average time for this treatment for distal radius fractures was below the time necessary for volar plating. There were no complications like Targon DR breakage, tendon irritation or tendon rupture. Volar angle plating may reach up for tendon affections to 16.6 % [31] which displays 57 % of the overall complication rate. In our study tendon affections were not encountered because of intramedullary placement the nail and screws run in the frontal level of the radius. Radial shortening, which means shortening over 2 mm was not seen.

The surgical approach at the radial styloid had a risk to affect the superficial radial nerve. In our study a temporal paraesthesia or dysaesthesia of the superficial radial nerve resolved in 15 cases. Full nerve recovery occurred in eight cases. Loosening of locking screws in the distal part of the nail was registered in 2 cases (2.4 %). Espen et al. experienced that in 1 of 32 patients (3.1 %) [32]. Screw penetration into the distal radioulnar joint was seen by incorrect length of distal screws. Contrary to Ilyas et al. (with a rate of 30 %) we

registered only in one patient (1.2 %) a screw penetration into the DRUJ. We experienced in one case (1.2 %) dorsal displacement $\geq 5^\circ$ and a mean palmar inclination of 2.16° . We assume these are factors, which can all be controlled with proper training and more surgical experience. The applicability in fractures with articular involvement was not yet analysed.

In conclusion, we believe the Targon DR is competitive in terms of fracture reduction, maintenance of reduction and functional outcome to palmar angular stable plating in the treatment of distal radial fractures. We found this new technique to be versatile for the reduction and stable fixation of the fractures. All fractures united and there were no secondary loss of reduction. Patients returned quickly to their pre-injury level of wrist motion and tolerated the minimal invasive surgical procedure very well. Tan et al. reported also good results after intramedullary nailing, compatible with our findings. The main advantage seemed to be the limited surgical dissection and rigid fracture fixation which allowed an immediate postoperative recovery [28]. The Targon DR appeared as an effective device to treat extra-articular distal radial fractures (fig. 5), with good overall functional results and a low complication rate. We did not experience any long-term soft tissue problems. Further study to compare the outcome of patients treated with locking plates and the Targon DR is warranted to test the hypothesis that the hybrid between plate and nail is an extremely well treatment strategy for extra-articular distal radial fractures. Fig. 6 shows Clinical example of a 61 year old female, suffering from a A3.1 fracture of the distal radius. Preoperative and 12 months post surgery x-ry evaluation.

Values for motions and grip strength are reported as mean \pm SEM (SD) in percentage of the uninjured side.

References

1. Chung K. C. The frequency and epidemiology of hand and forearm fractures in the United States / K. C. Chung, S. V. Spilson // *J. Hand Surg. Am.* — 2001. — Vol. 26. — P. 908–915.
2. Epidemiology of fractures in England and Wales / T. P. van Staa, E. M. Dennison, H. G. Leufkens, C. Cooper // *Bone.* — 2001. — Vol. 29. — P. 517–522.
3. Brogren E. Incidence and characteristics of distal radius fractures in a southern Swedish region / E. Brogren, M. Petranek, I. Atroshi // *Musculoskelet. Disord.* — 2007. — Vol. 8. — Article 48.
4. Patients with femoral or distal forearm fracture in Germany: a prospective observational study on health care situation and outcome / H. G. Endres, B. Dasch, M. Lungenhausen [et al.] // *Public Health.* — 2006. — Vol. 6. — Article 87.
5. Fractures of the distal radius. Minimally invasive pin fixation: indications and results / L. Lindemann-Sperfeld, F. Pilz, I. Marintschev, W. Otto // *Chirurg.* — 2003. — Vol. 74. — P. 1000–1008.
6. Jupiter J. B. Complex articular fractures of the distal radius: classification and management / J. B. Jupiter // *J. Am. Acad. Orthop. Surg.* — 1997. — Vol. 5. — P. 119–129.
7. Functional result in distal radius fractures. Comparison between the severity of the fracture, the treatment of choice and the baseline X-ray parameters / E. Farias Cisneros, F. Gil

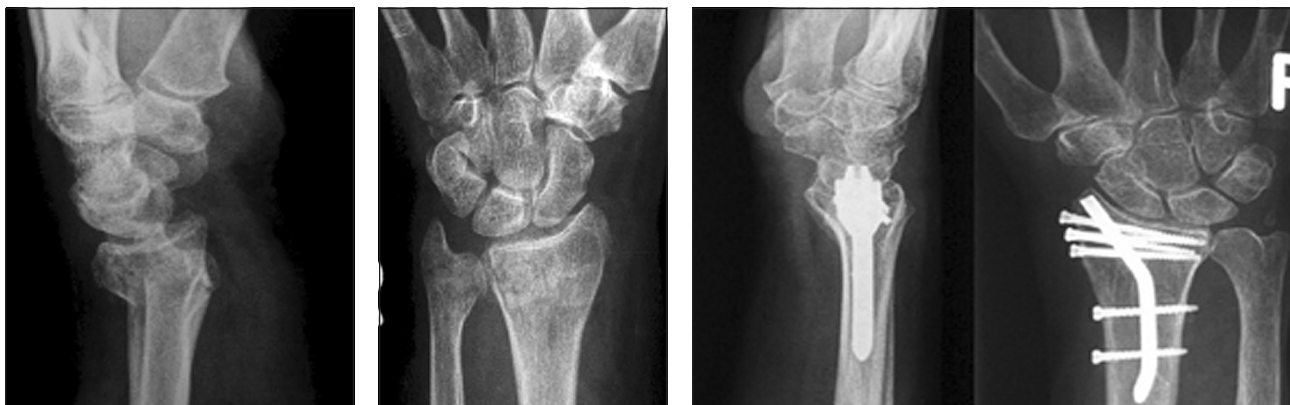


Fig. 6. X-ray evaluation

- Orbezo, C. Trueba Davalillo, R. Jaspeado Reynoso // *Acta Ortop. Mex.* — 2010. — Vol. 24. — P. 220–229.
8. McQueen M. Colles fracture: does the anatomical result affect the final function? / M. McQueen, J. Caspers // *J. Bone Joint Surg.* — 1988. — Vol. 70-A. — P. 649–651.
 9. Comparison of external and percutaneous pin fixation with plate fixation for intra-articular distal radial fractures. A randomized study / F. Leung, Y. K. Tu, W. Y. Chew, S. P. Chow // *J. Bone Joint Surg.* — 2008. — Vol. 90-A. — P. 16–22.
 10. Rizzo M. Comparison of locked volar plating versus pinning and external fixation in the treatment of unstable intraarticular distal radius fractures / M. Rizzo, B. A. Katt, J. T. Carothers // *Hand (N Y).* — 2008. — Vol. 3. — P. 111–117.
 11. Flexor tendon irritations after locked plate fixation of the distal radius with the 3.5 mm T-plate: identification of risk factors / A. Ateschrang, F. Stuby, F. Werdin [et al.] // *Z. Orthop. Unfall.* — 2010. — Vol. 148. — P. 319–325.
 12. Chen N. C. Management of distal radial fractures / N. C. Chen, J. B. Jupiter // *J. Bone Joint. Surg.* — 2007. — Vol. 89-A. — P. 2051–2062.
 13. Wick M. Mid-term results after volar plating of distal radius fractures with a newly designed locking plate / M. Wick, M. Z. Wiesner // *Orthop. Unfall.* — 2007. — Vol. 148. — P. 66–71.
 14. Results of volar locking plate osteosynthesis for distal radial fractures / T. Lattmann, C. Meier, M. Dietrich [et al.] // *J. Trauma.* — 2011. — Vol. 70 (6). — P. 1510–1528.
 15. Jupiter J. B. Operative management of distal radial fractures with 2.4-millimeter locking plates. A multicenter prospective case series / J. B. Jupiter, M. Marent-Huber // *J. Bone Joint. Surg.* — 2009. — Vol. 91-A. — P. 55–65.
 16. Screw prominences related to palmar locking plating of distal radius / T. S. Sugun, N. Karabay, Y. Gurbuz [et al.] // *J. Hand Surg. Eur.* — 2011. — Vol. 36 (4). — P. 320–324.
 17. Volar locking plate implant prominence and flexor tendon rupture / M. Soong, B. E. Earp, G. Bishop [et al.] // *J. Bone Joint. Surg.* — 2011. — Vol. 93-A. — P. 328–335.
 18. Fracture of the distal radius: risk factors for complications after locked volar plate fixation / M. Soong, R. van Leerdam, T. G. Guittton [et al.] // *J. Hand Surg. Am.* — 2011. — Vol. 36. — P. 3–9.
 19. Musgrave D. S. Volar fixation of dorsally displaced distal radius fractures using the 2.4-mm locking compression plates / D. S. Musgrave, R. S. Idler // *J. Hand Surg. Am.* — 2005. — Vol. 30. — P. 743–749.
 20. Intramedullary nailing vs. palmar locked plating for unstable dorsally comminuted distal radius fractures: a biomechanical study / K. J. Burkhart, T. E. Nowak, G. Gradl [et al.] // *Clin. Biomech.* — 2010. — Vol. 25. — P. 771–775.
 21. Harreld K. Intramedullary fixation of distal radius fractures / K. Harreld, Z. Li // *Hand Clin.* — 2010. — Vol. 26. — P. 363–372.
 22. The comprehensive classification of fractures in long bones / M. E. Muller, S. Nazarian, P. Koch [et al.]. — Springer-Verlag, Berlin, 1990. — 200 p.
 23. McQueen M. M. Use of the Hoffman 2 compact external fixator in the treatment of redisplaced unstable distal radial fractures / M. M. McQueen, D. Simpson, C. M. Court-Brown // *J. Orthop. Trauma.* — 1999. — Vol. 13. — P. 501–505.
 24. Castaing J. Recent fractures of the lower extremity of the radius in adults / J. Castaing // *Rev. Chir. Orthop. Reparatrice Appar Mot.* — 1964. — Vol. 50. — P. 581–696.
 25. Gartland J. J. Evaluation of healed Colles' fractures / J. J. Gartland, C. W. Werley // *J. Bone Joint Surg.* — 1951. — Vol. 33-A. — P. 895–907.
 26. X-ray film measurements for healed distal radius fractures / H. J. Kreder, D. P. Hanel, M. McKee [et al.] // *J. Hand Surg. Am.* — 1996. — Vol. 21. — P. 31–39.
 27. McQueen M. M. Redisplaced unstable fractures of the distal radius. A randomised prospective study of bridging versus non-bridging external fixation / M. M. McQueen // *J. Bone Joint Surg.* — 1996. — Vol. 80-B. — P. 665–669.
 28. Tan V. Distal radius fracture fixation with an intramedullary nail / V. Tan, J. Capo, M. Warburton // *Tech Hand Up Extrem. Surg.* — 2005. — Vol. 9. — P. 195–201.
 29. Ilyas A. M. Intramedullary fixation of displaced distal radius fractures: a preliminary report / A. M. Ilyas, J. J. Thoder // *J. Hand Surg. Am.* — 2008. — Vol. 33. — P. 1706–1715.
 30. Internal fixation of distal radius fractures with novel intramedullary implants / K. R. Brooks, J. T. Capo, M. Warburton, V. Tan // *Clin. Orthop. Relat. Res.* — 2006. — Vol. 445. — P. 42–50.
 31. Complications following internal fixation of unstable distal radius fracture with a palmar locking-plate / R. Arora, M. Lutz, A. Hennerbichler [et al.] // *J. Orthop. Trauma.* — 2007. — Vol. 21. — P. 316–322.
 32. Espen D. Fixation of fractures of the distal radius using the «nail-plate» / D. Espen // *Oper. Orthop. Traumatol.* — Vol. 21. — P. 459–471.

Article submitted on 14.02.2014

ЛЕЧЕНИЕ ВНЕСУСТАВНЫХ ПЕРЕЛОМОВ ДИСТАЛЬНОГО ОТДЕЛА ЛУЧЕВОЙ КОСТИ УСТРОЙСТВОМ TARGON DR NAIL (ИНТРАМЕДУЛЛЯРНАЯ ФИКСАЦИЯ)

Георг Градль¹, Штеффи С. И. Фальк², Мартина Вендт¹, Надя Мельш¹, Томас Миттлмайер¹

¹ Отделение травмы и реконструктивной хирургии, Ростокский университет. Германия

² Институт биостатистики, информатики в медицине и возрастных исследований, Ростокский университет. Германия