

УДК 616.728.2-089.843(091)(045)

DOI: <http://dx.doi.org/10.15674/0030-59872021485-95>

Reverse shoulder arthroplasty. History and development prospects

M. O. Korzh ¹, V. B. Makarov ², O. O. Pidgaiska ¹, O. V. Tankut ¹

¹ Sytenko Institute of Spine and Joint Pathology National Academy of Medical Sciences of Ukraine, Kharkiv

² Municipal non-profit enterprise «City Clinical Hospital № 16» of the Dnipro City Council. Ukraine

In elderly patients with a low bone mineral density primary endoprosthesis shoulder joint is one of the methods of surgical treatment. Goal. Perform a historical review of the development of reverse shoulder arthroplasty (RSA) with analysis of biomechanical features of existing implants, their advantages and disadvantages to identify possible areas for further ways of improvement. Methods. Search for scientific information was performed in electronic databases PubMed, ScienceDirect, Google Scholar with a search depth of 30 years. There were selected 68 sources. Results. Unsatisfactory results after shoulder hemiarthroplasty caused in patients with severe damage to the rotator cuff and multifragmental fractures of the proximal humerus using RSA. Endoprosthesis design C. Neer replaced the implants of P. Grammont design, built on the principles: spherical glenoid component, concave support part on the humerus, the center of rotation at the level or medially of the scapular neck, proximal humerus fractures is displaced medially and distally. Medialization of the center of rotation is an unfavorable factor that leads to loss of tension of the deltoid muscle. To eliminate this disadvantages, lateralized hemispheres have been developed, with the help of which stability is achieved, the formation of a defect of the lower edge of the scapular neck is prevented. Their size affects on the volume of movements: the smallest diameters should be used for prevention of soft tissue strain. Note that the use of RSA with a lateralized center of rotation and varus shoulder component brings biomechanics closer shoulder joint to normal anatomical features. Conclusions. The main directions of RSA improvement: conducting biomechanical research to evaluate structures endoprotheses in order to choose the optimal design; introduction of modern additive technologies that will allow to obtain porous components with increased osteointegrative properties; reduce the weight of the hemisphere; improving friction pairs. Key words. Proximal humerus fractures, reverse shoulder arthroplasty.

У пацієнтів похилого та старечого віку на фоні зниження мінеральної щільності кістки первинне ендопротезування плечового суглоба є одним із методів хірургічного лікування. Мета. Провести історичний огляд розвитку реверсивного ендопротезування (RSA) плечового суглоба з аналізом біомеханічних особливостей наявних імплантатів, їхніх переваг і недоліків для визначення можливих напрямів подальшого вдосконалення конструкцій. Методи. Пошук наукової інформації проведений в електронних базах PubMed, ScienceDirect, Google Scholar із глибиною пошуку 30 років. Відібрано 68 джерел. Результати. Незадовільні результати після геміартропластики плечового суглоба обумовили в пацієнтів із важкими ушкодженнями обертальної манжети й багатодіагностичними переломами проксимального відділу плечової кістки (ПВПК) використання RSA. Ендопротези дизайну С. Неєр змінили імплантати конструкції Р. Граммонт, побудовані за принципами: сферичний гленоїдальний компонент, увігнута опорна частина на плечовій кістці, центр ротації на рівні або медіальніше шийки лопатки, ПВПК зміщений медіально та дистальніше. Медіалізація центра обертання є несприятливим чинником, що призводить до втрати напруження дельтоподібного м'яза. Задля усунення цього недоліку розроблено латералізовані гемісфери, за допомогою яких досягається стабільність, попереджується утворення дефекту нижнього краю шийки лопатки. Їхній розмір впливає на обсяг рухів: найменші діаметри слід використовувати для попередження перенапруження м'яких тканин. Зауважимо, що застосування RSA з латералізованим центром обертання та варусним плечовим компонентом наближає біомеханіку плечового суглоба до нормальних анатомічних особливостей. Висновки. Основні напрями вдосконалення RSA: проведення біомеханічних досліджень для оцінювання конструкцій ендопротезів із метою вибору оптимального дизайну; впровадження сучасних адитивних технологій, які дозволяють одержати пористі компоненти з підвищеними остеointегративними властивостями; зменшити вагу гемісфери; вдосконалення пари тертя. Ключові слова. Переломи проксимального відділу плечової кістки, ендопротезування плеча.

Key words. Proximal humerus fractures, reverse shoulder arthroplasty

Introduction

Fractures of the proximal humerus (FPH) account for 5–6 % of all fractures of long skeletal bones, they are found in one third of patients over 65 years, most often in women (70 %) [1, 2]. In young people, FPHs usually occur due to high-energy injuries [3, 4]. In patients older than 50–55 years, FPH, which is diagnosed by low-energy mechanisms of injury, is a sign of osteoporosis. Conservative treatment is the most common method for most patients (67–85 %) with FPH [1–11]. Unstable three- and four-fragment fractures are considered to be indications for FPH surgery in elderly patients. The choice of surgical technique depends on the function of the limb before injury, comorbidities, the level of qualification of the surgeon. Improvements in the technique of open reduction internal fixation (ORIF) have led to the spread of this technique [12]. The use of PHILOS bone plates and intramedullary rods for the osteosynthesis of FPH in young patients with A and B/A fractures and good bone quality allows to obtain positive results of surgical treatment in most cases [13]. In elderly and senile patients, against the background of reduced bone mineral density, ORIF does not provide adequate fixation and leads to negative results [14]. An alternative method of surgery is primary arthroplasty of the shoulder joint, which reduces the period of maladaptation after injury, pain in the first weeks after surgery and improves quality of life.

The aim of the study was to conduct a historical review of the development of reversible shoulder arthroplasty with analysis of biomechanical features of existing implants, their advantages and disadvantages to determine possible areas for further improvement of structures.

Material and methods

The search for scientific information was conducted in electronic databases PubMed, ScienceDirect, Google Scholar with a search depth of 30 years.

Results and discussion

Since the first arthroplasty of the shoulder joint by Jules Emile Pean in 1893 in tuberculosis (according to [15]), several stages have been improved in the design and technique of shoulder arthroplasty. For example, hemiarthroplasty of the shoulder joint [16], proposed by Dr. Charles Neer in 1955 as an operation of despair in avascular necrosis of the humeral head in multifragmentary FPH due to unsatisfactory results is now practically not used [17, 18]. It is noted that there is no statistically significant difference between the results of conservative treatment of mul-

tifragmentary FPH and hemiarthroplasty [19]. Unsatisfactory results after the latter led to the creation of total endoprostheses of the shoulder joint. In-depth study of biomechanics of the shoulder joint, introduction of new materials, improvement of surgical techniques for total shoulder arthroplasty (TSA) allowed to obtain much more positive results in the long term compared to hemiarthroplasty [19, 20]. At the same time, as a result of negative TSA results in patients with severe rotator cuff injuries and multifragmentary FPH, total reversible shoulder arthroplasty (RSA), based on a different biomechanical concept, has gradually developed [20]. TSA has historically been considered the ideal treatment for stage III osteoarthritis of the shoulder joint, but some surgeons now prefer RSA in the elderly and senile with primary osteoarthritis of the shoulder joint and intact rotator cuff due to postoperative (secondary) rupture. Further research and longer-term follow-up are needed to determine the optimal implant in elderly patients with primary osteoarthritis. It is believed that the optimal indications for RSA are multifragmentary fractures on the background of osteoporosis and inoperable damage to the rotating cuff of the shoulder in the case of osteoarthritis of the shoulder joint [22].

In general, total reversible shoulder arthroplasty has been developing for the last 50 years. Initially, RSA was used as a solution in case of damage to the rotating shoulder cuff. The first endoprostheses created by Dr. Charles Neer, failed (Fig. 1, a, c). Revolutionary principles in endoprosthesis design strategy implemented by Dr. Paul Grammont in 1985: spherical glenoid, concave support on the humerus, center of rotation at or below the scapular neck, and the proximal humerus should be displaced medially and distally. Despite the creation of the latest endoprostheses, the principles of RSA by Dr. Paul Grammont still define the development of implants and surgical techniques [15]. In November 2003, the US Food and Drug Administration (FDA) approved the use of RSA. Accordingly, in 2003–2004, the number of RSA transactions in the country began to grow and increases annually [23]. With the increase in the number of surgical procedures using RSA, the number of reports and evidence in support of its use in FPH has increased [24–27]. Persistent problems, failures, and completely unpredictable results with conservative treatment, ORIF, and hemiarthroplasty for FPH, especially in the elderly, have led to a significant increase in RSA use, mainly due to independence from the condition of the rotator cuff muscles.

A number of design features that were previously considered appropriate are no longer used in modern

models of reversible endoprostheses. For example, attempts to reproduce the anatomical center of rotation in an endoprosthesis have resulted in early unsatisfactory results due to increased contact stresses, as well as stresses in the glenoid recess and destabilization of the basic support. Lack of positive results of MARK series endoprostheses developed by Dr. Charles Neer, led to the refusal to use them (Fig. 1) [28].

Further developments to improve the design and stability of the fixation of the glenoid component of the reversible endoprosthesis led to the creation of the Kessel endoprosthesis, which uses one large central glenoid screw for the base support, and the stem is made of polyethylene [30]. In 23 patients who had such implants and who were under observation for at least 5 years, radiologically transparent lines around the glenoid components were observed, and in 6 persons repeated operations were performed up to 3 years of observation [31]. Later, the RSA design was improved by Bailey and Walker (Fig. 2): the glenoid screw was covered with hydroxylapatite, and the center of rotation was moved medially and distally, the shoulder polyethylene stem was replaced with a metal one with a polyethylene liner [31].

The Liverpool reversible endoprosthesis (1969) is similar to the design of an inverted hip implant, the glenoid component and the stem were cemented in the scapula and the polyethylene cup in the proximal humerus [32]. In 1973, Y. Gerard et al. [33] published the results of 6 implants of reversible total endoprostheses of the shoulder joint (Fig. 3, a) with a metal glenoid plate fixed with 2 screws in the blade and with a hole in the center for screwing a metal sphere 20 mm into the plate. The shoulder component was a polyethylene hemispherical cup mounted on a metal stem. All patients achieved stability of the shoulder joint and reduction of pain. However, the active movements did not increase because the design of the prosthesis did not compensate for the function of the rotating cuff.

The idea of a reversible endoprosthesis by J. M. Fenlin (Fig. 3, b) was to create a two-fragment scapular component that could fill two extensions of the spongy cavity extending beyond the articular arch. One of these extensions goes unevenly to the beak-shaped process, the other — down along the edge of the scapula. Its blade anchor was cemented to the blade, as in previous RSA models. To solve the problem of fixation of the glenoid component in the scapula B. Reeves et al. [35] proposed a new design with the reproduction of the normal anatomical center (Fig. 3, c). This endoprosthesis showed higher tear strength than other designs during *in vitro* testing, but its use was also unsuccessful.

In 1985, Dr. Paul Grammont et al. [36] published the first results of arthroplasty with reversible endoprosthesis of the author's design. A distinctive feature of this implant is the medialization of the center of rotation, which allowed to reduce the cutting and shear stresses around the glenoid sphere and the base plate and, accordingly, improve the survival of the endoprosthesis [37]. Dr. Paul Grammont suggested that shifting the center of rotation in the distal direction is necessary to improve the function of the deltoid muscle by tightening it and increasing tone. This concept remains the «cornerstone» in the creation of most reversible shoulder prostheses today. Although medialization of the center of rotation is one of the main principles in the development of reversible endoprostheses of the shoulder joint, if they are installed, a defect of the lower edge of the scapular neck develops, which can lead to instability of the glenoid component of the implant. Based on a multicenter study [38] involving 80 patients who underwent a reversible Grammont Delta shoulder joint prosthesis, minimal pain or no pain was noted in 96 % of cases with good recovery. Instability of the glenoid component occurred in 5 patients, hemispheric and basal plate disorders in 7, development of cervical notch in 49, deep infection in 1. The mean follow-up was 44 months.




Fig. 1. Reversible endoprostheses: a) Mark I (for [29]); b) MARK II; (for [28]); c) Mark III (for [15])

The authors concluded that improving the design of RSA would reduce the number of complications.

Further, medialization of the center of rotation was considered an unfavorable factor, leading to a loss of tension in the deltoid muscle due to disruption of normal rotation around the large tubercle. At the same time, the design features of advanced Grammont-type endoprostheses improve the function of this muscle only by shifting the center of rotation distally. However, excessive displacement in the distal direction is also an insensitive factor for the restoration of function, as it can potentially cause overstretching of the film nerve plexus, increase the «dead space» around the prosthesis and, consequently, increase the risk of infection [39].

To eliminate the negative factors of RSA center of rotation mediation, lateralized hemispheres have been developed, which allow to achieve stability with improved function and prevent the occurrence of a defect of the lower edge of the scapular neck. The stability of the shoulder joint is ensured by shifting the lateral edge of the large tubercle to almost normal anatomical position. Restoration of the distance from the large tubercle to the articular cavity of the scapula and acromial-tuberculous offset allows to maintain the tension of the rotating cuff physio-

logically appropriate. This restores the compression effect of the deltoid muscle when working around a large tubercle. Increasing stability allows the use of varus shoulder components, which, in turn, reduces the risk of scapular impingement [40]. The advantages and disadvantages of medialization and lateralization of the center of rotation are currently under discussion. It is known that the anatomical and functional features of the human shoulder joint are very complex and it is impossible to repeat them perfectly with an artificial implant, and therefore expect maximum recovery of function. Biomechanical research has shown that the varus shoulder component is a major factor in reducing the likelihood of developing scapular impingement [41]. Other important components are the position of the base plate and the lateralization of the center of rotation. This concept is confirmed clinically, as under the conditions of lateralized endoprostheses with varus shoulder component the frequency of defect formation on the lower edge of the scapular neck is from 0 to 10 %, and in classic Grammont endoprostheses with medialization of the center of rotation up to 90 %. S. Guitierrez et al. [39] biomechanically substantiated the increase in the volume of movements under the conditions of lateralized glenosphere. Its low oscillation and downward tilt, varus shoulder component are also significant factors that affect function. However, other authors have shown that the use of varus shoulder components with medialization of the rotational center is unacceptable due to the high frequency of instability of the endoprosthesis components. The use of reversible implants with a lateralized center of rotation improves external rotation due to the increased tension of the preserved rotational cuff muscles and the increase in the radius of rotation before the onset of bone impingement [42].

The most common complications of RSA are instability of the base plate and components, fracture of the acromion, infection, neuropathy of the humeral



Fig. 2. Bailey-Walker reversible endoprosthesis (Stanmore Implants, Elstry, UK) (for [31])

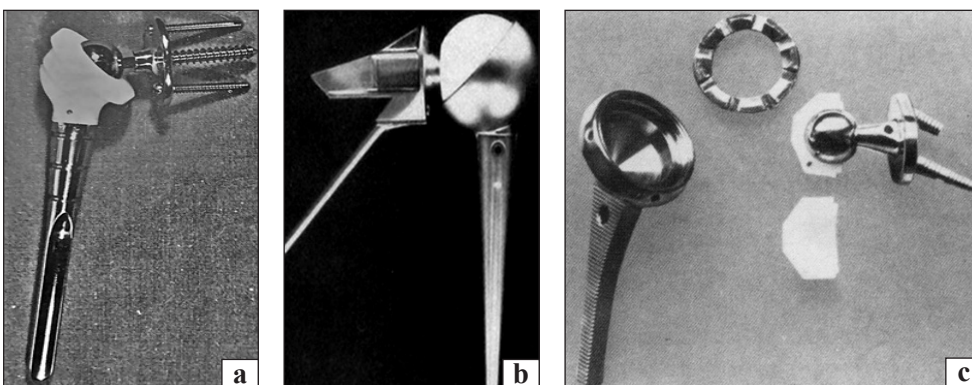


Fig. 3. Reversible endoprostheses: a) Y. Gerard et al. (for [33]); b) J. M. Fenlin (for [34]); c) B. Reeves et al. (for [35])

plexus. The design features of a reversible endoprosthesis significantly affect the risk of complications. Weakness and instability of the base support can occur due to significant shear forces at the bone-implant boundary or loss of structural integration between bone and implant. *In vitro* studies have shown that shear forces at the «bone- endoprosthesis base» boundary are greater at lateralization of the center of rotation than at medialization [43]. In clinical settings, instability of the base plate was determined in 12 % of patients after arthroplasty with implants with a lateralized center of rotation of early design [44]. After extensive use of 4 peripheral locked screws to fix the base support, the frequency of its instability approached 0 %. This indicates that the risk of developing this complication is predictably reduced with increasing stability and rigidity of the primary fixation of the basic support [45]. As the magnitude of the shear forces due to the connection of the base support with the articular process of the blade increases with the lateralization of the center of rotation, it is very important to obtain the primary rigid fixation. The base plate should be installed with the maximum possible degree of compression and additionally fixed with peripheral locked screws [43, 44, 46–49].

Another reason for the development of instability of the basic support is its aseptic shaking due to the formation of a defect along the lower edge of the scapular neck in the case of scapular impingement. The third reason is the wear of polyethylene and the accumulation of inflammatory debris with the development of aseptic lysis of bone [45, 46].

The frequency of instability under the use of endoprostheses with different centers of rotation is approximately the same. Biomechanical studies confirm that the improvement of stability is achieved with an increase in lateral offset, the depth of the liner and the arc of rotation to obtain bone impingement. Lateral offset and bone impingement depend on the diameter of the hemisphere, the center of rotation, and the depth of immersion in the liner — an independent value from the center of rotation [46, 50-53].

Glenosphere size directly affects the volume of movements in the postoperative period. Its smallest diameters should be used to prevent soft tissue strain and, as a result, to increase the destabilizing force on the base support. It can be considered that the use of endoprostheses with a lateralized center of rotation and varus shoulder component brings the biomechanics of the shoulder joint closer to normal anatomical features [46].

It should be noted that among the features of surgical technique, it is advisable to try to suture the ten-

don of the subscapularis muscle either to the proximal humerus, or to the endoprosthesis. Experts believe that this manipulation is necessary because the work of the subscapularis muscle allows to balance the effort of the back of the shoulder girdle muscle. It is necessary to consider that shifting the axis of the glenosphere further downward can reduce the risk of a scapular neck defect, but at the same time, by increasing the tension of the deltoid muscle, it can lead to a fracture. On the contrary, the central location of the glenosphere reduces the risk of fracture of the articular process of the scapula, but increases the risk of scapular impingement [46, 49, 50, 52, 54].

All known reversible endoprostheses of the shoulder joint have certain advantages and disadvantages. The center of rotation in RSA is only one of many factors that determine the function and stability of an artificial shoulder joint. Regardless of the choice of endoprosthesis type, it is always very important to change the anatomy minimally to prevent complications and restore maximum function. Today, most authors suggest the use of reversible endoprostheses of the shoulder joint with lateralization of the center of rotation, which allows to increase the range of motion [43, 44, 46–54].

The key concept of the mechanics of a normal shoulder joint is best described by F. Matsen and S. Lippitt [50, 52]: the greater the depth of the concave surface, the greater the displacement force that will shift the sphere or hemisphere from this concavity for a particular compressive load. In a healthy shoulder joint, the rotator cuff muscles provide a compressive load. Their damage results in an imbalance of muscle tone and instability of the head relative to the cavity [50].

Another important issue in the biomechanics of the shoulder joint is the concept of the central line of the glenoid [52]. In a normal healthy human scapula, the central line is perpendicular to the articular surface of the cavity and is directed on average about 10° back from the plane of the scapula. The central line serves as an axis relative to which the head of the humerus rotates; movements in the shoulder joint and movements of the shoulder blade relative to the chest are interconnected to keep the axis of rotation of the head relative to this line. In case of muscle deficiency or damage to the rotator cuff, wear of the articular surface of the glenoid cavity increases. Ideally, the articular component is located along the centerline of the articular cavity. However, in some cases of loss of bone tissue of the articular cavity of the scapula, the establishment of components in this plane is impossible.

In case of severe or eccentric loss of bone tissue, it is necessary to use either bone plastic or replacement of the defect with porous structures — augmentations of titanium alloys.

The third important biomechanical factor in massive supraspinatus damage is the impingement between the great tubercle and the acromion. In patients who have lost the dynamic stabilizers of the rotator cuff muscles, the humeral head is displaced upward and results in a stop under the acromion. In such cases, the use of RSA helps to neutralize pathological dynamic instability.

Fixation of the components of the reversible endoprosthesis of the shoulder joint has undergone significant changes since Dr. Charles Neer proposed his first designs. Initially, the implants were fixed with cement, later, during the development of endoprosthesis designs, their osteointegration was taken into account. It is achieved under conditions of reliable primary stabilization of the endoprosthesis component to the bone, using a press-fit technique or fixation with screws [53]. For greater osseointegration, the surfaces of the humeral and glenoid components

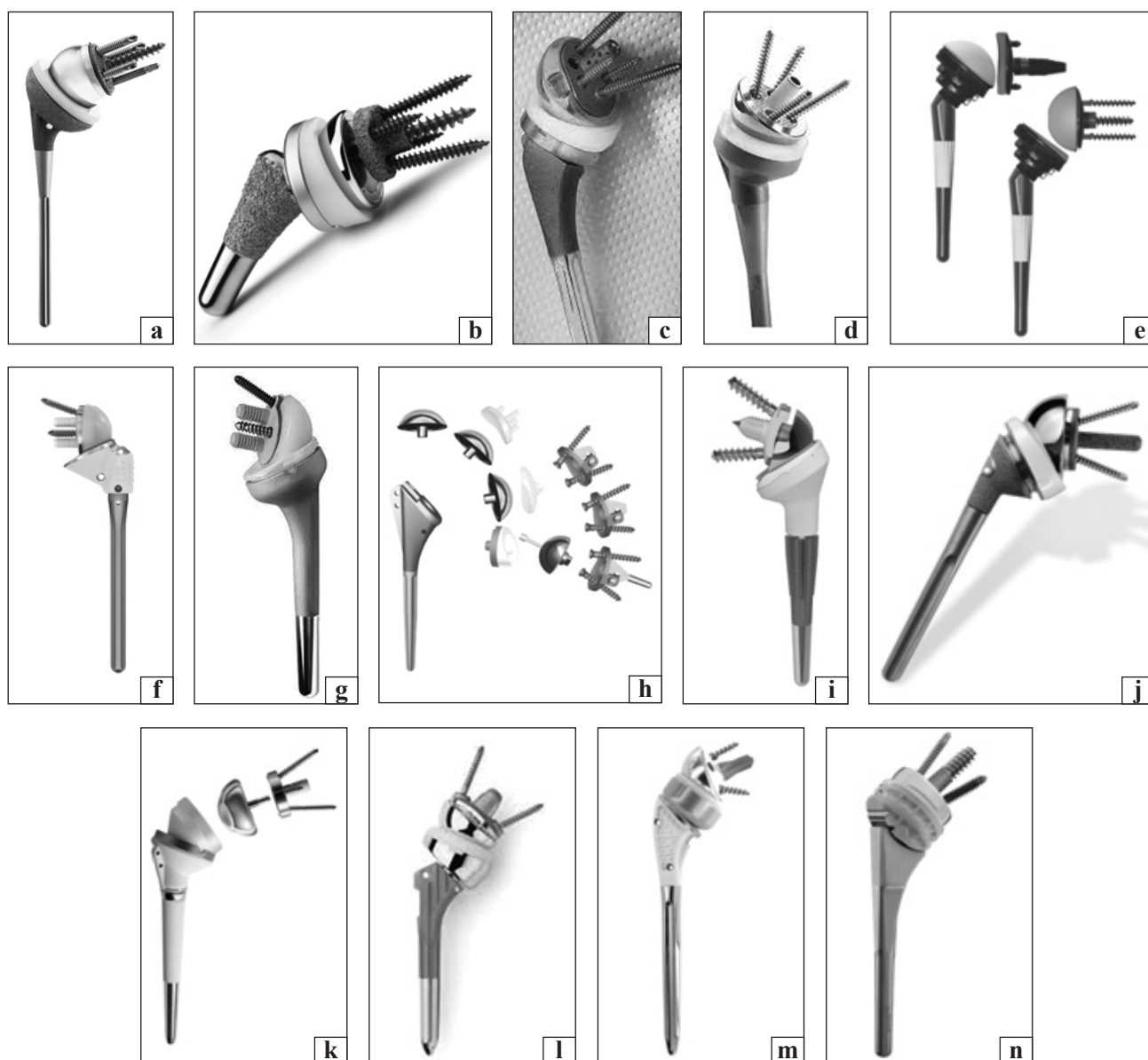


Fig. 4. Modern reversible total shoulder endoprostheses: a) DJO RSP (Vista, CA); b) Zimmer Biomet Comprehensive® Reverse Shoulder System; c) Exactech Equinox (Gainesville, FL); d) Wright Tornier Aequalis (Edina, MN); e) Mirai RSA Permedica, Italy; f) Affinis Inverse, Switzerland old type; g) Affinis Inverse, Switzerland, new type; h) Universal Arrow System (Heimsbrunn, France); i) Lima SMR (Udine, Italy); j) Zimmer Trabecular (Warsaw, IN); k) DePuy Delta III reverse shoulder Warsaw, IN; l) Reverse Anatomical Shoulder Fracture system Zimmer with two types of stem; m) Evolutis UNIC Reverse Shoulder Prosthesis; n) Univers Revers™ Modular Glenoid System Arthrex

are produced with rough coatings with a porosity of 65–80 % [46, 47, 53].

The designs of reversible endoprostheses of the shoulder joint available today (Fig. 4) use a combination of cement to fix the diaphyseal part of the shoulder component and a rough proximal coating to achieve osseointegration. Fixation of the glenoid part of all endoprostheses is only cementless, provided by compression and neutralization of possible shear forces. Compression is performed by a central screw, and peripheral screws counteract the destabilizing shear forces along the contact area, reducing the possibility of micro-mobility to a minimum [48].

Some experts emphasize the importance of placing one of the peripheral screws to fix the base plate at the base of the beak-like process. The study of screw compression of the glenoid component of the two most frequently implanted endoprostheses revealed a 10-fold difference between DJO RSP (2000 N) and Delta III (200 N) [49]. Although biomechanical studies have shown stronger fixation using a 6.5 mm central locked screw in combination with 3.5 mm peripheral unlocked screws for glenoid fixation, instability in the use of such structures has been clinically determined by about 10 % [43, 44].

Further analysis by scanning electron microscopy revealed impaired bone germination between the base support. The use of 5.0 mm central and 3.5 mm peripheral locked screws has been found to reduce the incidence of instability by up to 14 % [54]. The search for optimal positioning and design of the glenoid component continues. P. M. Grammont and E. Baulot [55] believe that the violation of the stability of the base plate by RSA is associated with significant shear stresses passing through the glenoid component, and medialization of the center of rotation will reduce these stress loads [56].

An analysis of the adverse RSA results associated with base plate instability found that in all cases the glenosphere was established with an upward slope [45]. The most uniform distribution of forces that affect the glenoid component occurs during its implantation with a downward slope of 10–15° [57].

RSA is increasingly used in the case of three- and four-fragment FPH for elderly patients, as the number of complications and unsatisfactory results after hemiarthroplasty and ORIF remains high. In particular, the frequency of reoperations after RSA is much lower than 20 years ago, with significant improvements in functional outcomes, especially in the elderly. The patient and the surgeon should be aware that although the function will not be normal, it is usually

suitable for this population with low needs. RSA is also a «rescue surgery» after a failed ORIF [58–61].

Improvements in surgical techniques, implantation technologies, and more accurate patient selection have improved RSA outcomes in the case of STDs. In a retrospective study with a mean follow-up of 35 months involving 52 patients aged 59–89 years with three- and four-fragment FPH who underwent RSA, mostly positive results were obtained [62]. But despite the growth of positive RSA results, the excellent consequences in the case of these FPH are quite rare. It is believed that RSA in FPH achieves 80 % of normal shoulder function, pain relief and the ability to self-care. Comparison of RSA and hemiarthroplasty in the elderly with three- and four-fragment FPH showed that more favorable and reliable functional results are observed in patients after RSA. Although the incidence of complications varies, the number of reoperations is significantly lower in patients after RSA. Unlike hemiarthroplasty, the successful outcome of RSA does not depend on the healing of the large tubercle and the integrity of the rotational cuff of the shoulder [63]. However, restoration of anatomical tubercles may increase the range of motion in the shoulder joint in patients after RSA [64–67]. In a multicenter retrospective study of 898 people with FPHs who underwent RSA, the overall incidence of complications was 12.5 %, revisions — 5%, mortality rate 1 year after surgery — 6%. Instability was the most common complication in 33 % of cases, the formation of a defect of the lower edge of the scapula in 11.9 %. The frequency of revisions after RSA was recorded at the level of 5.1 % versus 12.1 % after ORIF in the period up to 3.6 years after surgery [68].

Conclusions

Positive functional results after RSA and long-term functioning of the reversible endoprosthesis are associated with the design, features of surgical techniques and adequate patient choice.

Summarizing the results of the analyzed scientific publications, we believe that the main directions for improving the design of reversible total endoprosthesis of the shoulder joint are:

- conducting three-dimensional modeling for comparative assessment of stresses arising in a healthy human joint and after implantation of different structures of endoprostheses, glenosphere at different angles, as well as the use of eccentric and elliptical glenospheres;
- introduction of modern additive technologies that allow to obtain both glenoid and shoulder

porous components with increased osseointegrative properties;

– biomechanical and histological experimental studies of porous 3D components of endoprotheses to justify their use in clinical practice.

Improving the design of the reversible endoprosthesis of the shoulder joint, it is necessary to pay attention to the diameter and depth of the concavity of the shoulder component (liner), its inclination relative to the diaphysis of the humerus; the angle of fixation of the glenoid component relative to the axis of the articular process of the scapula and its central axis, the presence of a defect of the glenoid cavity, the importance of central and peripheral fixation of the base plate; reducing the weight of the hemisphere and the features of its fixation to the base plate; improving friction steam to reduce wear and possible lysis of bone tissue.

Conflict of interest. The authors declare no conflict of interest.

References

1. Court-Brown C. M. Epidemiology of adult fractures: a review / C. M. Court-Brown, B. Caesar // *Injury*. — 2006. — Vol. 37 (8). — P. 691–697. — DOI: 10.1016/j.injury.2006.04.130.
2. Trends in surgical management and costs for operative treatment of proximal humerus fractures in the elderly / E. K. Hasty, E. W. Jernigan, A. Soo [et al.] // *Orthopedics*. — 2017. — Vol. 40 (4). — P. 641–647. — DOI: 10.3928/01477447-20170411-03.
3. Proximal humerus fractures in the elderly: concomitant fractures and management / K. Zachariassen, B. R. Dart, E. Ablah [et al.] // *Kansas Journal of Medicine*. — 2020. — Vol. 13. — P. 101–105.
4. Fractures in older adults. A view of the future / C. M. Court-Brown, A. D. Duckworth, N. D. Clement, M. M. McQueen // *Injury*. — 2018. — Vol. 49 (12). — P. 2161–2166. — DOI: 10.1016/j.injury.2018.11.009.
5. Rate of proximal humeral fractures in older Finnish women between 1970 and 2007 / P. Kannus, M. Palvanen, S. Niemi [et al.] // *Bone*. — 2009. — Vol. 44 (4). — P. 656–659. — DOI: 10.1016/j.bone.2008.12.007.
6. Update in the epidemiology of proximal humeral fractures / M. Palvanen, P. Kannus, S. Niemi, J. Parkkari // *Clinical Orthopaedics and Related Research*. — 2006. — № 442. — P. 87–92. — DOI: 10.1097/01.bl0.0000194672.79634.78.
7. Kim SH, Szabo RM, Marder RA. Epidemiology of humerus fractures in the United States: nationwide emergency department sample, 2008 / S. H. Kim, R. M. Szabo, R. A. Marder // *Arthritis Care & Research*. — 2012. — Vol. 64 (3). — P. 407–414. — DOI: 10.1002/acr.21563.
8. Conservative treatment, plate fixation, or prosthesis for proximal humeral fracture. A prospective randomized study / A. P. Launonen, V. Lepola, T. Flinkkila [et al.] // *BMC Musculoskeletal Disorders*. — 2012. — Vol. 13. — Article ID: 167. — DOI: 10.1186/1471-2474-13-167.
9. Humeral fractures in the elderly / J. Bell, B. C. Leung, K. F. Spratt [et al.] // *The Journal of Bone and Joint Surgery. American volume*. — 2011. — Vol. 93 (2). — P. 121–131. — DOI: 10.2106/JBJS.I.01505.
10. Clement N. D. The outcome of proximal humeral fractures in the elderly predictors of mortality and function / N. D. Clement, A. D. Duckworth, M. M. McQueen // *The Bone & Joint Journal*. — 2014. — Vol. 96-B (7). — P. 970–977. — DOI: 10.1302/0301-620X.96B7.32894.
11. Proximal humerus fragility fractures: recent trends in nonoperative and operative treatment in the Medicare population / R. J. Han, D. C. Sing, B. T. Feeley [et al.] // *Journal of Shoulder and Elbow Surgery*. — 2016. — Vol. 25 (2). — P. 256–261. — DOI: 10.1016/j.jse.2015.07.015.
12. Does the magnitude of injuries affect the outcome of proximal humerus fractures treated by locked plating (PHILOS)? / T. Berk, S. Halvachizadeh, F. Bellmann [et al.] // *European Journal of Trauma and Emergency Surgery*. — 2020. — DOI: 10.1007/s00068-020-01451-9.
13. Long-term follow-up after MIPO Philos plating for proximal humerus fractures / Y. Frima, C. Michelitsch, R. B. Beks [et al.] // *Archives of Orthopaedic and Trauma Surgery*. — 2019. — Vol. 139 (2). — P. 203–209. — DOI: 10.1007/s00402-018-3063-1.
14. Kim DY, Kim TY, Hwang JT. PHILOS plate fixation with polymethyl methacrylate cement augmentation of an osteoporotic proximal humerus fracture / D. Y. Kim, T. Y. Kim, J. T. Hwang // *Clinics in Shoulder and Elbow*. — 2020. — Vol. 23 (3). — P. 156–158. — DOI: 10.5397/cise.2020.00206.
15. Flatow E. L. A history of reverse total shoulder arthroplasty / E. L. Flatow, A. K. Harrison // *Clinical Orthopaedics and Related Research*. — 2011. — Vol. 469 (9). — P. 2432–2439. — DOI: 10.1007/s11999-010-1733-6.
16. Neer C. S. Articular replacement for the humeral head / C. S. Neer // *The Journal of Bone and Joint Surgery. American volume*. — 1955. — Vol. 37. — P. 215–228. — DOI: 10.2106/00004623-195537020-00001.
17. Reverse shoulder arthroplasty versus hemiarthroplasty for treatment of proximal humerus fractures / W. W. Schairer, B. U. Nwachukwu, S. Lyman [et al.] // *Journal of Shoulder and Elbow Surgery*. — 2015. — Vol. 24 (10). — P. 1560–1566. — DOI: 10.1016/j.jse.2015.03.018.
18. Use and cost of reverse shoulder arthroplasty versus hemiarthroplasty for acute proximal humerus fractures / C. S. Politzer, A. Bala, T. M. Seyler [et al.] // *Orthopedics*. — 2020. — Vol. 43 (2). — P. 119–125. — DOI: 10.3928/01477447-20200107-06.
19. Functional results of hemi- and total shoulder arthroplasty according to diagnosis and patient age at surgery / B. Sowa, H. Thierjung, M. Bühlhoff [et al.] // *Acta Orthopaedica*. — 2017. — Vol. 88 (3). — P. 310–314. — DOI: 10.1080/17453674.2017.1280656.
20. Anatomic total shoulder arthroplasty for primary glenohumeral osteoarthritis is associated with excellent outcomes and low revision rates in the elderly / R. A. Jensen, J. Tangtiphai-boontana, E. Marigi [et al.] // *Journal of Shoulder and Elbow Surgery*. — 2021. — Vol. 30 (7S). — P. S131–S139. — DOI: 10.1016/j.jse.2020.11.030.
21. Polisetty T. S. Value analysis of anatomic and reverse shoulder arthroplasty for glenohumeral osteoarthritis with an intact rotator cuff / T. S. Polisetty, R. Colley, J. C. Levy // *The Journal of Bone and Joint Surgery. American volume*. — 2021. — Vol. 103 (10). — P. 913–920. — DOI: 10.2106/JBJS.19.01398. PMID: 33983149.
22. Anatomic and reverse shoulder arthroplasty in patients 70 years of age and older: a comparison cohort at early to midterm follow-up / R. K. Poondla, M. M. Sheth, L. B. Heldt [et al.] // *Journal of Shoulder and Elbow Surgery*. — 2021. — Vol. 30 (6). — P. 1336–1343. — DOI: 10.1016/j.jse.2020.08.030.
23. Increasing incidence of shoulder arthroplasty in the United States / Sjo H. Kim, B. L. Wise, Y. Zhang, R. M. Szabo // *The Journal of bone and joint surgery. American volume*. — 2011. — Vol. 93 (24). — P. 2249–2254. — DOI: 10.2106/JBJS.J.01994.
24. Reverse total shoulder arthroplasty for acute head-splitting, 3- and 4-part fractures of the proximal humerus in the elderly / F. Grubhofer, K. Wieser, D. C. Meyer [et al.] // *Journal*

- of Shoulder and Elbow Surgery. — 2016. — Vol. 25. — P. 1690–1698. — DOI: 10.1016/j.jse.2016.02.024.
25. Uncemented reverse total shoulder arthroplasty as initial treatment for comminuted proximal humerus fractures / J. O. Wright, A. Ho, J. Kalma [et al.] // *Journal of Orthopaedic Trauma*. — 2019. — Vol. 33 (7). — P. e263–e269. — DOI: 10.1097/BOT.0000000000001465.
 26. Reverse shoulder arthroplasty for proximal humeral fractures: outcomes comparing primary reverse arthroplasty for fracture versus reverse arthroplasty after failed osteosynthesis / F. S. Shannon, E. R. Wagner, M. T. Houdek [et al.] // *Journal of Shoulder and Elbow Surgery*. — 2016. — Vol. 25 (10). — P. 1655–1660. — DOI: 10.1016/j.jse.2016.02.012.
 27. Reverse shoulder arthroplasty for complex fractures of the proximal humerus in elderly patients: impact on the level of independency, early function, and pain medication / F. Wolfensperger, P. Grüniger, M. Dietrich [et al.] // *Journal of Shoulder and Elbow Surgery*. — 2017. — Vol. 26 (8). — P. 1462–1468. — DOI: 10.1016/j.jse.2017.01.021.
 28. Zilber S. Shoulder arthroplasty: historical considerations / S. Zilber // *The Open Orthopaedics Journal*. — 2017. — Vol. 11. — P. 1100–1107. — DOI: 10.2174/1874325001711011100.
 29. Neer C. S. II. Glenohumeral arthroplasty / C. S. Neer II (ed) // *Shoulder Reconstruction*. — Philadelphia: W. B. Saunders, 1990. — 149 p.
 30. Kessel L. Prosthetic replacement of shoulder joint: preliminary communication / L. Kessel, I. Bayley // *Journal of the Royal Society of Medicine*. — 1979. — Vol. 72 (10). — P. 748–752.
 31. The Kessel prosthesis in total shoulder arthroplasty. A five-year experience / L. A. Broström, R. Wallensten, E. Olsson, D. Anderson // *Clinical Orthopaedics and related Research*. — 1992. — No. 277. — P. 155–160.
 32. Blauth W. Zur Geschichte der Arthroplastik [Notes on the history of arthroplasty (author's transl)] / W. Blauth, K. Donner // *Zeitschrift für Orthopädie und ihre Grenzgebiete*. — 1979. — Vol. 117 (6). — P. 997–1006. (in German)
 33. Gerard Y. Une prothèse totale d'épaule [A complete shoulder prosthesis] / Y. Gerard, J. P. Leblanc, B. Rousseau // *Chirurgie*. — 1973. — Vol. 99 (9). — P. 655–663. (in French).
 34. Fenlin J. M. Jr. Total glenohumeral joint replacement / J. M. Fenlin Jr. // *The Orthopedic Clinics of North America*. — 1975. — Vol. 6 (2). — P. 565–583.
 35. A total shoulder endoprosthesis / B. Reeves, B. Jobbins, D. Dowson, V. Wright // *Engineering of Medicine*. — 1974. — Vol. 1. — P. 64–67. — DOI: 10.1243/EMED_JOUR_1971_001_028_02.
 36. Study and development of a new shoulder prosthesis / P. Grammont, P. Trouilloud, J. Laffay, X. Deries // *Rhumatologie*. — 1987. — Vol. 39. — P. 407–418. (in French).
 37. Grammont reverse prosthesis: design, rationale, and biomechanics / P. Boileau, D. J. Watkinson, A. M. Hatzidakis [et al.] // *Journal of Shoulder and Elbow Surgery*. — 2005. — Vol. 14 (Suppl 1). — P. 147S–161S
 38. Grammont inverted total shoulder arthroplasty in the treatment of glenohumeral osteoarthritis with massive rupture of the cuff. Results of a multicentre study of 80 shoulders / F. Sirveaux, L. Favard, D. Oudet [et al.] // *The Journal of Bone and Joint Surgery. British volume*. — 2004. — Vol. 86 (3). — P. 388–395. — DOI: 10.1302/0301-620x.86b3.14024.
 39. Range of impingement-free abduction and adduction deficit after reverse shoulder arthroplasty. Hierarchy of surgical and implant-design-related factors / S. Gutiérrez, C. A. Comiskey 4th, Z. P. Luo [et al.] // *The Journal of Bone and Joint Surgery. American volume*. — 2008. — Vol. 90 (12). — P. 2606–2615. — DOI: 10.2106/JBJS.H.00012.
 40. Polyethylene wear in retrieved reverse total shoulder components / J. S. Day, D. W. MacDonald, M. Olsen [et al.] // *Journal of Shoulder and Elbow Surgery*. — 2012. — Vol. 21 (5). — P. 667–674. — DOI: 10.1016/j.jse.2011.03.012.
 41. Reverse shoulder arthroplasty components and surgical techniques that restore glenohumeral motion / N. A. Virani, A. Cabezas, S. Gutiérrez [et al.] // *Journal of Shoulder and Elbow Surgery*. — 2013. — Vol. 22 (2). — P. 179–187. — DOI: 10.1016/j.jse.2012.02.004.
 42. Reverse shoulder arthroplasty for the treatment of rotator cuff deficiency: a concise follow-up, at a minimum of five years, of a previous report / D. Cuff, R. Clark, D. Pupello, M. Frankle // *The Journal of Bone and Joint Surgery. American volume*. — 2012. — Vol. 94 (21). — P. 1996–2000. — DOI: 10.2106/JBJS.K.01206.
 43. Frankle M. Rationale and biomechanics of the reverse shoulder prosthesis: the American experience / M. Frankle (ed.) // *Rotator Cuff Deficiency of the Shoulder*. — New York: Thieme, 2008. — P. 76–104.
 44. The reverse shoulder prosthesis for glenohumeral arthritis associated with severe rotator cuff deficiency: a minimum two-year follow-up study of sixty patients / M. Frankle, S. Siegal, D. Pupello [et al.] // *The Journal of Bone and Joint Surgery. American volume*. — 2005. — Vol. 87 (8). — P. 1697–1705. — DOI: 10.2106/JBJS.D.02813.
 45. Coronal plane tilt angle affects risk of catastrophic failure in patients treated with a reverse shoulder prosthesis / M. Frankle, S. Siegal, D. Pupello [et al.] // *Journal of Shoulder and Elbow Surgery*. — 2007. — Vol. 16 (2). — Article ID: e46. — DOI: 10.1016/j.jse.2007.02.096.
 46. How reverse shoulder arthroplasty works / M. Walker, J. Brooks, M. Willis, M. Frankle // *Clinical Orthopaedics and Related Research*. — 2011. — Vol. 469 (9). — P. 2440–2451. — DOI: 10.1007/s11999-011-1892-0.
 47. Tissue response to porous tantalum acetabular cups: a canine model / J. D. Bobyn, K. K. Toh, S. A. Hacking [et al.] // *The Journal of Arthroplasty*. — 1999. — Vol. 14 (3). — P. 347–354. — DOI: 10.1016/s0883-5403(99)90062-1.
 48. Initial glenoid component fixation in 'reverse' total shoulder arthroplasty: a biomechanical evaluation / M. Harman, M. Frankle, M. Vasey, S. Banks // *Journal of Shoulder and Elbow Surgery*. — 2005. — Vol. 14. — P. 162S–167S. — DOI: 10.1016/j.jse.2004.09.030.
 49. Optimizing glenosphere position and fixation in reverse shoulder arthroplasty, Part Two: the three-column concept / C. S. Humphrey, J. D. Kelly 2nd, T. R. Norris // *Journal of Shoulder and Elbow Surgery*. — 2008. — Vol. 17 (4). — P. 595–601. — DOI: 10.1016/j.jse.2008.05.038.
 50. Matsen F. Principles of glenohumeral stability / F. Matsen // F. Matsen, S. Lippitt, S. DeBartolo (eds.) // *Shoulder Surgery: Principles and Procedures*. — Philadelphia: WB Saunders, 2004. — P. 83.
 51. Neer C. S. 2nd. Cuff-tear arthropathy / C. S. Neer 2nd, E. V. Craig, H. Fukuda // *The Journal of Bone and Joint Surgery. American volume*. — 1983. — Vol. 65 (9). — P. 1232–1244.
 52. Matsen F. Principles of glenoid concavity / F. Matsen, S. Lippitt, // F. Matsen, S. Lippitt, S. DeBartolo (eds.) // *Shoulder Surgery: Principles and Procedures*. — Philadelphia: WB Saunders, 2004. — P. 89.
 53. In vivo skeletal responses to porous-surfaced implants subjected to small induced motions / M. Jasty, C. Bragdon, D. Burke [et al.] // *The Journal of Bone and Joint Surgery. American volume*. — 1997. — Vol. 79 (5). — P. 707–714. — DOI: 10.2106/00004623-199705000-00010.
 54. Initial glenoid component fixation in 'reverse' total shoulder arthroplasty: a biomechanical evaluation / M. Harman, M. Frankle, M. Vasey, S. Banks // *Journal of Shoulder and Elbow Surgery*. — 2005. — Vol. 14. — P. 162S–167S. — DOI: 10.1016/j.jse.2004.09.030.
 55. Grammont P. M. Delta shoulder prosthesis for rotator cuff rupture / P. M. Grammont, E. Baulot // *Orthopedics*. — 1993. — Vol. 16 (1). — P. 65–68.

56. Grammont reverse prosthesis: design, rationale, and biomechanics / P. Boileau, D. J. Watkinson, A. Hatzidakis, F. Balg // *Journal of Shoulder and Elbow Surgery*. — 2005. — Vol. 14 (Suppl S). — P. 147S–161S. — DOI: 10.1016/j.jse.2004.10.006.
57. Effects of tilt and glenosphere eccentricity on baseplate/bone interface forces in a computational model, validated by a mechanical model, of reverse shoulder arthroplasty / S. Gutiérrez, M. Walker, M. Willis [et al.] // *Journal of Shoulder and Elbow Surgery*. — 2011. — Vol. 20 (5). — P. 732–739. — DOI: 10.1016/j.jse.2010.10.035.
58. Ferrel J. R. Reverse total shoulder arthroplasty versus hemiarthroplasty for proximal humeral fractures: a systematic review / L. R. Ferrel, T. Q. Trinh, R. A. Fischer // *Journal of Orthopaedic Trauma*. — 2015. — Vol. 29 (1). — P. 60–68. — DOI: 10.1097/BOT.0000000000000224.
59. Decreased reoperations and improved outcomes with reverse total shoulder arthroplasty in comparison to hemiarthroplasty for geriatric proximal humerus fractures: a systematic review and meta-analysis / D. C. Austin, M. T. Torchia, N. H. Cozzolino [et al.] // *Journal of Orthopaedic Trauma*. — 2019. — Vol. 33 (1). — P. 49–57. — DOI: 10.1097/BOT.00000000000001321.
60. A cost-effectiveness analysis of reverse total shoulder arthroplasty versus hemiarthroplasty for the management of complex proximal humeral fractures in the elderly / G. G. N. O'Hara, J. D'Cruz [et al.] // *Value Health*. — 2017. — Vol. 20 (3). — P. 404–411. — DOI: 10.1016/j.jval.2016.10.017.
61. Reverse total shoulder arthroplasty for failed open reduction and internal fixation of fractures of the proximal humerus / F. Grubhofer, K. Wieser, D. C. Meyer [et al.] // *Journal of Shoulder and Elbow Surgery*. — 2017. — Vol. 26 (1). — P. 92–100. — DOI: 10.1016/j.jse.2016.05.020.
62. Reverse total shoulder arthroplasty for acute head-splitting, 3- and 4-part fractures of the proximal humerus in the elderly / F. Grubhofer, K. Wieser, D. C. Meyer [et al.] // *Journal of Shoulder and Elbow Surgery*. — 2016. — Vol. 25. — P. 1690–1698. — DOI: 10.1016/j.jse.2016.02.024.
63. Reverse shoulder arthroplasty for proximal humeral fractures: outcomes comparing primary reverse arthroplasty for fracture versus reverse arthroplasty after failed osteosynthesis / S. F. Shannon, E. R. Wagner, M. T. Houdek [et al.] // *Journal of Shoulder and Elbow Surgery*. — 2016. — Vol. 25 (10). — P. 1655–1660. — DOI: 10.1016/j.jse.2016.02.012.
64. Reuther F, Petermann M, Stangl R. Reverse shoulder arthroplasty in acute fractures of the proximal humerus: does tuberosity healing improve clinical outcomes / F. Reuther, M. Petermann, R. Stangl // *Journal of Orthopaedic Trauma*. — 2019. — Vol. 33 (2). — P. 46–51. — DOI: 10.1097/BOT.00000000000001338.
65. Tuberosity healing after reverse shoulder arthroplasty for complex proximal humeral fractures in elderly patients—does it improve outcomes? A systematic review and meta-analysis / N. P. Jain, S. S. Mannan, R. Dharmarajan, A. Rangan // *Journal of Shoulder and Elbow Surgery*. — 2019. — Vol. 28 (3). — P. e78–e91. — DOI: 10.1016/j.jse.2018.09.006.
66. Effect of tuberosity healing on clinical outcomes in elderly patients treated with a reverse shoulder arthroplasty for 3- and 4-part proximal humerus fractures / R. W. Simovitch, C. P. Roche, R. B. Jones [et al.] // *Journal of Orthopaedic Trauma*. — 2019. — Vol. 33 (2). — P. E39–E45. — DOI: 10.1097/BOT.00000000000001348.
67. Reverse shoulder arthroplasty for the treatment of acute complex proximal humeral fractures: influence of greater tuberosity healing on the functional outcomes / C. Torrens, E. Alentorn-geli, F. Mingo [et al.] // *Journal of Orthopaedic Surgery (Hong Kong)*. — 2018. — Vol. 26 (1). — P. 1–7. — DOI: 10.1177/2309499018760132.

The article has been sent to the editors 23.11.2021

REVERSE SHOULDER ARTHROPLASTY. HISTORY AND DEVELOPMENT PROSPECTS

M. O. Korzh¹, V. B. Makarov², O. O. Pidgaiska¹, O. V. Tankut¹

¹ Sytenko Institute of Spine and Joint Pathology National Academy of Medical Sciences of Ukraine, Kharkiv

² Municipal non-profit enterprise «City Clinical Hospital № 16» of the Dnipro City Council. Ukraine

✉ Mykola Korzh, MD, Prof. in Traumatology and Orthopaedics: mykola.korzh47@gmail.com

✉ Vasyl Makarov, MD, PhD in Orthopaedics and Traumatology: vasylnmakarov2010@gmail.com

✉ Olga Pidgaiska, MD, PhD in Traumatology and Orthopaedics: podgayo@yahoo.com

✉ Oleksiy Tankut, MD, PhD in Traumatology and Orthopaedics: tankutmed@gmail.com