

## SHORT REPORTS AND NOTES FROM PRACTICE

УДК 616.728.2-089.843-089.881:004.942](045)

DOI: <http://dx.doi.org/10.15674/0030-59872021258-62>**Complex revision hip arthroplasty for aseptic implant instability with 3D-modeling****O. M. Polivoda, D. S. Chabanenko, G. V. Puhkan, O. O. Vytychak**

PE «Odessa Regional Clinical Hospital». Ukraine

*The increasing number of hip replacement surgeries in the worldwide practice causes the progressive increase in revision cases. The treatment of patients with instability of the hip implants requires the individual approach, taking into account the size of the defect, the loss of bone mass and the structural state of the bone in each case. Objective. To show the technical opportunities of the revision cementless implants in combination with 3D-modeling for the treatment of acetabulum massive defects. Methods. It was shown the clinical case of hip replacement surgery of the patient with the aseptic instability of endoprosthesis components. A 3D-model of the pelvis and femur was created on the basis of the CT scan in order to make an analysis of bone tissue defects and to select the exact size of implant components for revision surgery. Results. It was suggested a standardized methodology of the preoperative examination to make the high-tech operation easier and maximally effective. It is necessary not only to take into account the results of the X-ray analysis, but also to pay attention to all changes in the damaged segments. It was shown that the real plastic model make the work of the surgeon easier during all steps of the treatment. The opportunity to use the standard revision components for the restoration of the complex geometrically shaped bone was demonstrated with the good nearest clinical and radiological and functional results. Conclusions. The success of the revision arthroplasty depends on the carefully preoperative planning, the maximum approximation of the parameters of the artificial joint to the anatomical parameters of the patient and biomechanics of the hip joint. No less important is the individual recovery program during the postoperative period. Key words. Revision arthroplasty, bone defect, 3D-model.*

*Щорічне істотне збільшення кількості операцій первинного ендопротезування кульшових суглобів у світовій практиці призводить до прогресивного підвищення виконаних ревізійних втручань. Лікування пацієнтів із нестабільністю компонентів кульшового суглоба вимагає індивідуального підходу в кожному випадку з урахуванням величини дефекту, втраченої кісткової маси і структурного стану кістки. Мета. Показати технічні можливості ревізійних безцементних імплантатів за умов масивних дефектів кісткової тканини. Методи. Наведено клінічний випадок ревізійного ендопротезування кульшового суглоба в пацієнтки з асептичною нестабільністю компонентів ендопротеза. На підставі результатів КТ створено 3D-модель таза та стегнової кістки для аналізу дефектів кісткової тканини і точного підбору компонентів ендопротеза. Результати. Запропоновано стандартизовану методіку передопераційного обстеження для полегшення та максимальної ефективності високотехнологічної операції. Наголошено на необхідності враховувати всі зміни ушкоджених сегментів, а не лише результати аналізу рентгенограм. Показано, що використання реальної пластикової моделі значно полегшує роботу хірурга на всіх етапах лікування. Продемонстровано можливість використання стандартних ревізійних компонентів для відновлення великих дефектів кістки складної геометричної форми з хорошим найближчим клініко-рентгенологічним і функціональним результатом. Висновки. Успіх ревізійного ендопротезування залежить від ретельного передопераційного планування, максимального наближення параметрів штучного суглоба до анатомічних параметрів пацієнта й біомеханіки кульшового суглоба. Не менш важливою є індивідуальна програма реабілітації в післяопераційному періоді.*

**Key words.** Revision arthroplasty, bone defect, 3D-model

© Polivoda O. M., Chabanenko D. S., Puhkan G. V., Vytychak O. O., 2021

## Introduction

Endoprosthetic replacement is currently the most effective surgery for the treatment of injuries and diseases of the hip joint. This is confirmed by the ever-increasing number of these transactions around the world. The leader is the United States, where, since 2018, more than 800,000 operations are performed annually, and more than 1.5 million per year in the world as a whole [1–3]. It is known that the 15-year survival of the endoprosthesis in the best clinics in Europe and the United States is 85–95 % [4, 5]. The main causes of unsatisfactory results are various types of instability of the components of the endoprosthesis, pain and dysfunction [5].

Aseptic endoprosthesis instability refers to the dysfunction of implants without any mechanical cause or infection. There is a deviation of the dynamic balance at the «bone – implant» boundary in the case of cementless fixation of the endoprosthesis and «bone – cement» in the cement one, which leads to inflammatory reactions in the joint [1, 6, 7].

The load and movement of the endoprosthesis become factors of wear on hinged surfaces and joints, where there is micromovement. The main source of wear products under normal conditions is the bearing surface of the cup, made of ultra-high molecular weight polyethylene (UHMWP). At each stage, many particles are formed, and most of them are less than 1 µm in diameter. The cells of the patient's immune system react to polyethylene particles as foreign material and initiate a complex inflammatory reaction. This response leads to focal bone loss (osteolysis), bone resorption, loosening and/or bone fracture [8–10].

The degree of destruction of bone tissue depends on the method of fixing the components of the endoprosthesis during the audit, its reliability and the term of effective functioning of the endoprosthesis [11, 12].

*The aim of the study:* to show the technical capabilities of revision cementless implants under conditions of massive bone loss.

## Material and methods

The study was approved by the Committee on Bioethics at the municipal non-profit institution «Odesa Regional Clinical Hospital» of Odesa Regional Council (Minutes No. 5 of 19.02.2021). The patient voluntarily signed an informed consent.

A clinical case of revision hip arthroplasty due to aseptic instability of endoprosthesis components is presented. A 3D model of the pelvis and femur was used to assess bone defects and accurately select endoprosthesis components.

## Clinical example

A 51-year-old patient L. was admitted to the orthopedic and traumatology department of the municipal non-profit institution «Odesa Regional Clinical Hospital» of Odesa Regional Council with pain and restriction of movement in the left hip joint, impaired leaning ability of the left lower extremity. According to the patient, there was not any recent injury.

According to history, the patient since birth has suffered from dysplasia of both hip joints. In 2008, due to the progressive course of the dystrophic-degenerative process, pain, dysfunction in the left hip joint, total endoprosthesis (TEP) replacement was performed. In 2015, due to pain and dysfunction in the right lower extremity, a cementless TEP of the right hip joint with bone grafting of the upper wall of the acetabulum was performed.

At the time of her visit, the patient was moving with crutches, with a moderate load on the left lower limb. Soft tissues of the left hip joint were without visible signs of inflammation. Moderate soft tissue edema of the left hip was found. The contours of the soft tissues were slightly smoothed. Reduction of the left lower limb by 2 cm. Active and passive movements in the left hip joint were limited due to pain. There were no vascular or neurological abnormalities in the left lower extremity.

The protrusion of the acetabular component with its complete displacement and defect of the bone tissue of the acetabulum type 3B according to Paprosky, of the femur type 1A according to Paprosky were determined radiologically (Fig. 1).

## Results and their discussion

To clarify the diagnosis and choose further treatment tactics the patient underwent:

– puncture of the hip joint in 3 areas with subsequent cytological and microbiological studies to

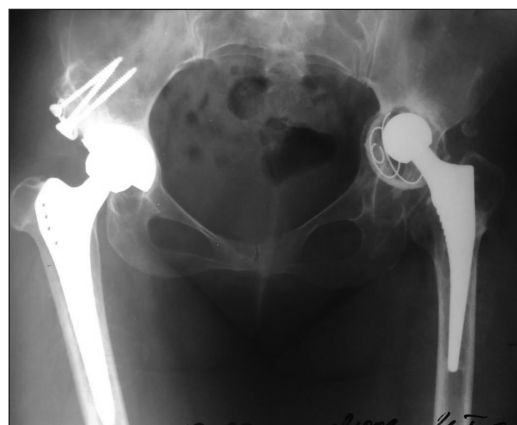

Fig. 1. Radiological image of a patient L. on admission

exclude infectious etiology of the process. The growth of microflora was not detected;

- analysis of laboratory parameters: C-reactive protein (negative) and ESR (15);

- CT of the pelvis with 3D-reconstruction and creation of a plastic copy [13] of the pelvis and femur of the patient (Fig. 2).

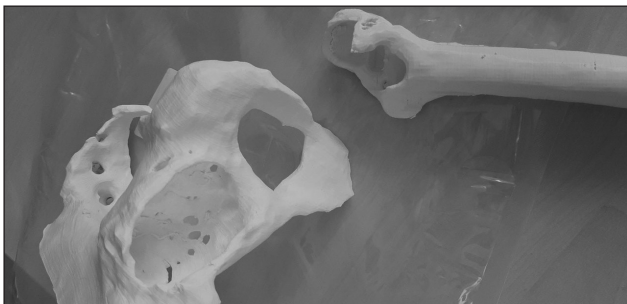
Examination showed thinning of the upper wall of the acetabulum with the presence of multiple cysts, some of which were pervasive. Due to a large defect of the posteroinferior segment, the acetabulum acquired an ellipsoidal shape with anterior-posterior dimensions of 67 mm, upper-lower of 49 mm.

The final diagnosis was made as follows: bilateral dysplastic coxarthrosis of the third degree. Condition

after TEP of the right hip joint with bone autoplasty of the upper wall of the acetabulum (2015). Aseptic instability of left hip endoprosthesis components, condition after TEP (2008).

Preoperative period involved several main stages:

- assessment of the general condition of the patient taking into account the expected extremely traumatic surgery;



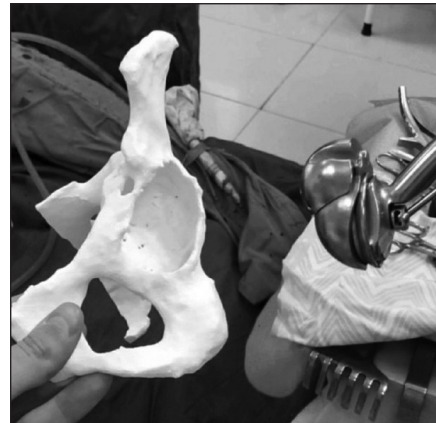
**Fig. 2.** CT of the pelvis with 3D-reconstruction of the femur



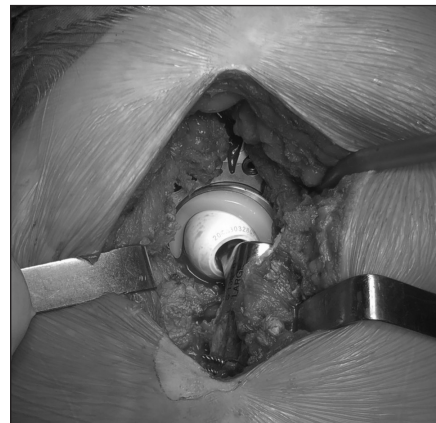**Fig. 3.** Modular revision system



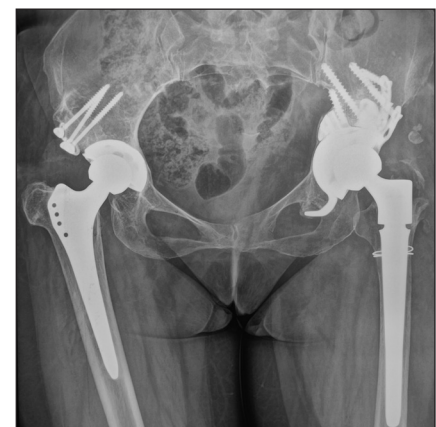**Fig. 4.** Modular cementless revision leg



**Fig. 5.** Selection of the acetabular component using a 3D model



**Fig. 6.** Intraoperative photo



**Fig. 7.** Radiological image of a patient L. after arthroplasty

- laboratory puncture (multiple) diagnosis of the septic nature of instability;
- analysis of radiographic images of the pelvis and hip joints;
- CT with subsequent creation of a 3D model of polymer using 3D printing.
- selection of appropriate serial components of the endoprosthesis according to the 3D model of the pelvis and femur: acetabular component — a modular revision mechanical system made by «trabecular titanium» technology, which consists of an inspection cup and trabecular augment (Fig. 3). If necessary, together with the acetabular component, an angular spacer is used, i. e. an implant that provides a possibility to change the position of the liner relative to the cup to correct the inclination angle (10° or 20°) and add side shifting (5 mm) to restore the center of rotation (Fig. 3). The femoral component is a modular cementless inspection leg (Fig. 4).

After preoperative preparation, the patient under spinal anesthesia in the lateral position underwent anterior external access to the hip joint. Samples were taken for bacteriological and cytological analysis from the joint cavity. The audit revealed a significant amount of scar tissue, instability of the acetabular and femoral components of the endoprosthesis, which were removed.

Visually, the bone defects corresponded to 3D models of the pelvis and femur. A trial acetabular component was selected (Fig. 5).

Restoration of the defects of the acetabulum was made with a small crumb of auto- and allogene. The acetabular component with augment was installed and fixed with spongy screws. To increase the stability of the head in the cup, the acetabular tilt angle was corrected by a 20° spacer. A polyethylene liner was installed.

The femoral rasp prepared the bed for the femoral component of the endoprosthesis. Due to the thin cortical layer of the femur, the proximal part of the femur was strengthened with cerclages. A cementless modular femoral component was installed. The endoprosthesis head was selected. The thigh was straightened (Fig. 6).

As a result of the audit TEP, a sufficient amount of movement was achieved. The length of the lower extremities was the same. X-ray control was performed (Fig. 7).

Postoperative wound healing was by the primary tension. Starting from the 10th day after surgery and for the next 3 months. the patient was on rehabilitation treatment according to an individual program in the rehabilitation sanatorium of Odesa.

## Conclusions

A significant annual increase in the number of primary hip arthroplasty operations in the world leads to a progressive increase in revision interventions. Instability of the hip arthroplasty requires individual approach to each patient taking into account the size of the defect, lost bone mass and bone condition. This example illustrates the facilitation of the surgeon's work due to preoperative planning using 3D-reconstruction of the pelvis and femur based on CT results.

The success of revision arthroplasty depends on careful preoperative planning, the maximum approximation of the artificial joint to the anatomical parameters of the patient, as well as the biomechanics of the hip joint. No less important is the individual mode of rehabilitation of the patient in the postoperative period.

**Conflict of interest.** The authors declare no conflict of interest.

## References

1. Filippenko, V. A., & Korzh, N. A. (2015). Endoprosthetics of the hip joint. Kharkiv: Collegium.
2. How long does a hip replacement last? A systematic review and metaanalysis of case series and national registry reports with more than 15 years of follow-up / J. T. Evans, J. P. Evans, R. W. Walker [et al.] // *The Lancet*. — 2019. — Vol. 393 (10172). — P. 647–654. — DOI: 10.1016/S0140-6736(18)31665-9.
3. What are the causes for failures of primary hip arthroplasties in France? C. Delaunay, M. Hamadouche, J. Girard [et al.] // *Clinical Orthopaedics and Related Research*. — 2013. — Vol. 471 (12). — P. 3863–3869. — DOI: 10.1007/s11999-013-2935-5.
4. Paprosky W. G. Acetabular defect classification and surgical reconstruction in revision arthroplasty / W. G. Paprosky, P. G. Perona, J. M. Lawrence / *Journal of Arthroplasty*. — 1994. — Vol. 9 (1). — P. 33-44. — DOI: 10.1016/0883-5403(94)90135-x
5. Revision total hip arthroplasty: Addressing acetabular bone loss / C. Reid, G. P. Grobler, B. J. Dower [ et al.] // *SA Orthopaedic Journal*. — 2012. — Vol. 11 (3). — P. 34–46.
6. Kosyakov, A. N. (2016). *Essays on surgery of the hip joint*. 2<sup>nd</sup> ed. Kiev.
7. Gaiko, G. V., Torchinsky, V. P. & Sulima, O. M. (2014). Errors and complications of revision prosthetics in patients with aseptic instability of the acetabular component of the hip arthroplasty. *Trauma*, 15(1).
8. Korzh, M. O., Filippenko, V. A., & Tankut, V. O. (2017). Modern tendencies of using friction pairs in human joint endoprostheses (review of literature and own researches). *Journal of the National Academy of Medical Sciences of Ukraine*, 23(3–4), 247–255
9. Massin P. Wear products of total hip arthroplasty: The case of polyethylene / P. Massin, S. Achour // *Morphologie*. — 2017. — Vol. 101 (332). — P. 1–8. — DOI: 10.1016/j.morpho.2016.06.001.
10. The relationship between polyethylene wear and periprosthetic osteolysis in total hip arthroplasty at 12 years in a randomized controlled trial cohort / J. A. Broomfield, T. T. Malak, G. E. Thomas [et al.] // *The Journal of Arthroplasty*. — 2017. — Vol. 32 (4). — P. 1186–1191. — DOI: 10.1016/j.arth.2016.10.037.
11. Revell P. A. The combined role of wear particles, macrophages and lymphocytes in the loosening of total joint prostheses // *Journal of the Royal Society, Interface*. — 2008. — Vol. 5 (28). — P. 1263–1278. — DOI: 10.1098/rsif.2008.0142.

12. Marsh A. C. Long-term performance and failure of orthopedic devices / A. C. Marsh, N. P. Chamorro, Xanthippi Chatzistavrou // *Bone Repair Biomaterials* / Eds.: Kendall Pawelec, J. A. Planell. — 2<sup>nd</sup> Edition. — Woodhead Publishing, 2018. — P. 379–403.
13. Three-dimensional models in planning of revision hip arthroplasty with complex acetabular defects / G. M. Kavalerskiy, V. Y. Murylev, Y. A. Rukin [et al.] // *Indian Journal of Orthopaedics*. — 2018. — Vol. 52 (6). — P. 625–630. — DOI: 10.4103/ortho.IJOrtho\_556\_16.

The article has been sent to the editors 22.03.2021

---

## COMPLEX REVISION HIP ARTHROPLASTY FOR ASEPTIC IMPLANT INSTABILITY WITH 3D-MODELING

O. M. Polivoda, D. S. Chabanenko, G. V. Puhkan, O. O. Vytychak

PE «Odessa Regional Clinical Hospital». Ukraine

- ✉ Diomyd Chabanenko, DMSci in Traumatology and Orthopaedics: raisaozz@gmail.com
- ✉ Oleksandr Polivoda, MD, Prof. in Traumatology and Orthopaedics: polendos73@gmail.com
- ✉ Grigory Puhkan, MD: puhkangrigorij@gmail.com
- ✉ Oleh Vytychak, MD: Vitichak1993@gmail.com