

УДК 616.718.5/6-001.47-089.844(045)

DOI: <http://dx.doi.org/10.15674/0030-59872021251-57>

## Combined soft tissue plastics in treatment of the leg infected necrotic lesions

I. G. Bets <sup>1</sup>, O. Ye. Vyrva <sup>1</sup>, G. V. Bets <sup>2</sup>

<sup>1</sup> Sytenko Institute of Spine and Joint Pathology National Academy of Medical Sciences of Ukraine, Kharkiv

<sup>2</sup> KNP «City Multidisciplinary Hospital № 18», Kharkiv. Ukraine

*Anatomical features of the leg create prerequisites for the occurrence of severe damage to bone-soft structures with the further development of infection-necrotic complications and osteomyelitis. A difficult problem is the development of infected soft tissue defects. Objective. To study the effectiveness of the use of plastic surgical technologies using skin-fascial and muscular patches based on angiosomal concept by Taylor & Palmer. Methods. Treatment results analysis of 3 patients with necrotic defects of the leg soft tissues. All patients initially received high-energy different sites fractures of the leg bones and they were given metalosteosynthesis using plates. In all cases, treatment was complicated by the occurrence of trophic disorders with infected full-layer defects of soft tissues that did not heal. Results. According to the angiosomal Taylor's & Palmer's theory, the human body is divided into 40 three-dimensional zones that combine skin with subordinate fiber and muscles, and have clear limits of blood supply to one nourishing artery. Full-haired soft-blooded patches, taking into account areas of angiosomes, are supplied throughout the plane and to the full depth, which guarantees much better results at the transplant site. The use of traditional plastics technologies in study group patients, on previous treatment did not lead to positive results, and the use of combined plastics based on the angiosomes concept allowed to obtain 100 % positive results, with complete healing of the foci of infection and the absence of relapses. Conclusions. A new stage in the development of plastic surgery, based on the angiosomes theory of human body structure by the blood supply to Taylor & Palmer, is promising for use in traumatology orthopaedics. The experience of using angiosomal patches for plastics of infected defects of the leg soft tissues has proved the high efficiency of this technology, which confirms the expediency of continuing research into the angiosomal theory in the treatment of such pathology another sites. Retrospective analysis of the etiology and pathogenesis for the leg tissues post-traumatic infected defects can be used to correct fracture treatment tactics in order to avoid the development of such complications. Key words. Leg, fractures, complications, infected necrotic tissue defects, angiosomes, plastic surgery.*

*Анатомічні особливості гомілки створюють передумови для виникнення тяжких ушкоджень кістково-м'якотканинних структур із подальшим розвитком інфекційно-некротичних ускладнень та остеомиєліту. Важкою проблемою є розвиток інфікованих дефектів м'яких тканин. Мета. Вивчити ефективність використання пластичних хірургічних технологій зі застосуванням шкірно-фасціальних і м'язових шматків на основі концепції ангіосом Taylor і Palmer. Методи. Проаналізовано результати лікування 3 пацієнтів із некротичними дефектами м'яких тканин гомілки. Усі хворі первинно отримали високоенергетичні переломи кісток гомілки різної локалізації та їм було проведено накістковий металоостеосинтез. У всіх випадках лікування ускладнилось виникненням трофічних розладів з інфікованими повношаровими дефектами м'яких тканин гомілки, які не загоювалися. Результати. Згідно з теорією ангіосом Taylor і Palmer, тіло людини розподілено на 40 тривимірних зон, які поєднують у собі шкіру з підлеглою жирною клітковиною та м'язами, мають чіткі межі кровопостачання однією живлячою артерією. Повношарові м'якотканинні шматки з урахуванням ділянок ангіосом кровопостачаються на всій площині та на всю глибину, що гарантує краще приживлення на місці пересадки. Застосування традиційних технологій пластики в пацієнтів на попередніх етапах лікування не призвело до позитивних результатів, а використання комбінованої пластики на основі концепції ангіосом дозволило отримати 100 % позитивних результатів із повним загоєнням вогнищ інфекції та відсутністю рецидивів. Висновки. Новий етап розвитку пластичної хірургії, який базується на ангіосомальній теорії будови тіла людини з боку кровопостачання Taylor і Palmer, є перспективним для застосування в ортопедії та травматології. Використання ангіосомальних шматків для пластики інфікованих дефектів м'яких тканин гомілки є ефективною технологією. Доцільно продовжити дослідження теорії ангіосом у лікуванні зазначеної патології іншої локалізації.*

**Key words.** Leg, fractures, complications, infected necrotic tissue defects, angiosomes, plastic surgery

## Introduction

The shin is the most typical localization of infected wounds and trophic ulcers that do not heal for a long time. At the same time, this localization is the most difficult for choosing a method of plastic replacement of defects of both soft tissues and bones [1]. Anatomical and functional features of this segment of the musculoskeletal system create the preconditions for frequent and severe injuries, and the deceptive simplicity of surgical access to the tibia may form in surgeons a superficial idea of the possibility of arbitrary choice of methods for fixing bone fragments and provoke unreasonable decisions about treatment. The combination of tactical and technological errors results in disabling complications in the form of adhesions, osteomyelitis, which is often accompanied by infected wounds, soft tissue defects, trophic ulcers, which do not heal even after the restoration of the supporting function of the leg. Chronic infected necrotic wounds are a significant obstacle to the recovery of patients and their long-term course causes exacerbation of osteomyelitis, local infectious-allergic skin inflammation, etc.

The traditional practice of treating post-traumatic or postoperative defects of the soft tissues of the lower leg is reduced to open management of wounds with their gradual secondary healing. But this tactic does not cover up for the impossibility of complete closure of the wound, the frequent formation of gross scarring of the skin and the further progression of chronic wound infection [2]. These facts necessitate the replacement of the existing defect with an adequate piece in size and composition [3, 4]. The main problem is the choice of the donor site for the collection of plastic material and forecasting the prospects for its further viability [5]. An empirical approach to deciding on the method of choosing plastic surgery is the cause of failure.

The viability of full-layer skin-fascial-muscle pieces is the key to a successful plastic surgery. And it is the relevance and importance of vascular nutrition of different parts of the torso and extremities led to an in-depth study of vascular anatomy, including perforating skin arteries and their accompanying veins, as a basis for island «perforating pieces», regardless of local or remote transposition [6].

The study of this problem describes a large number of scientific papers. But anatomical studies, enabling to create the concept of angiosomes, has become a new stage in the development of plastic surgery technologies [7, 8]. According to this theory, the human body is divided into 40 three-dimensional areas

of skin with subordinate fat and muscle, which are clearly delineated by separate areas of blood supply and have clear boundaries of nutrition by one artery (Fig. 1). The area of each angiosome is determined by the perimeter of the anastomotic vessels that connect them in all directions (vessels of reduced caliber, «choke vessels» [9], or real anastomoses without reducing the caliber of blood vessels). On average, there are 376 such vessels with a diameter of 0.5 mm or more [10]. The value of the research performed for plastic reconstructive surgery is that the full-layer soft tissue pieces, prepared taking into account the areas of angiosomes, are fully supplied with blood over the entire plane and to the full depth, which guarantees better engraftment at the transplant site.

Many years of world experimental and clinical practice have shown the unconditional expediency of using angiosomal theory in plastic surgery. It has been repeatedly proven that soft tissue pieces that are planned, prepared and moved with strict regard to the anatomy of angiosomes, fully maintain a full blood supply and are well ingrained at the transplant site [10].

Some publications on this topic have also been found in the domestic professional literature [11]. In this article, we consider it appropriate to share the experience of clinical use of angiosomal technology in the treatment of complicated infected injuries of the lower leg, as one of the most problematic areas of the human body from the standpoint of eliminating infected soft tissue defects.

*The aim of the study:* to assess the effectiveness of the use of plastic surgical technologies using non-

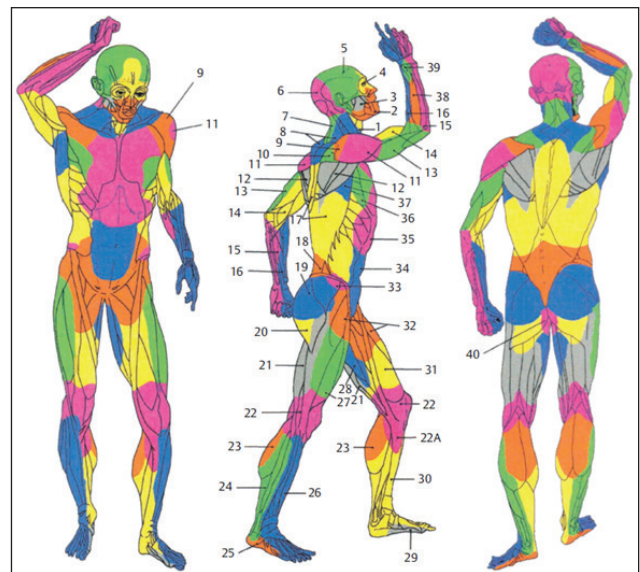


Fig. 1. Angiosomes of the human body [7]

free skin-fascial and muscle pieces based on the concept of angiosomes.

**Materials and methods**

The materials of the article were considered at the meeting of the Committee on Bioethics at the Sytenko Institute of Spine and Joint Pathology National Academy of Medical Sciences of Ukraine and received a positive decision (Minutes No. 216 of 26.04.2021).

The Department of Emergency Traumatology and Reconstructive Surgery of the Sytenko Institute of Spine and Joint Pathology National Academy of Medical Sciences of Ukraine and the Department of Bone and Purulent Infection of the municipal non-profit institution City General Hospital No. 18 as of today have accumulated considerable experience in the practical use of the theory of angiosomes for plastic replacement of combined skin and soft tissue defects of different localization secondary to infectious complications. Dozens of surgeries have been performed on the upper and lower extremities for purulent-necrotic defects of the skin and muscles of various origin, e. g. post-traumatic, neuroendocrine or onco-orthopedic. In this study, we decided to show the high effectiveness of plastic angiosomal pieces on the leg in case of injuries and post-traumatic complications of fractures. The clinical material is based on the analysis of the results of treatment of 3 patients with long-term infectious-necrotic defects of the soft tissues of the leg. In due time, all patients received high-energy fractures of the tibia of different localization and with different classification features. Within one day to three months after injury, the patients were operated on using bone metal osteosynthesis. In all cases, treatment was complicated by trophic disorders, resulting in the development of infected full-layer defects of the soft tissues of the lower leg, which did not heal for a long time (from 7 weeks to 3 years). Two patients developed chronic osteomye-

litis. In the previous stages of treatment, two patients were treated with traditional treatment technologies and soft tissue restoration in case of long-term trophic disorders and osteomyelitis (loosening dissection, «Italian» restoration, etc.) without achieving positive results. The presence of infected wounds in patients significantly hindered the final recovery and constantly provoked an exacerbation of osteomyelitis.

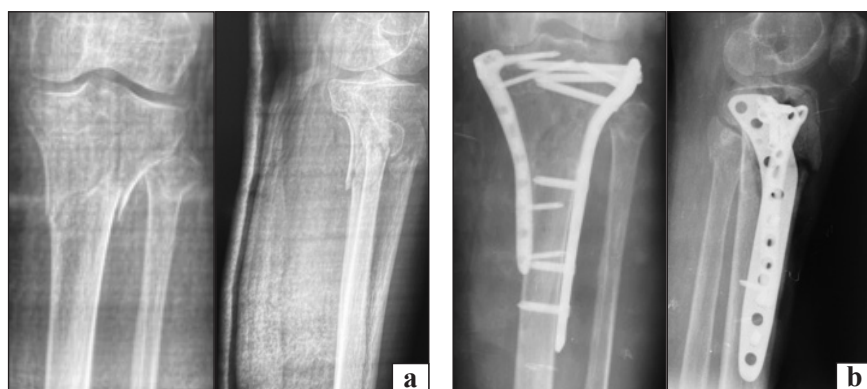Substantive examination for the presence of concomitant vascular abnormalities using ultrasound was the obligatory rule of examination and preoperative preparation of patients, and at the stage of planning plastic surgery and directly during the operation, we used a portable Doppler device. The use of anticoagulants, vascular and VAC therapy (as indicated), early mobilization of patients were also mandatory components of the treatment process.

**Results and their discussion**

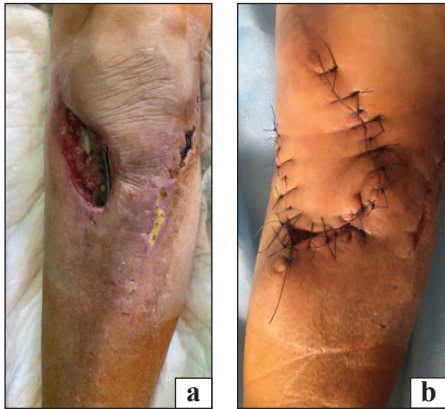
*Clinical example No. 1*

A 63-year-old patient A., as a result of a fall received a multifracture fracture of the proximal epimetaphysis of the left tibia type 41 C2 according to the AO/ASIF classification (Fig. 2, a). On the 10<sup>th</sup> day after injury, open reposition and bone metal osteosynthesis of the tibia were performed (Fig. 2, b).

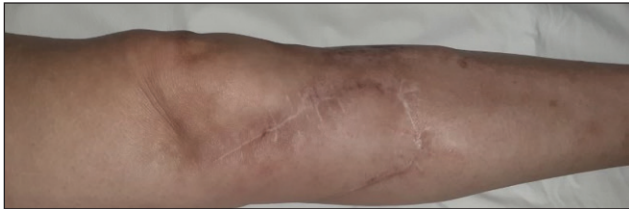The postoperative period was complicated by trophic disorders in the area of surgical access from the medial surface, in the form of full-layer necrosis of soft tissues with exposure of the bone in the area of fracture and metal structures (Fig. 3, a). In 1.5 months after the initial intervention, necrectomy was performed, followed by VAC therapy to prepare the wound for plastic replacement. Subsequently, the metal structure was removed, careful planning of plastic surgery was performed, involuntary plasticity of the defect was performed with a rotational skin-fascial piece on the perforators of the lower medial knee artery on a proximal basis (Fig. 3, b). Engraftment of the moved piece proceeded without complications.



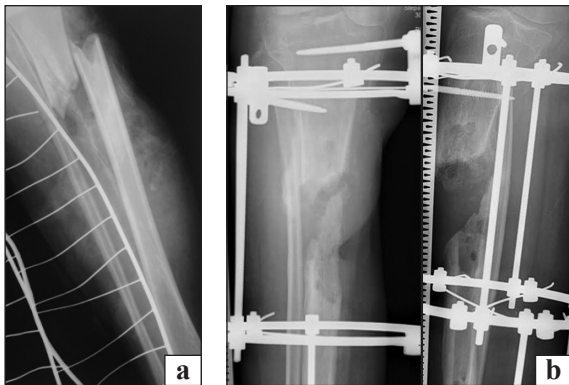
**Fig. 2.** Radiological images of a 63-year-old patient A. after injury (a), after surgery (b)



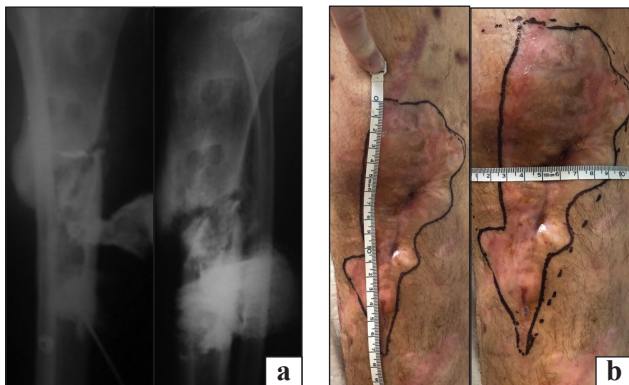
**Fig. 3.** Appearance of an area of the left knee joint of a 63-year-old patient A. after osteosynthesis (a), after plastic surgery of the defect with a rotational skin-fascial piece (b)



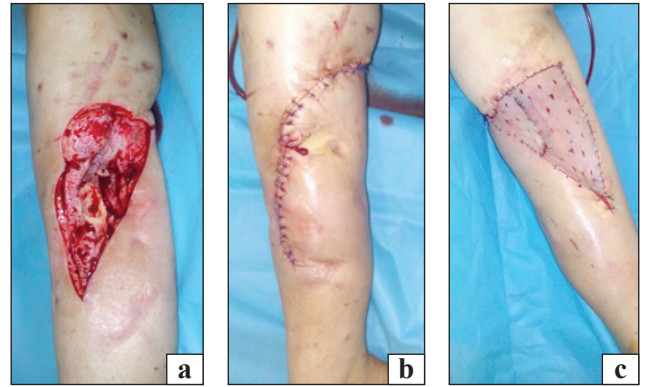
**Fig. 4.** Appearance of an area of the left knee joint of a 63-year-old patient A., a year after surgery



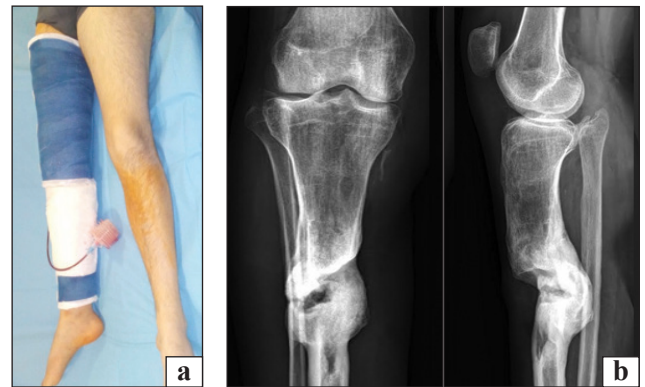**Fig. 5.** Radiological images of an 18-year-old patient S., after injury (a), after primary surgery (b)



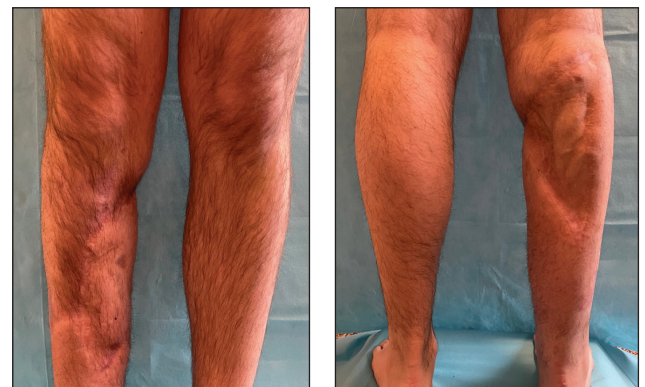
**Fig. 6.** Radiological images of the extremity of a patient S.: a) X-ray of fistula; b) surgery planning



**Fig. 7.** Appearance of the extremity of an 18-year-old patient S. after surgery: a) resection of scars and necrotic tissues; b) sural rotational skin-fascial piece on the distal base; c) free split skin piece (posterior surface of the tibia)



**Fig. 8.** Appearance of the extremity (a) and radiological images of an 18-year-old patient S. in 6 months after plastic surgery (b)



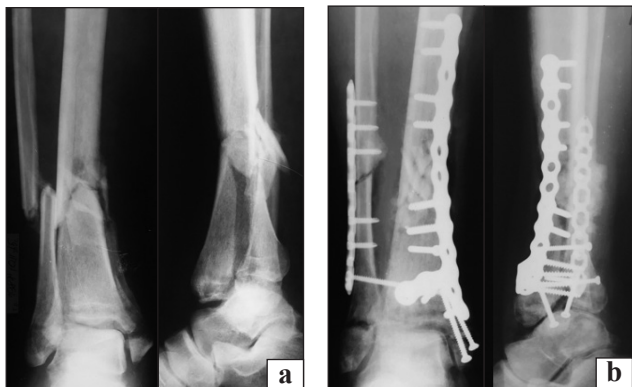
**Fig. 9.** Appearance of the extremities of an 18-year-old patient S. in 2.5 years after plastic surgery

Fig. 4 illustrates the final result of treatment one year after plastic surgery. The total follow-up period was 3 years after the last operation.

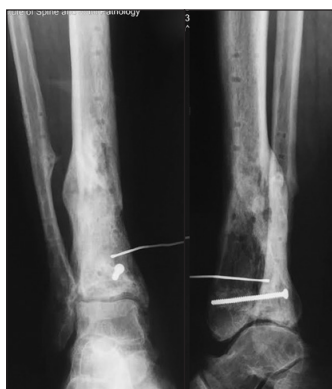#### *Clinical example No. 2*

An 18-year-old patient S. received an open fracture of the upper middle third of the right tibia as a result of an accident, type 42 B3 according to

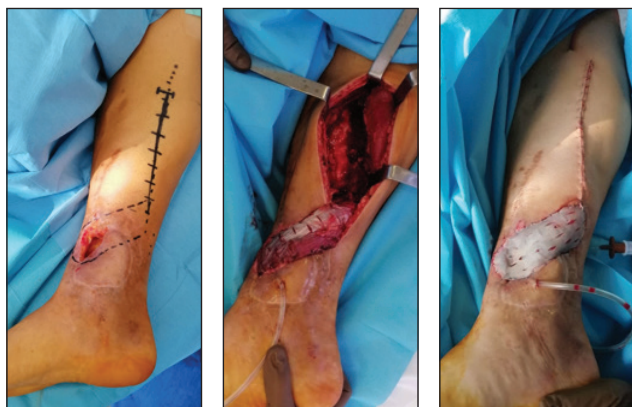
AO/ASIF (type II B according to the Kaplan-Markov classification of open injuries) (Fig. 5, a). Urgently, at the place of the accident, the patient underwent surgical treatment of the wound and extrafocal osteosynthesis with a rod external fixator (Fig. 5, b). The postoperative period was complicated by the development of soft tissue infection and, subsequently, osteomye-



**Fig. 10.** Radiological images of a 39-year-old patient B. in 2 months after injury (a), after open reposition and metal osteosynthesis (b)



**Fig. 11.** Radiological images of a 39-year-old patient B. in 8 months after osteosynthesis, chronic osteomyelitis of the tibia, fistula

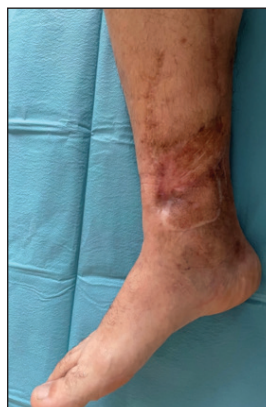

**Fig. 12.** A 39-year-old patient B., stages of plastic surgery using the medial head of the soleus muscle on the distal base and split free skin graft

litis of the tibia. Within 1.5 years from the moment of injury, the patient still underwent external fixation in the device and a series of fistula sequestrectomies, but it did not eliminate the infectious process and did not consolidate bone fragments (Fig. 6, a). An area of hypotrophic scar degeneration of integumentary tissues with numerous fistulas was formed on the anterior medial surface of the tibia (Fig. 6, b). At this stage of treatment, the external fixation device was dismantled, scars and necrotic tissues were resected (Fig. 7, a), plastic surgery was performed with a distal rotational skin-fascial piece on the distal base (Fig. 7, b), the donor wound was closed with a free split skin piece, 7, c). In the postoperative period, the limb was fixed with a functional bandage «Scotch-cast» with «windows» for the rehabilitation of the wound surface, which allowed axial loading (Fig. 8, a). In 6 months after the described surgical intervention, femoral fusion was achieved (Fig. 8, b), in the complete absence of signs of infectious process, reorganization of skin pieces and wound healing. The total observation period after plastic surgery was 2.5 years, the appearance of the limb is shown in Fig. 9.

*Clinical example No. 3*

A 39-year-old patient B. received a fracture of the pilon of the right leg in the classic version of type 43 C3 according to the classification of AO/ASIF. Primary treatment was performed on an outpatient basis, at the place of residence, in rural areas with the help of a posterior plaster cast. The patient was able to go to a specialized medical institution for social reasons only in 2 months after injury (Fig. 10, a). Open reposition of fragments of the distal metaepiphysis of the right tibia and bone metal osteosynthesis of the lower third of the right tibia was performed (Fig. 10, b). The postoperative period was complicated by a purulent-necrotic process in the area of the postoperative wound, and then by osteomyelitis of the tibia. However, in 8 months after osteosynthesis,



**Fig. 13.** A 39-year-old patient B., general view of the extremity in 2 years after plastic surgery

the metal structure was removed, the fractures were consolidated, and the resistance function of the limb was restored in the presence of the fistulous form of osteomyelitis (Fig. 11).

That is, secondary to a consolidated fracture there was a defect of integumentary tissues with periodic exacerbations of the inflammatory process, which significantly worsened the quality of life of the patient. The patient was repeatedly subjected to necrectomy, attempts to close the infected soft tissue defect in the distal third of the leg with the help of loosening skin incisions, «Italian» plastic surgery, etc. Due to the presence of a combined deep soft tissue and bone defect, it was considered appropriate to perform plastic surgery using the medial head of the soleus muscle on a distal base and a split free skin graft (Fig. 12). One month after the operation, complete control was achieved over the infectious inflammatory process of both bone and integumentary tissues, the wounds healed initially. The total observation period after plastic surgery was 2 years, no recurrence of the infectious process was noted; complete restructuring of the skin and muscle pieces, restoration of limb porosity was recorded. The appearance of the surgical area is shown in Fig. 13.

## Conclusions

The treatment of combined damage to the bone and soft tissue structures of the lower leg is a multi-component problem, leading to chronic infected wound defects, and the use of traditional methods of free and non-free skin grafting is generally ineffective. That is why a new stage in the development of plastic surgery, which is based on the angiosomal theory of the structure of the human body by the blood supply, developed by G. I. Taylor and J. H. Palmer, is quite promising for use in orthopaedics and traumatology.

Our own clinical experience with the use of angiosomal pieces for plastics of infected soft tissue defects of the upper and lower extremities has proven the high efficiency of this technology.

It is advisable to continue clinical trials to develop options for plastic surgery for the treatment of infected post-traumatic soft tissue defects of the extremities using angiosomal theory.

Further studies of the possibilities of angiosomal plasticity of trophic lesions of the distal parts of the lower extremities in vascular and endocrine abnormalities depending on its etiology and the degree of circulatory disorders are promising.

**Conflict of interest.** The authors declare no conflict of interest.

## References

1. Shibaev, E. Yu., Ivanov, P. A., & Nevedrov, A. V. (2018). Tactics of treatment of post-traumatic defects of soft tissues of the extremities. *Zh. N.V. Sklifosovsky Research Institute for Emergency Medicine*, 7(1), 37–43. <https://doi.org/10.23934/2223-9022-2018-7-1-37-43>.
2. Fast and standardized skin grafting of leg wounds with a new technique: report of 2 cases and review of previous methods / N. Hamnerius, E. Wallin, Å. Svensson [et al.] // *Eplasty*. — 2016. — Vol. 16. — Article ID: e14.
3. Belousov, A. E. (1998). *Plastic reconstructive and aesthetic surgery*. St. Petersburg : HIPPOCRATES.
4. Best local flaps for lower extremity reconstruction / F. M. Al-Mugaren, C. J. Pak, H. P. Suh, J. P. Hong // *Plastic and Reconstructive Surgery, Global Open*. — 2020. — Vol. 8 (4). — Article ID: e2774. — DOI: 10.1097/GOX.0000000000002774.
5. Zenn M. R. *Reconstructive surgery. Anatomy, Technique, and Clinical Applications* / M. R. Zenn, G. Jones. — Thieme, 2012. — P. 1583–1732.
6. The perforasome theory: Vascular anatomy and clinical implications / M. Saint-Cyr, C. Wong, M. Schaverien [et al.] // *Plastic and Reconstructive Surgery*. — 2009. — Vol. 124. — P. 1529–1544. — DOI: 10.1097/PRS.0b013e3181b98a6c.
7. Taylor G. I. The vascular territories (angiosomes) of the body: experimental study and clinical applications / G. I. Taylor, J. H. Palmer // *British Journal of Plastic Surgery*. — 1987. — Vol. 40 (2). — P. 113–141. — DOI: 10.1016/0007-1226(87)90185-8.
8. The anatomical (angiosome) and clinical territories of cutaneous perforating arteries: development of the concept and designing safe flaps / G. I. Taylor, R. J. Corlett, S. C. Dhar, M. W. Ashton // *Plastic and Reconstructive Surgery*. — 2011. — Vol. 127 (4). — P. 1447–1459. — DOI: 10.1097/PRS.0b013e318208d21b.
9. The function of 'choke vessels' to the blood flow: angiographic and laser flow-graphic study on the rat flap model / M. Toshiharu, S. Katsumata, K. Ogo, G. I. Taylor // *Wound Repair and Regeneration*. — 2008. — Vol. 12 (1). — P. A15–A15. — DOI: 10.1111/j.1067-1927.2004.abstractbc.x.
10. Taylor G. I. The functional angiosome: clinical implications of the anatomical concept / G. I. Taylor, R. J. Corlett, M. W. Ashton // *Plastic and Reconstructive Surgery*. — 2017. — Vol. 140 (4). — P. 721–733. — DOI: 10.1097/prs.0000000000003694.
11. Samoilenko, G. E., Zharikov, S. O., & Klimansky, R. P. (2019). Application of "propeller" technique for plastics of extensive wounds of the distal lower extremity. *Clinical Surgery*, 86(3), 27–31. <https://doi.org/10.26779/2522-1396.2019.03.27>.

## COMBINED SOFT TISSUE PLASTICS IN TREATMENT OF THE LEG INFECTED NECROTIC LESIONS

I. G. Bets, O. Ye. Vyrva, G. V. Bets

Sytenko Institute of Spine and Joint Pathology National Academy of Medical Sciences of Ukraine, Kharkiv

✉ Iryna Bets, DMSci in Traumatology and Orthopaedics: [betsirina1984@gmail.com](mailto:betsirina1984@gmail.com)

✉ Oleg Vyrva, MD, Prof. in Traumatology and Orthopaedics: [dr.olegvyrva@gmail.com](mailto:dr.olegvyrva@gmail.com)

✉ Grygorii Bets, DMSci in Traumatology and Orthopaedics: [betsirina1984@gmail.com](mailto:betsirina1984@gmail.com)