

ОБЗОРЫ И РЕЦЕНЗИИ

УДК 617.547-003.8(045)

DOI: <http://dx.doi.org/10.15674/0030-59872018196-104>**New classification 3 columns theory of lumbar degenerative cascade (literature review)****B. Darwono¹, V. O. Radchenko²**¹ Medical Faculty of Tarumanagara University, Jakarta, Indonesia² Sytenko Institute of Spine and Joint Pathology National Academy of Medical Sciences of Ukraine, Kharkiv

Lumbar degeneration is a pathologic condition in the aging spine that changes the bio-mechanic construct of the lumbar mobile segment either single or multi-levels, leading to low back pain syndrome and lead to a deformity/de novo scoliosis. The generally well accepted theory of lumbar degeneration was published by Kirkaldy-Willis, et al (1978), and clearly described the pathologic cascade of lumbar mobile segment, but only involve 2 columns: the anterior column (disc) and middle column (posterior joint/ facet). The posterior column degenerative cascade was published by Christian Ingerslev Baastrup (1933). He described about the pathologic changes on spinous processes of lumbar vertebrae and the soft tissues in between them, which was then known as Baastrup's disease or Kissing Spine. Lacking off to understand the etiology due to a limitation of studies in histologic and radiographic changes at that time, then this theory was forgotten in the clinical practice until the recent Bristol and Auckland study, which were published in European Spine Journal (2012). Their study describes clearly the pathologic cascade of the posterior column that contributing the lumbar degeneration. Based on this 3 columns theory of lumbar degenerative cascade, then a new classification is designed to describe detail of bio-mechanic change in the anterior, middle and posterior column leading to low back pain syndrome and deformity. The justification of surgical treatment to fix and reconstruct the bio-mechanic changes of the 3 columns of lumbar mobile segment could be based on this new classification. Key words: lumbar degeneration, spine, theory of cascade.

Lumbar Degeneration

Lumbar degeneration is a pathologic condition in the aging spine due to discrepancy between external load and the internal strength of the mobile segment during the daily activity of life. The pathologic cascade may change the Bio-mechanic construct of the spine which is divided in 3 column according to R. Roy-Camille and P. Massin: anterior, middle and posterior column.

Key words: lumbar degeneration, spine, theory of cascade

Дегенерация поясничного отдела позвоночника, особенно полисегментарная, приводит к изменениям биомеханики, развитию болевых синдромов и деформациям. Большинство специалистов в своей работе используют теорию поясничной дегенерации, опубликованную в 1978 году Kirkaldy-Willis, где доступно описан каскад патологических изменений в позвоночном двигательном сегменте, включающем две опорные структуры — переднюю (межпозвоноковый диск) и заднюю или среднюю (дугоотростчатые суставы). Заднюю опорную систему также охарактеризовал Cristian Baastrup (1933), который представил патологические изменения в остистых отростках поясничных позвонков и мягких тканей между ними, которые хорошо известны как синдром Баструпа. На протяжении многих лет исследований в этой области проводилось очень мало, вплоть до работы Bristol and Auckland, результаты которой были опубликованы в European Spine Journal (2012). Описан каскад патологических изменений задних структур на фоне дегенерации поясничного отдела позвоночника. Базируясь на теории каскада дегенерации поясничного отдела позвоночника, средних и задних структур, представлена новая классификация, основанная на особенностях биомеханики, дальнейшем развитии болевых синдромов и деформаций позвоночника. Также приведены новые подходы к хирургическому лечению, включая реконструкцию биомеханики и формы позвоночника. Ключевые слова: дегенерация поясничного отдела, позвоночник, теория каскада.

W. H. Kirkaldy-Willis et al. (fig. 1) published 3 joints complex theory of lumbar degenerative cascade. Details of the pathologic cascade were clearly described the pathologic changes of the bio-mechanic construct of the mobile segment: the disc, and 2 posterior joints, but this only describe the 2 columns of Roy-Camille, anterior and middle column.

The lumbar disc herniation theory by Macnab and McCulloch (1990) describe only the pathology of anterior column (fig. 2). The pathologic grading for discopathy by Thompson (fig. 3) also describe the degenerative changes of anterior column, then the degenerative grading of the facet joint by Grogan (fig. 4) and the grading of the osteophyte by Fujiwara (fig. 5),

all describe the degenerative changes of the middle column. All these theories have a relationship with the

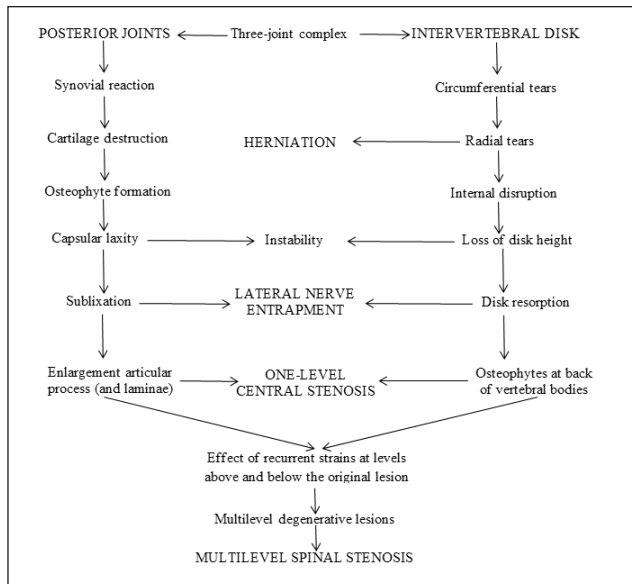


Fig. 1. Kirkaldy-Willis. 3 joints complex theory of lumbar degenerative cascade

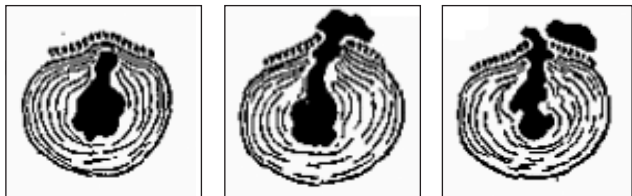


Fig. 2. The lumbar disk herniation theory by Macnab&McCulloch

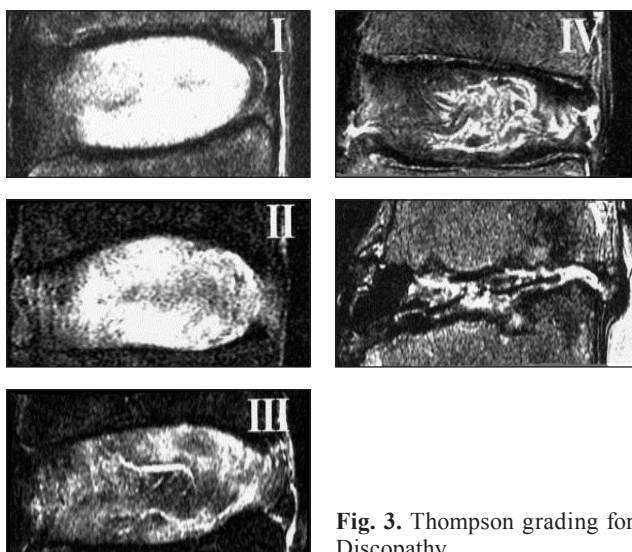


Fig. 3. Thompson grading for Discopathy

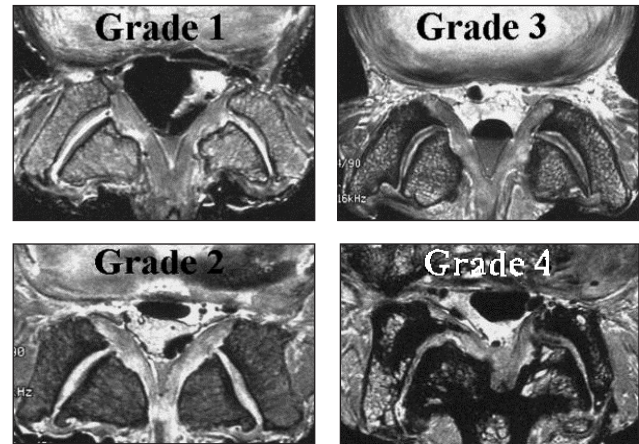


Fig. 4. Grogan grading for facet joint

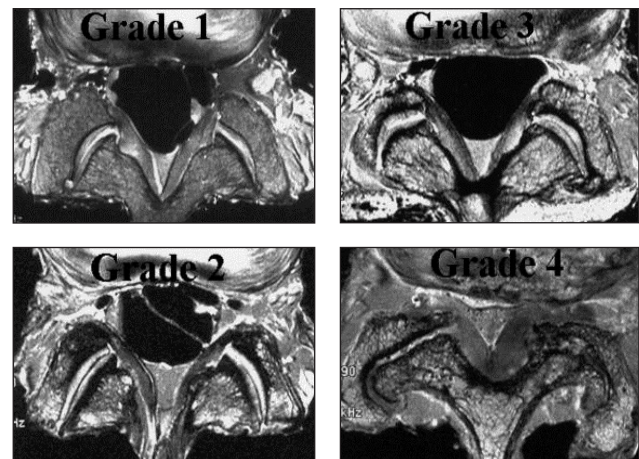


Fig. 5. Fujiwara grading for osteophyte

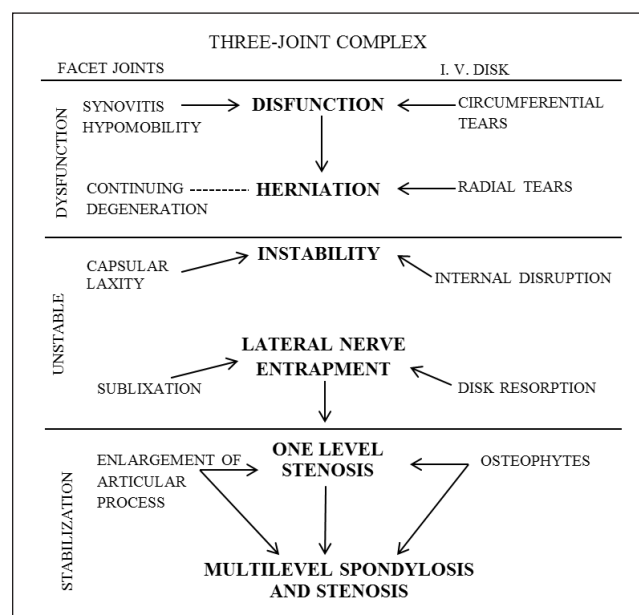


Fig. 6. Kirkaldy-Willis grading for three joint complex

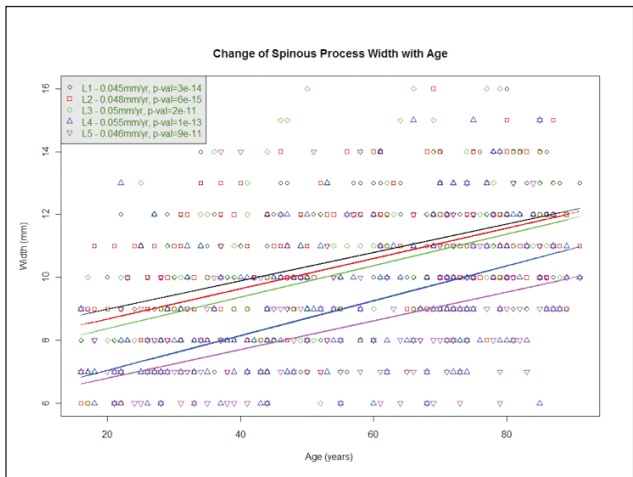


Fig. 7. The width of spinous process increase 50 %

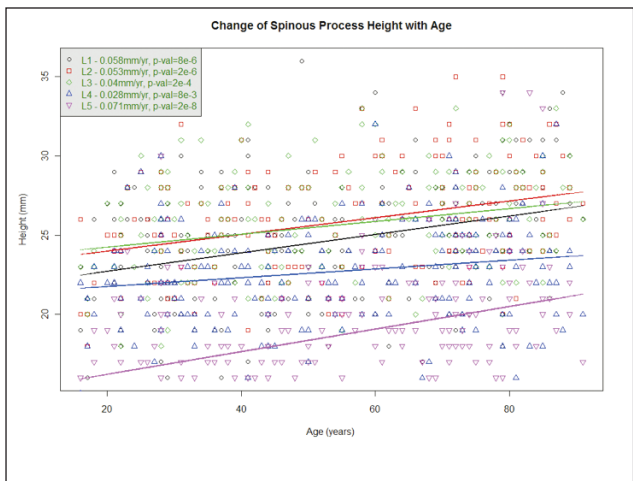

Fig. 8. Height of spinous process increase 30 %

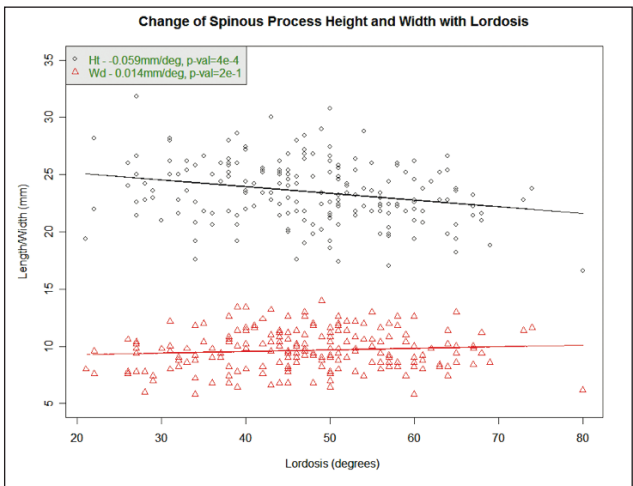


Fig. 9. The lordosis decrease by age

degenerative cascade of the three joint complex of Kirkaldi-Willis describing 3 cascades: dysfunction, unstable and stabilization (fig. 6), but only involve the two columns of Roy-Camille, the anterior and middle column.

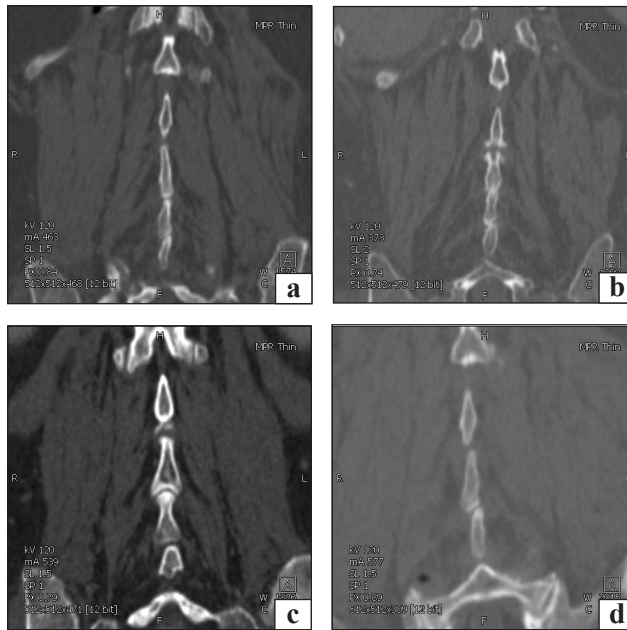


Fig. 10. 4 types of kissing spine abatement: a) type 1; b) type 2; c) type 3; d) type 4

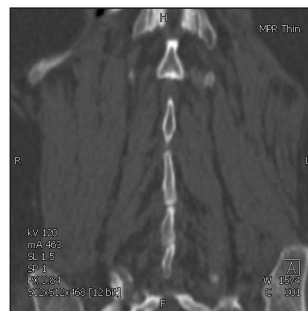

Fig. 11. Internal rotation

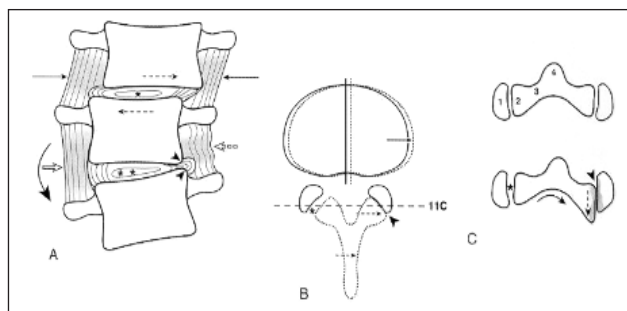


Fig. 12. Lateral listhesis

Christian Ingerslev Bastrup a Danish Radiologist Copenhagen (1855–1950) described the pathologic changes on the spinous processes in the lumbar vertebrae including the soft tissues between them which was mentioned as Kissing spine. A breakdown of the inter-spinous ligament occurs and leading to a development of neo-arthritis between adjacent spinous processes, characterized by abutment, enlargement, sclerosis and bursa.

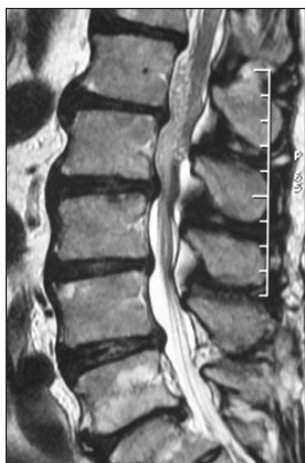

Fig. 13. Loss of lumbar lordosis

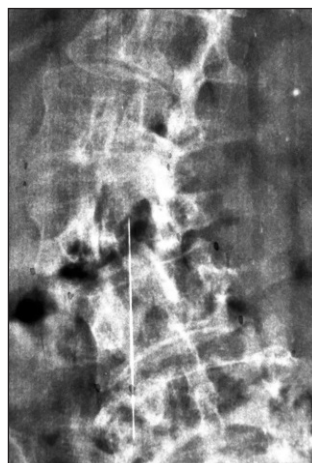
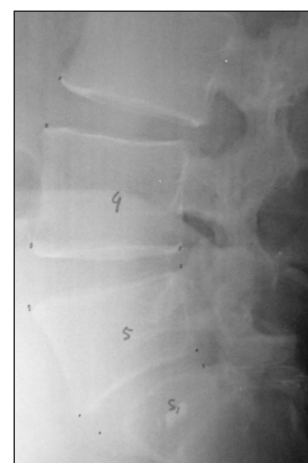
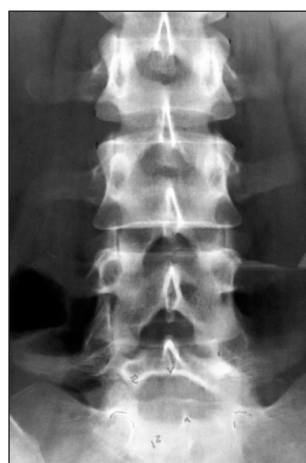
Fig. 14. Adult deformity (De novo scoliosis)



But due to a limitation of studies on histologic and radiographic changes in his era, his theory was forgotten in relation with the application in clinical practice.

Later a study of the Kissing spine was done in 2010 by Auckland group and by Bristol group.

The Bristol study (2010) analyze 100 standing X-rays regarding: lumbar lordosis, inter-spinous gap, and lumbar disc height, while the Auckland study analyze 200 CTs with the age ranging between 20–90 years: the abdominal CTs being used for the asymptomatic group and CT myelogram for the symptomatic group.

The result of these observation show that by aging, the width of the spinous process increase 50 % (fig. 7), the height increase 30 % (fig. 8), thus when the width and height of the spinous process increase as a consequence the lordosis of the lumbar spine decrease (fig. 9), and as a conclusion this study support the Kissing spine theory as described by Baastrup.

The Bristol and Auckland studies also describe 4 types of kissing spine abutment: type 1 end to end, type 2 hypertrophic, type 3 ball and socket, and type 4 oblique (fig. 10). In type 4, the oblique abutment produces a torque across this level creating an intersegmental rotation also a lateral listhesis and causing a deformity of de novo scoliosis (fig. 11, 12).

Combining the both theory of Kirkaldy-Willis and Baastrup will bring us to a new understanding about the loss of lumbar lordosis, that it is not merely related to disc degeneration but also due to enlargement of the spinous process related to spinous process degenerative cascade (fig. 13).

A new theory is built to give a clear understanding about Lumbar degenerative process: that it may start from either one of the three columns, alone or together, starting from inflammatory to a compressive

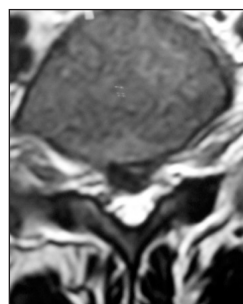
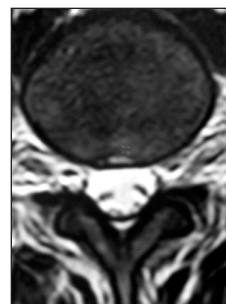
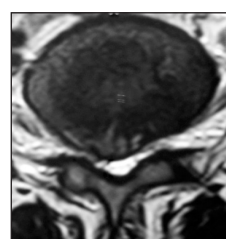
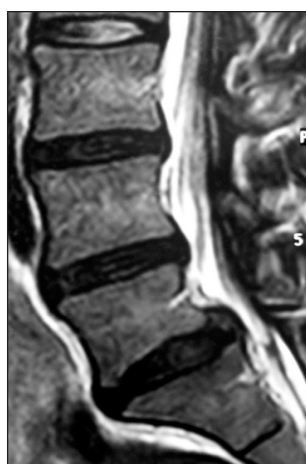


Fig. 15. Justification of treatment: discectomy L_{IV}-L_V, L_V-S_I

sive reactions, change the bio-mechanic construct of the lumbar spine, single or multi-levels and leading to an adult deformity or de novo scoliosis (fig. 14).

A new classification should be designed to give a complete description about various individual cascade of Lumbar degeneration, and as a consequence in the clinical application of evidence based treatment related to this theory: the justification of treatment for various individual cases will be different.

New Classification of Lumbar Degeneration

The new classification is based on the three columns theory of lumbar degeneration, using the radiologic parameters of dynamic lumbosacral X-rays and MRI studies, should describe a complete

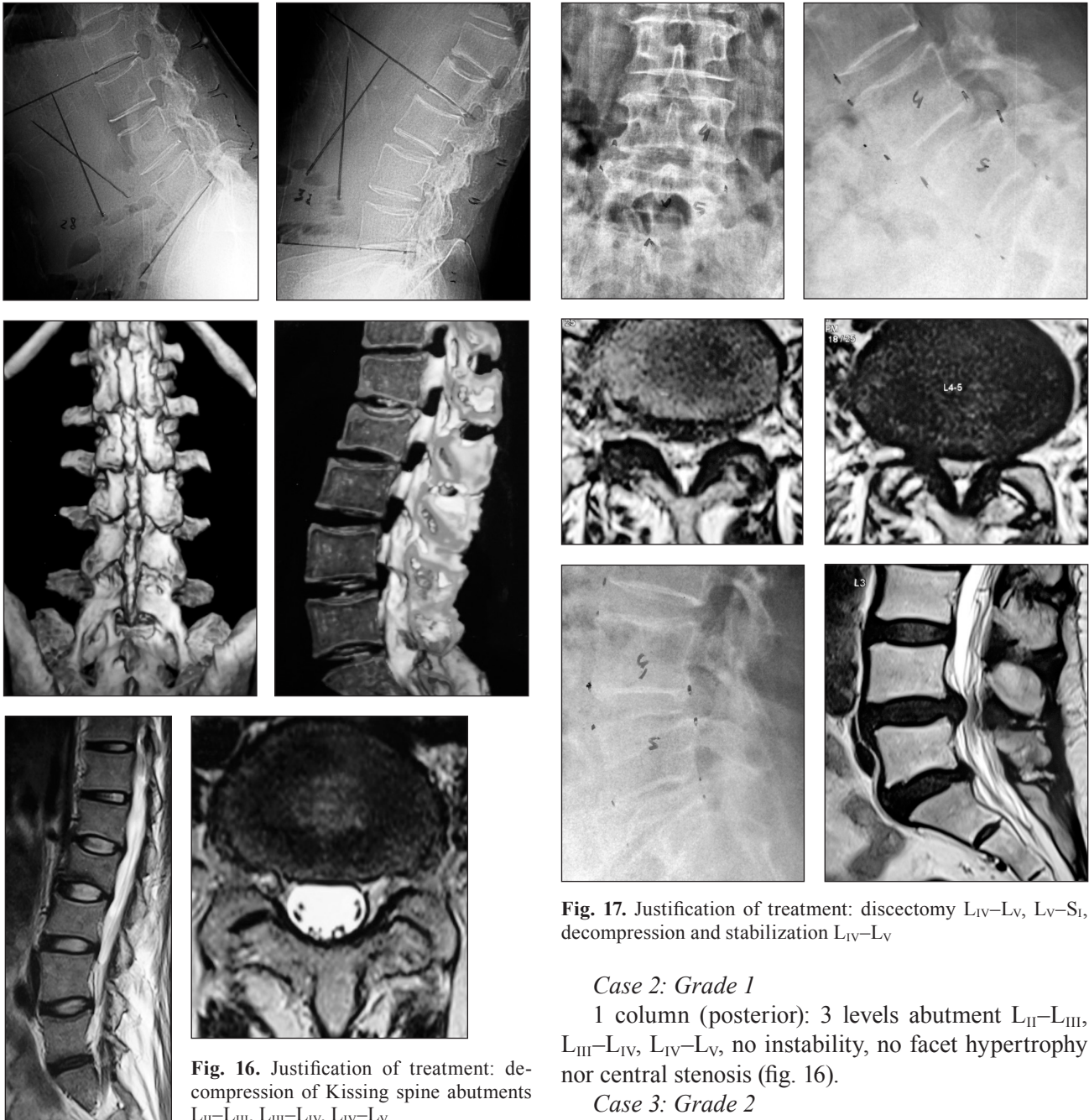


Fig. 16. Justification of treatment: decompression of Kissing spine abutments L_{II}-L_{III}, L_{III}-L_{IV}, L_{IV}-L_V

Fig. 17. Justification of treatment: discectomy L_{IV}-L_V, L_V-S_I, decompression and stabilization L_{IV}-L_V

assessment of bio-mechanic construct changes involving the three columns, and each column or level might be in different cascade.

Grade 1: involve either one of the three column of SMS, each level in different cascade.

Grade 2: involve either 2 columns of SMS, each column or level in different cascade.

Grade 3: involve 3 columns of SMS, each column or level in different cascade.

Case 1: Grade 1

1 column (anterior): 2 levels disc herniation L_{IV}-L_V, L_V-S_I, no instability, no abutment, no facet hypertrophy nor central stenosis (fig. 15).

Case 2: Grade 1

1 column (posterior): 3 levels abutment L_{II}-L_{III}, L_{III}-L_{IV}, L_{IV}-L_V, no instability, no facet hypertrophy nor central stenosis (fig. 16).

Case 3: Grade 2

2 Columns (anterior, middle): 2 levels disc herniation L_{IV}-L_V, L_V-S_I, 1 level Instability L_{IV}-L_V, 1 level facet hypertrophy and central stenosis L_{IV}-L_V, no abutment (fig. 17).

Case 4: Grade 2

2 Columns (anterior, middle): 1 level disc herniation L_{IV}-L_V, 1 level facet hypertrophy and stenosis L_{IV}-L_V, 2 levels instability L_{III}-L_{IV}, L_{IV}-L_V, no abutment (fig. 18).

Case 5: Grade 2

2 Columns (anterior, middle): 1 level disc herniation L_{IV}-L_V, 3 levels facet hypertrophy L_{III}-L_{IV}, L_{IV}-L_V, L_V-S_I, 3 levels instability L_{III}-L_{IV}, L_{IV}-L_V, L_V-S_I, no abutment (fig. 19).

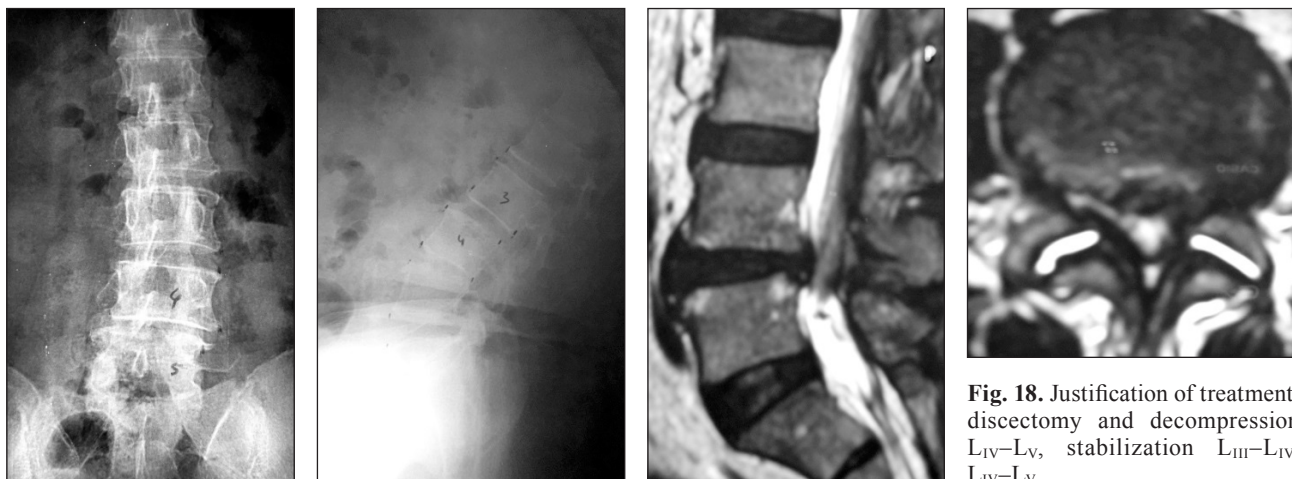


Fig. 18. Justification of treatment: discectomy and decompression L_{IV}-L_V, stabilization L_{III}-L_{IV}, L_{IV}-L_V

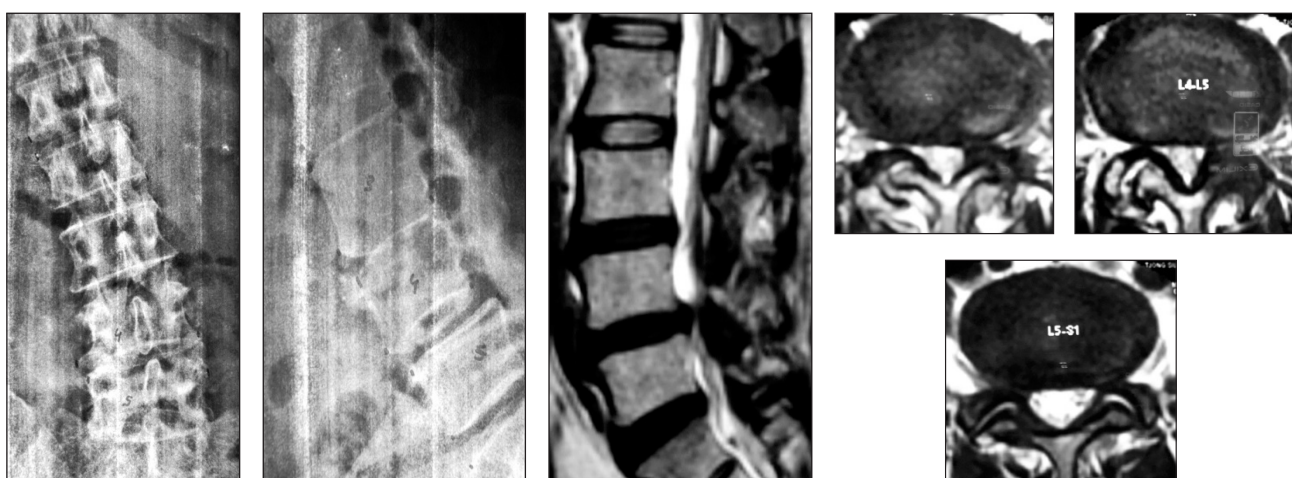


Fig. 19. Justification of treatment: discectomy L_{IV}-L_V, decompression and stabilization L_{III}-L_{IV}, L_{IV}-L_V, L_V-S_I

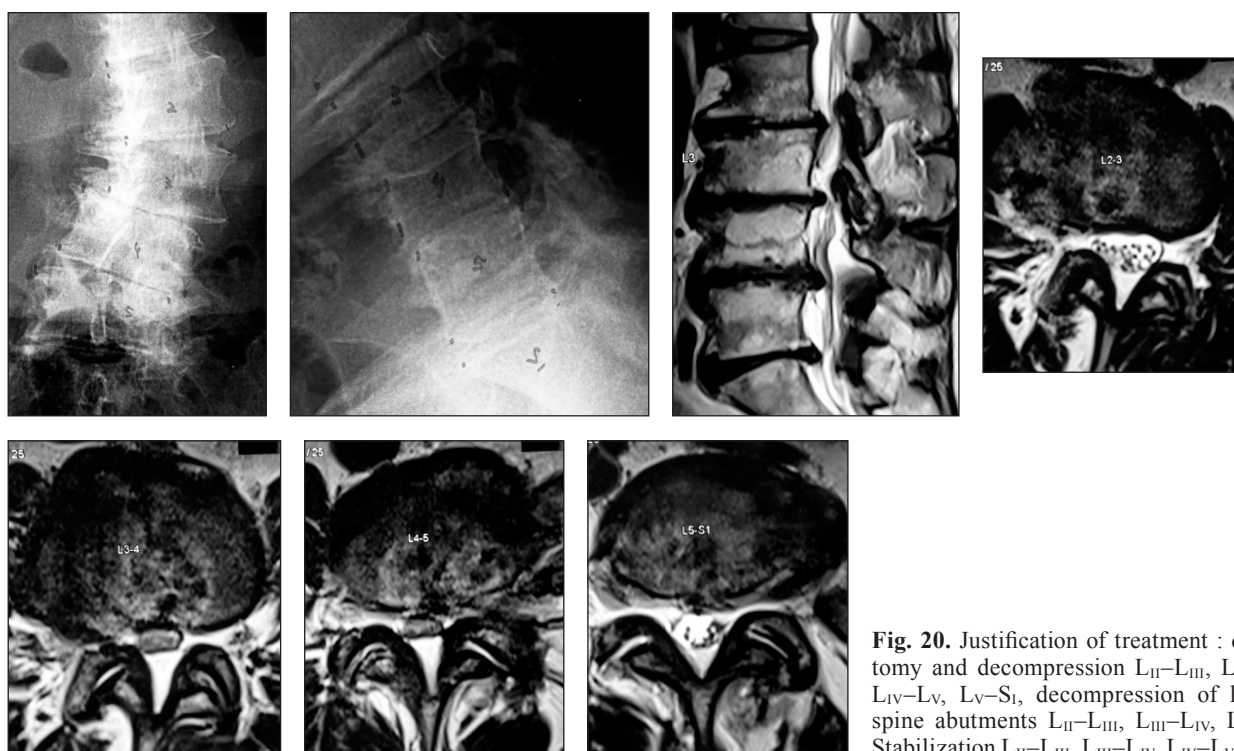


Fig. 20. Justification of treatment : discectomy and decompression L_{II}-L_{III}, L_{III}-L_{IV}, L_{IV}-L_V, L_V-S_I, decompression of kissing spine abutments L_{II}-L_{III}, L_{III}-L_{IV}, L_{IV}-L_V, Stabilization L_{II}-L_{III}, L_{III}-L_{IV}, L_{IV}-L_V, L_V-S_I

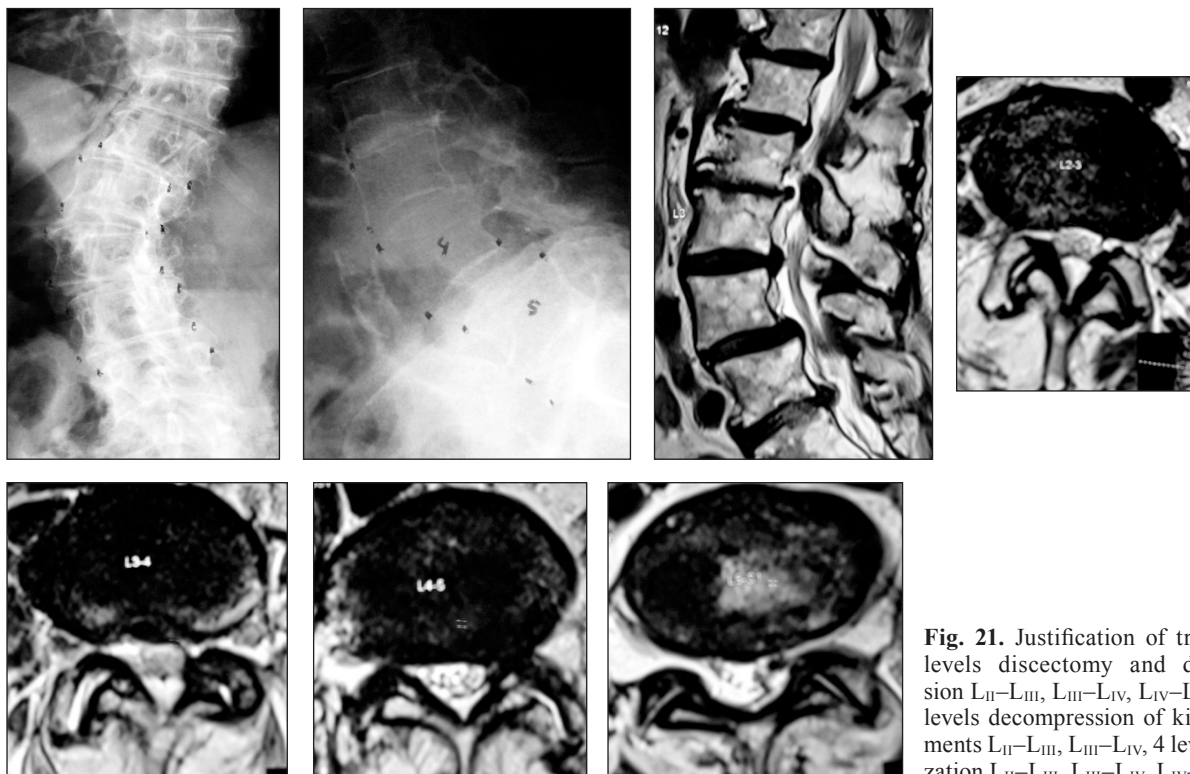


Fig. 21. Justification of treatment: 4 levels discectomy and decompression L_{II}–L_{III}, L_{III}–L_{IV}, L_{IV}–L_V, L_V–S_I, 2 levels decompression of kissing abutments L_{II}–L_{III}, L_{III}–L_{IV}, 4 levels stabilization L_{II}–L_{III}, L_{III}–L_{IV}, L_{IV}–L_V, L_V–S_I

Case 6: Grade 3

3 Columns (anterior, middle, posterior): 4 levels disc herniation L_{II}–L_{III}, L_{III}–L_{IV}, L_{IV}–L_V, L_V–S_I, 4 levels facet hypertrophy L_{II}–L_{III}, L_{III}–L_{IV}, L_{IV}–L_V, L_V–S_I, 3 levels abutments L_{II}–L_{III}, L_{III}–L_{IV}, L_{IV}–L_V, 4 levels instability L_{II}–L_{III}, L_{III}–L_{IV}, L_{IV}–L_V, L_V–S_I (fig. 20).

Case 7: Grade 3

3 Columns: 4 levels disc herniation L_{II}–L_{III}, L_{III}–L_{IV}, L_{IV}–L_V, L_V–S_I, 4 levels facet hypertrophy and stenosis L_{II}–L_{III}, L_{III}–L_{IV}, L_{IV}–L_V, L_V–S_I, 4 levels instability L_{II}–L_{III}, L_{III}–L_{IV}, L_{IV}–L_V, L_V–S_I, 2 levels abutments L_{III}–L_{IV}, L_{IV}–L_V (fig. 21).

Conclusions

The new classification could describe a complete assessment of all the bio-mechanic construct changes involving the three columns of mobile segment and each column in different cascade and different levels.

The new classification can be used as a Guideline to fix and reconstruct all the bio-mechanic construct changes of the mobile segment in lumbar degeneration.

It also can be used as an evidence based consideration to justify the different methods of treatment for various cases of lumbar degeneration.

Conflict of interest. The authors declare the absence of conflict of interest.

References

1. Spinous process morphology : the effect of ageing through adulthood on spinous process size and relationship to sagittal alignment / C. E. Aylott, R. Puna, P. A. Robertson, C. Walker // *Eur. Spine. J.* — 2012. — Vol. 21 (5). — P. 1007–1012. — DOI: 10.1007/s00586-011-2029-6.
2. Baastrup C. On the spinous processes of the lumbar vertebrae and the soft tissues between them, and on pathological changes in that region / C. Baastrup // *Acta Radiol.* — 1933. — Vol. 14. — P. 52–54.
3. Anterior lumbar fusion improves discogenic pain at levels of prior posterolateral fusion / W. T. Barrick, J. A. Schofferman, J. B. Reynolds [et al.] // *Spine.* — 2000. — Vol. 25 (7). — P. 853–857.
4. How much radiographic motion is present after solid fusion / C. M. Bono, M. Bawa, K. White [et al.] : presented at the Annual Meeting of the International Society for the Study of the Lumbar Spine. — Vancouver, BC, 2003.
5. Lumbar interbody fusion using the Brantigan I/F cage for posterior lumbar interbody fusion and the variable pedicle screw placement system: two-year results from a Food and Drug Administration investigational device exemption clinical trial / J. W. Brantigan, A. D. Steffee, M. L. Lewis [et al.] // *Spine.* — 2000. — Vol. 25 (11). — P. 1437–1446.
6. Darwono B. The role of IntraSpine in the treatment of late degenerative problems / B. Darwono : COA 2012 Meeting. — Beijing, 2012.
7. Darwono B. The role of interlaminar (IntraSpine) in the treatment of early and late degenerative problems / B. Darwono : IntraSpine Users Meeting. — Nice, France, 2013.
8. Darwono B. The role of interlaminar (IntraSpine) device in the treatment of early & late degenerative problems / B. Darwono : ISMISS. — Turkey, 2013.
9. Darwono B. The role of new interlaminar device (IntraSPINE) in the treatment of early & late degenerative problems / B. Darwono : Indonesian Spine Society Meeting. — Palembang, Indonesia, 2013.

10. Darwono B. The role of interlaminar stabilization device (IntraSPINE) in the treatment of early & late degenerative problems / B. Darwono : 13th Annual Meeting PASMIS. — Miyazaki, Japan, 2013.
11. DePalma A. F. Surgery of the lumbar spine / A. F. DePalma, R. H. Rothman // *Clin. Orthop.* — 1969. — Vol. 63. — P. 162–710.
12. Eck J. C. Adjacent-segment degeneration after lumbar fusion. A review of clinical, biomechanical, and radiologic studies / J. C. Eck, S. C. Humphreys, S. D. Hodges // *Am. J. Orthop.* — 1999. — Vol. 28. — P. 336–340.
13. Etebar S. Risk factors for adjacent-segment failure following lumbar fixation with rigid instrumentation for degenerative instability / S. Etebar, D. W. Cahill // *J. Neurosurg.* — 1999. — Vol. 90. — P. 163–169.
14. Frymoyer J. W. Spinal stability and instability: Definitions, classification, and general principles of management / J. W. Frymoyer, M. H. Krag // *The Unstable Spine* / ed. A. Kahn. — New York : Grune & Stratton, 1986.
15. Frymoyer J. W. Segmental instability. Rationale for treatment / J. W. Frymoyer, D. K. Selby // *Spine.* — 1985. — Vol. 10. — P. 280–286.
16. The effect of disc degeneration and facet joint osteoarthritis on the segmental flexibility of the lumbar spine / A. Fujiwara, T. H. Lim, H. S. An [et al.] // *Spine.* — 2000. — Vol. 25 (23). — P. 3036–3044.
17. The relationship between disc degeneration, facet joint osteoarthritis, and stability of the degenerative lumbar spine / A. Fujiwara, K. Tamai, H. S. An [et al.] // *J. Spinal. Disord.* — 2000. — Vol. 13. — P. 444–450.
18. Guizzardi G. DIAM Spinal Stabilization System / G. Guizzardi, P. Petrini // *Motion preservation surgery of the spine, Advanced technique and controversies.* — Saunders Elsevier, 2007. — P. 519–522.
19. Guizzardi G. Italian Multicentre study on the use of A New Interlaminar Prosthesis (INTRASPINE) in DDD of the lumbar spine / G. Guizzardi, R. Morichi, C. M. Mattioli [et al.] : Preliminary Report, Deutscher Wirbelsäulenkongress. — Congress Centrum, Ulm, 27–29 november, 2008.
20. Guizzardi G. Interspinous versus Interlaminar devices in DDD : Biomechanic Tests / G. Guizzardi, P. Petrini : Deutscher Wirbelsäulenkongress, Internationales Congress Centrum. — Munchen, 10–12 december, 2009.
21. Jinkins J. R. Acquired degenerative changes of the intervertebral segments at and suprajacent to the lumbosacral junction. A Radioanatomic analysis of the nondiskal structures of the spinal column and perispinal soft tissues / J. R. Jinkins // *Radiol. Clin. North Am.* — 2001. — Vol. 39 (1). — P. 73–99.
22. Adjacent- segment morbidity after Graft ligamentoplasty compared with posterolethal lumbar fusion / M. Kanayama, T. Hasshimoto, K. Shigenubu [et al.] // *J. Neurosurg.* — 2001. — Vol. 95 (1 Suppl.). — P. 5–10.
23. Non-fusion surgery for degenerative spondylolisthesis using artificial ligament stabilization: Surgical indication and clinical results / M. Kanayama, T. Hasshimoto, K. Shigenubu [et al.] // *Spine.* — 2005. — Vol. 30 (5). — P. 588–592.
24. Regional variations in the compressive properties of lumbar vertebral trabeculae. Effect of disc degeneration / T. S. Keller, T. H. Hanson, A. C. Abram [et al.] // *Spine.* — 1989. — Vol. 14. — P. 1012–1019.
25. Pathology and pathogenesis of lumbar spondylosis and stenosis / W. H. Kirkaldy-Willis, J. H. Wedge, K. Yong-Hing, [et al.] // *Spine.* — 1978. — Vol. 3. — P. 319–328.
26. Kwong Y. MDCT findings in Baastrup disease : Disease or normal features of the aging spine? / Y. Kwong, N. Roan, K. Latief // *AJR Am. J. Roentgenol.* — 2011. — Vol. 196 (5). — P. 1156–1159. — DOI: 10.2214/AJR.10.5719.
27. Lee C. K. Accelerated degeneration of the segment adjacent to a lumbar fusion / C. K. Lee // *Spine.* — 1988. — Vol. 13 (3). — P. 375–377.
28. Lindsey D. P. The effects of an interspinous implant on the kinematics of the instrumented and adjacent levels in the lumbar spine / D. P. Lindsey, K. E. Swanson, P. Fuchs [et al.] // *Spine.* — 2003. — Vol. 28 (19). — P. 2192–2197.
29. McAfee P. C. Classification of heterotopic ossification (HO) in the artificial disk replacement / P. C. McAfee, B. W. Cunningham, J. Devine [et al.] // *J. Spinal Disord. Tech.* — 2003. — Vol. 16 (94). — P. 384–389.
30. Molz F. The acute effect of L3/L4 fusion on the motion of vertebrae in a whole lumbar cadaveric spine / F. Molz, J. Partin, J. Kirkpatrick : presented at the Annual Meeting of the International Society for the Study of the Lumbar Spine. — Vancouver, BC, 2003.
31. Moore R. J. The origin and fate of herniated lumbar intervertebral disc tissue / R. J. Moore, B. Vernon-Roberts, R. D. Fraser [et al.] // *Spine.* — 1996. — Vol. 21 (18). — P. 2149–2155.
32. Mulholland R. C. Rationale, principles and experimental evaluation of the concept of soft stabilization / R. C. Mulholland, D. K. Sengupta // *Eur. Spine J.* — 2002. — Vol. 11 (Suppl. 2). — P. S198–S205.
33. Dynamic motion study of the whole lumbar spine by videofluoroscopy / A. Okawa, K. Shinomiya, H. Komori [et al.] // *Spine.* — 1998. — Vol. 23 (916). — P. 1743–1749.
34. Paaanen H. Association of incipient disc degeneration and instability in spondylolisthesis. A magnetic resonance and flexion-extension radiographic study of 20-year-old low back pain patients / H. Paaanen, M. Tertti // *Arch. Orthop. Trauma Surg.* — 1991. — Vol. 111. — P. 16–19.
35. The outcome of posterolateral fusion in highly selected patients with discogenic low back pain / L. M. Parker, S. E. Murrell, S. D. Boden [et al.] // *Spine.* — 1997. — Vol. 21 (16). — P. 1909–1916.
36. Symptomatic spinal stenosis adjacent to a previous lumbar fusion / C. Patel, E. Truumees, J. Gittlin [et al.] // *Spine J.* — 2002. — Vol. 2 (Suppl.). — P. 54S–55S.
37. Percy M. D. Lumbar intervertebral disc and ligament deformations measured in vivo / M. D. Percy, S. B. Tibrewal // *Clin. Orthop.* — 1984. — Vol. 191. — P. 281–286.
38. The surgical treatment of the lumbar disc prolapse nucleotomy with additional transpedicular dynamic stabilization versus nucleotomy alone / M. Putzier, S. V. Schneider, J. F. Funk [et al.] // *Spine.* — 2005. — Vol. 30 (5). — P. E109–E114.
39. Roy-Camille R. Traitement des fractures du rachis dorsolombaire par la method de Bohler / R. Roy-Camille, P. Massin // *Rev. Chir. Orthop.* — 1989. — Vol. 75 (7). — P. 479–489.
40. Schecter N. A. Painful internal disc derangements of the lumbosacral spine : Discographic diagnosis and treatment by posterior lumbar interbody fusion / N. A. Schecter, M. P. France, C. K. Lee // *Orthopaedics.* — 1991. — Vol. 14 (4). — P. 447–451.
41. Computer analysis of spinal segment motion in degenerative disc with and without axial loading / J. V. Seligman, S. D. Gertzbein, M. Tile [et al.] // *Spine.* — 1984. — Vol. 9 (6). — P. 566–573.
42. Instant centre of rotation and intradiscal pressure study to identify load-sharing property of dynamic stabilization devices in the lumbar spine without fusion — a biomechanical study in cadaver spine / D. K. Sengupta, C. K. Demetropoulos, H. N. Herkowitz [et al.] : Presented at World Spine II. — Chicago, Aug 2003.
43. Intervertebral disc disorganization is related to trabecular bone architecture in the lumbar spine / E. K. Simpson, I. H. Parkinson, B. Manthey [et al.] // *J. Bone Miner. Res.* — 2001. — Vol. 16. — P. 681–687.
44. Stoll T. M. The dynamic neutralization system for the spine : A multi-center study of a novel non-fusion system / T. M. Stoll, G. Dubois, O. Schwarzenbach // *Eur Spine J.* — 2002. — Vol. 11 (Suppl. 2). — P. 170–178.
45. The effects of an interspinous implant on intervertebral disc

pressure / K. E. Swanson, D. P. Lindsey, K. Y. Hsu [et al.] // Spine. — 2003. — Vol. 28 (1). — P. 26–32.
46. Intradiscal pressure measurements above an instrumented

fusion. A cadaver study / S. L. Weinhoffer, R. D. Guyer, M. Herbert [et al.] // Spine. — 1995. — Vol. 20 (5). — P. 526–531.

The article was received at editorial office 25.01.2017

НОВАЯ КЛАССИФИКАЦИЯ 3-Х КОЛОННОЙ ТЕОРИИ О ДЕГЕНЕРАТИВНЫХ ЗАБОЛЕВАНИЯХ ПОЗВОНОЧНИКА (ОБЗОР ЛИТЕРАТУРЫ)

Б. Дарвоно¹, В. А. Радченко²

¹ Медицинский факультет университета Таруманагара, Джакарта. Индонезия

² ГУ «Институт патологии позвоночника и суставов им. проф. М. И. Ситенко НАМН Украины», Харьков

✉ Bambang Darwono: bdarwono@hotmail.com

✉ Volodymyr Radchenko, MD, Prof. in Orthopaedics and Traumatology: volod56@ukr.net

ДО УВАГИ СПЕЦІАЛІСТІВ

ДУ «Інститут патології хребта та суглобів ім. проф. М. І. Ситенка НАМН України»
проводить післядипломну підготовку фахівців на курсах інформації та стажування
з актуальних питань ортопедії та травматології
(ліцензія Міністерства освіти і науки України АЕ № 285527 від 27.11.2013)

Курси для середнього медичного персоналу:

| № | Назва | Керівники |
|----|---|---|
| 1. | Функціональні та фізіотерапевтичні методи лікування хворих з ортопедо-травматологічною патологією | Проф. Маколінець В. І. К. м. н. Стауде В. А. |
| 2. | Гіпсово-ортопедична техніка та лікування хворих з ортопедо-травматологічною патологією | Д. м. н. Мателенок Є. М. Д. м. н. Мезенцев А. О. |
| 3. | Лікувальний масаж | К. м. н. Стауде В. А. |

Телефон для довідок: (057) 704-14-78